
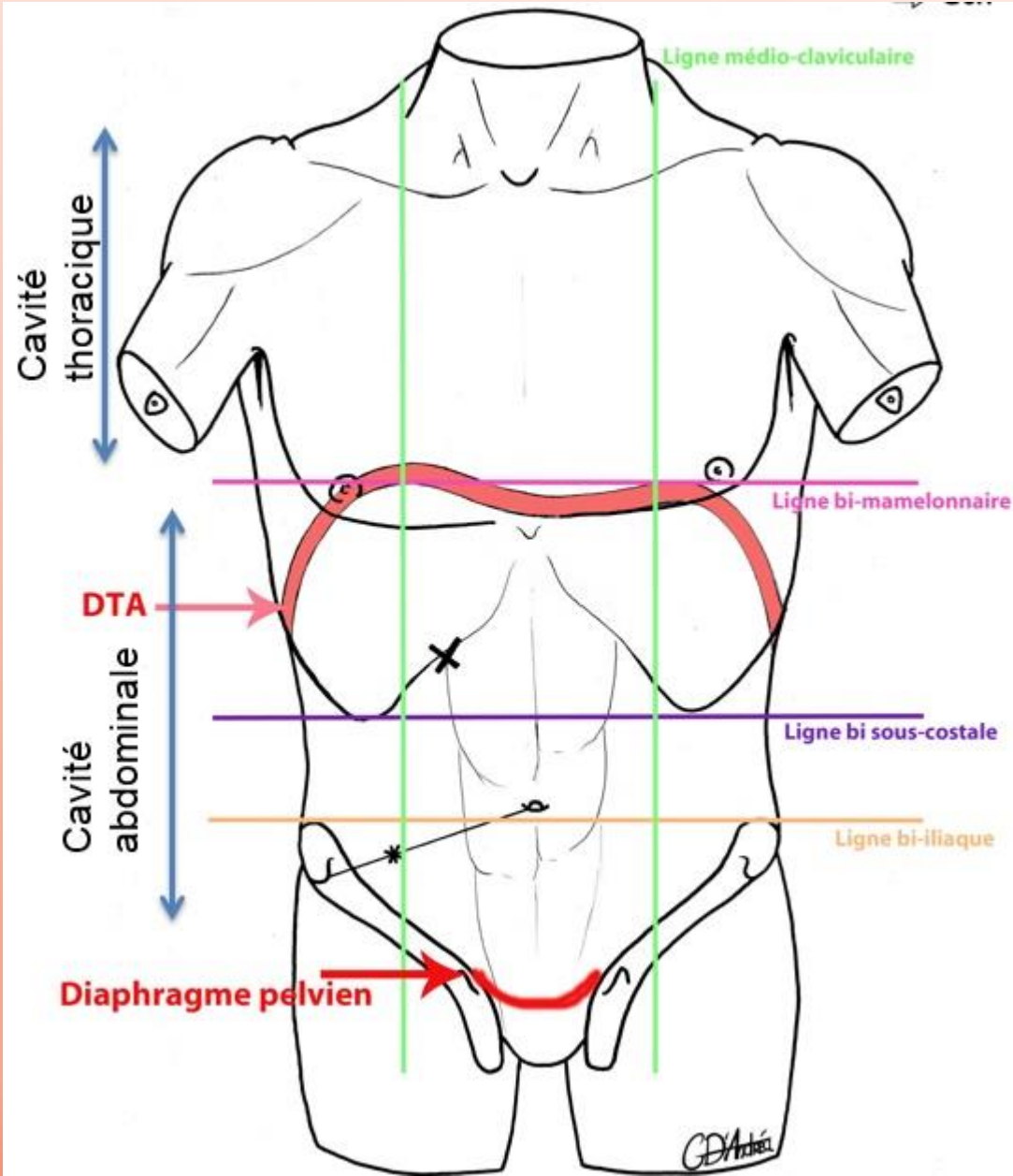


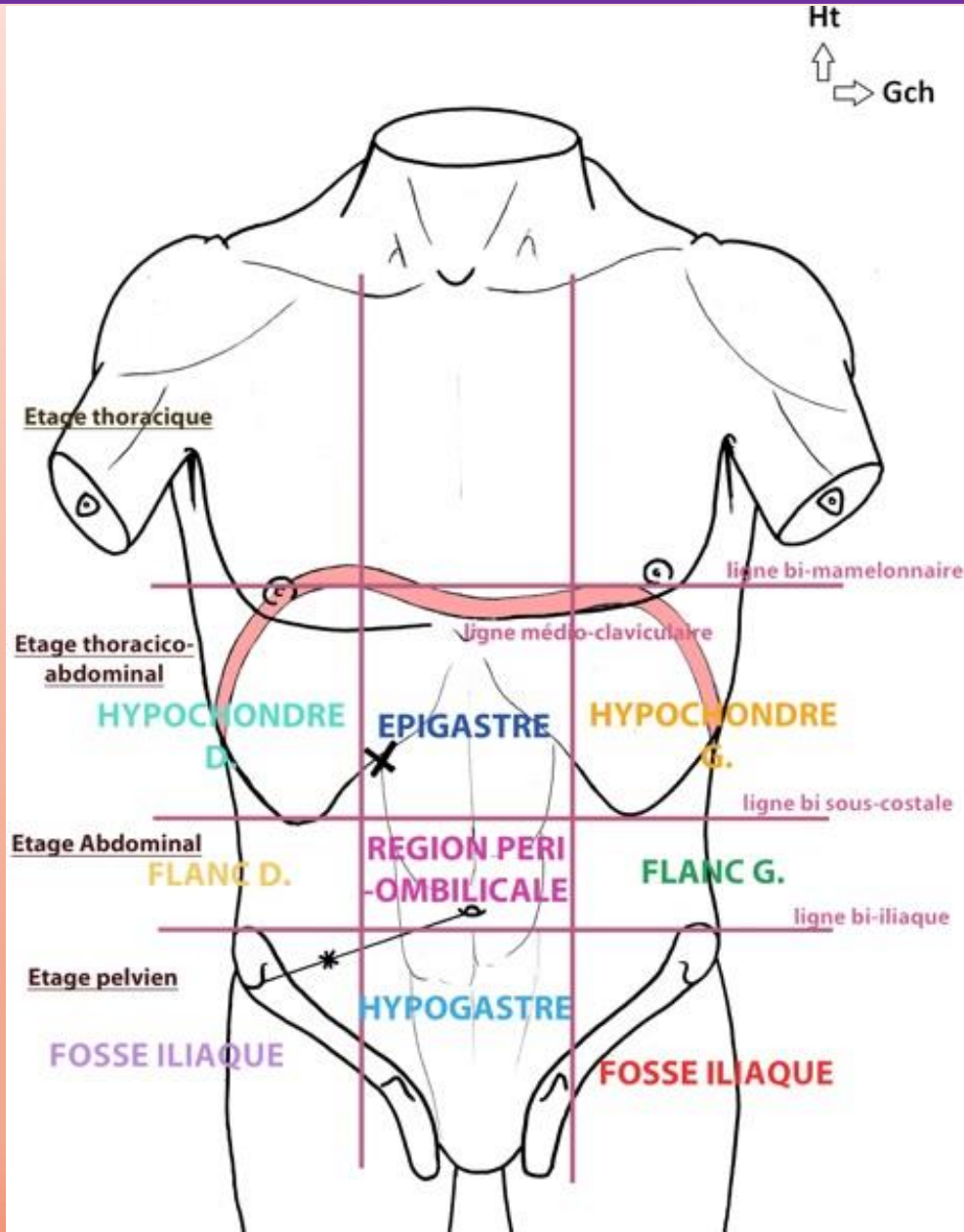
# APPAREIL DIGESTIF



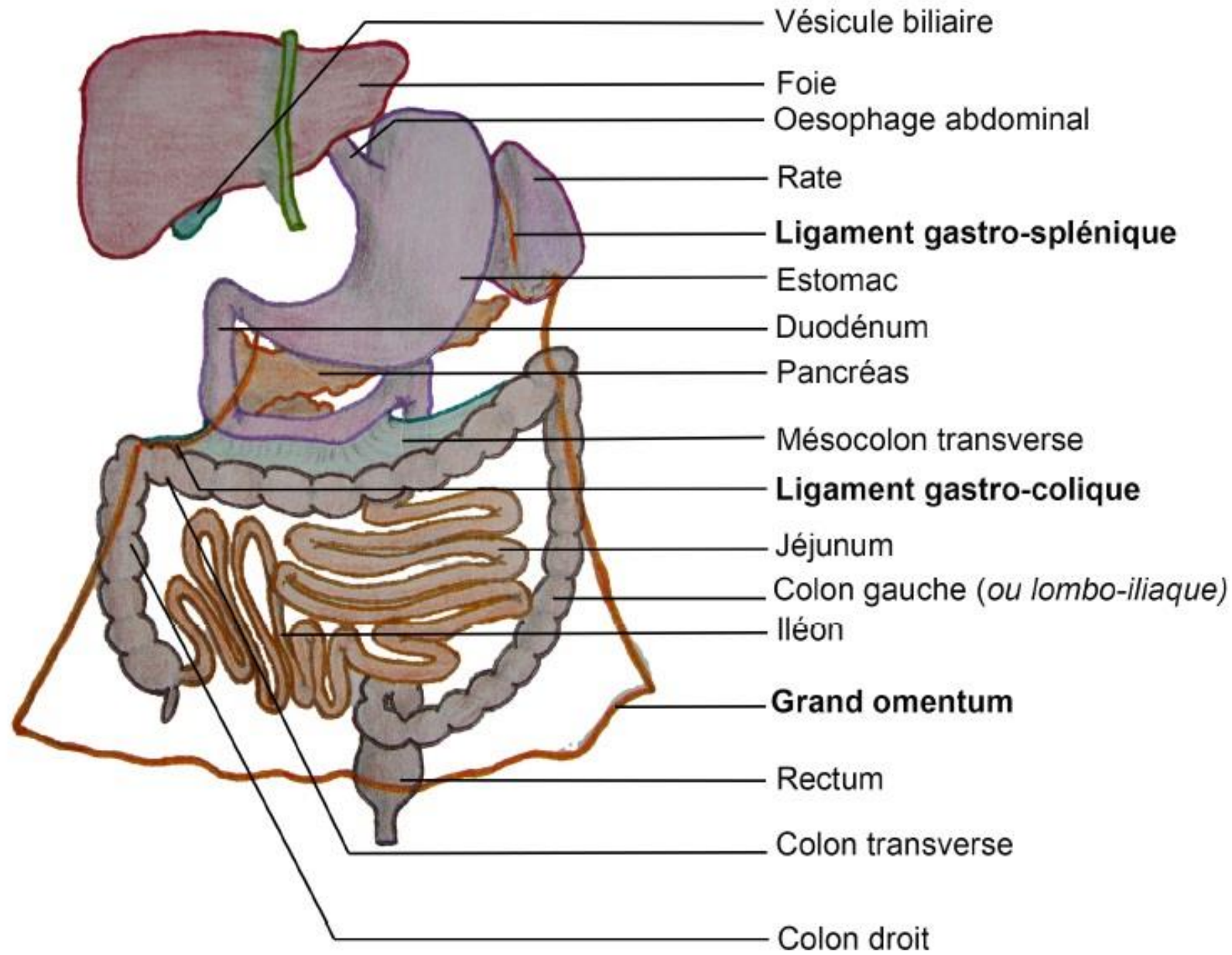
# Anatomie de surface



# Anatomie de surface

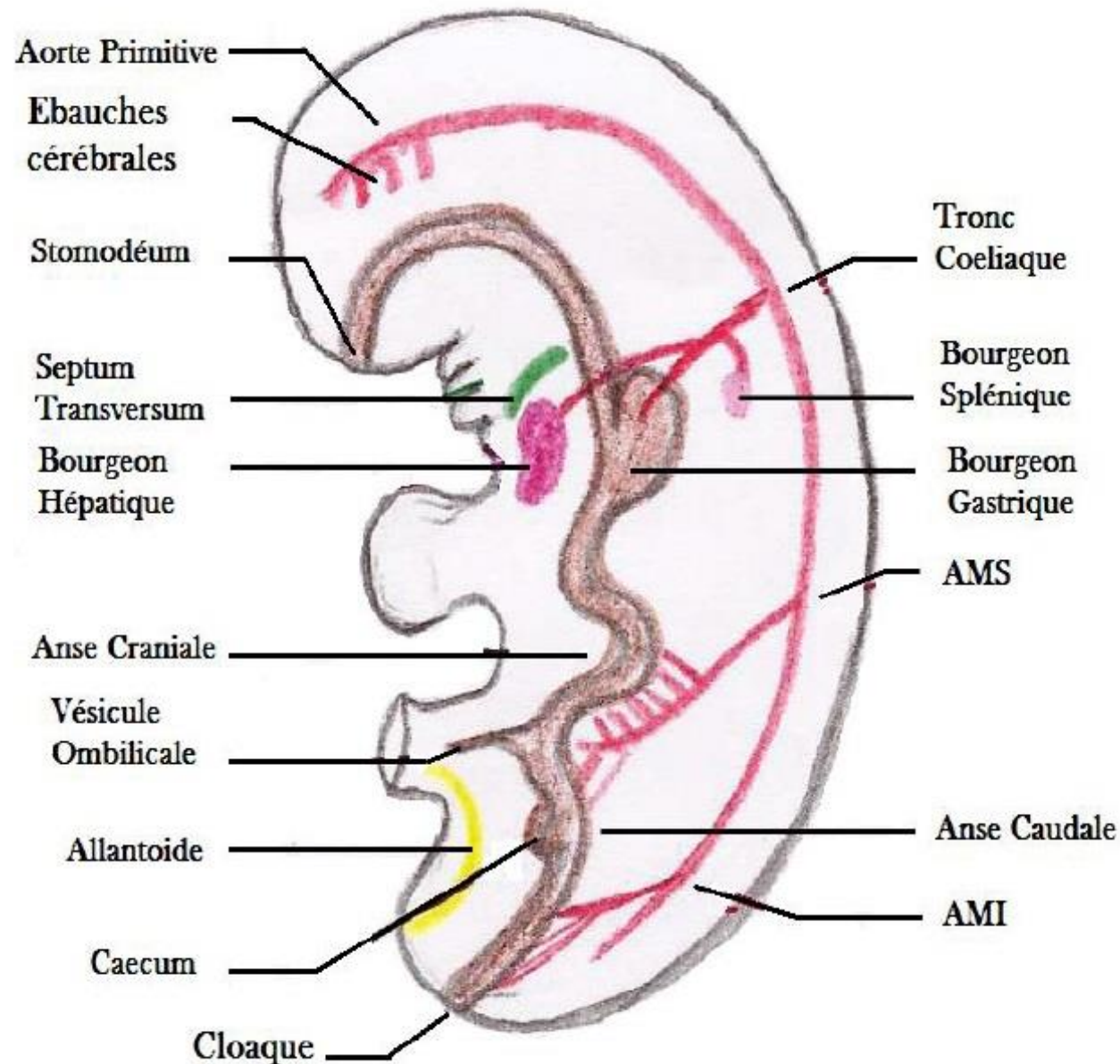


# Ouverture de la cavité abdominale

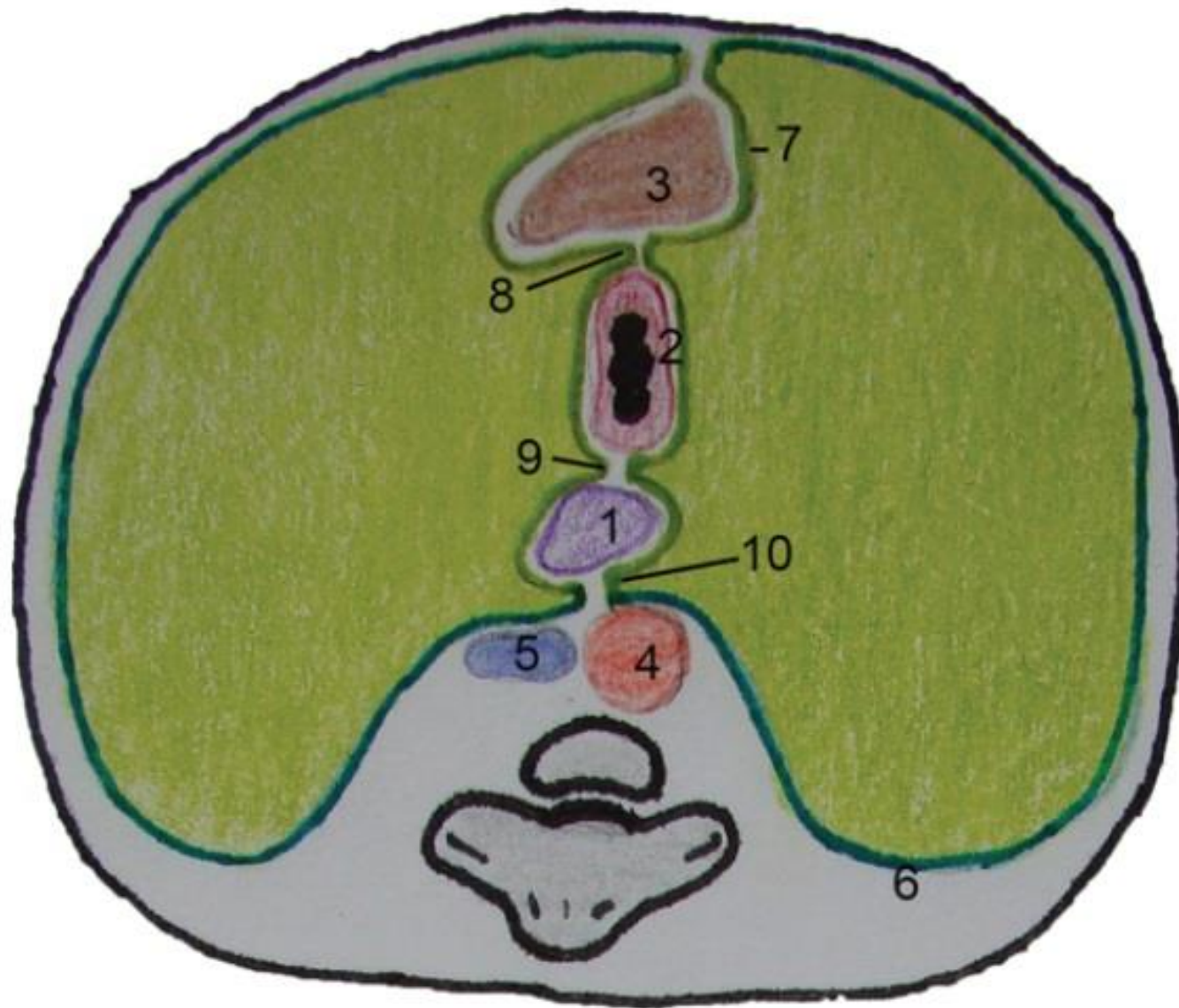




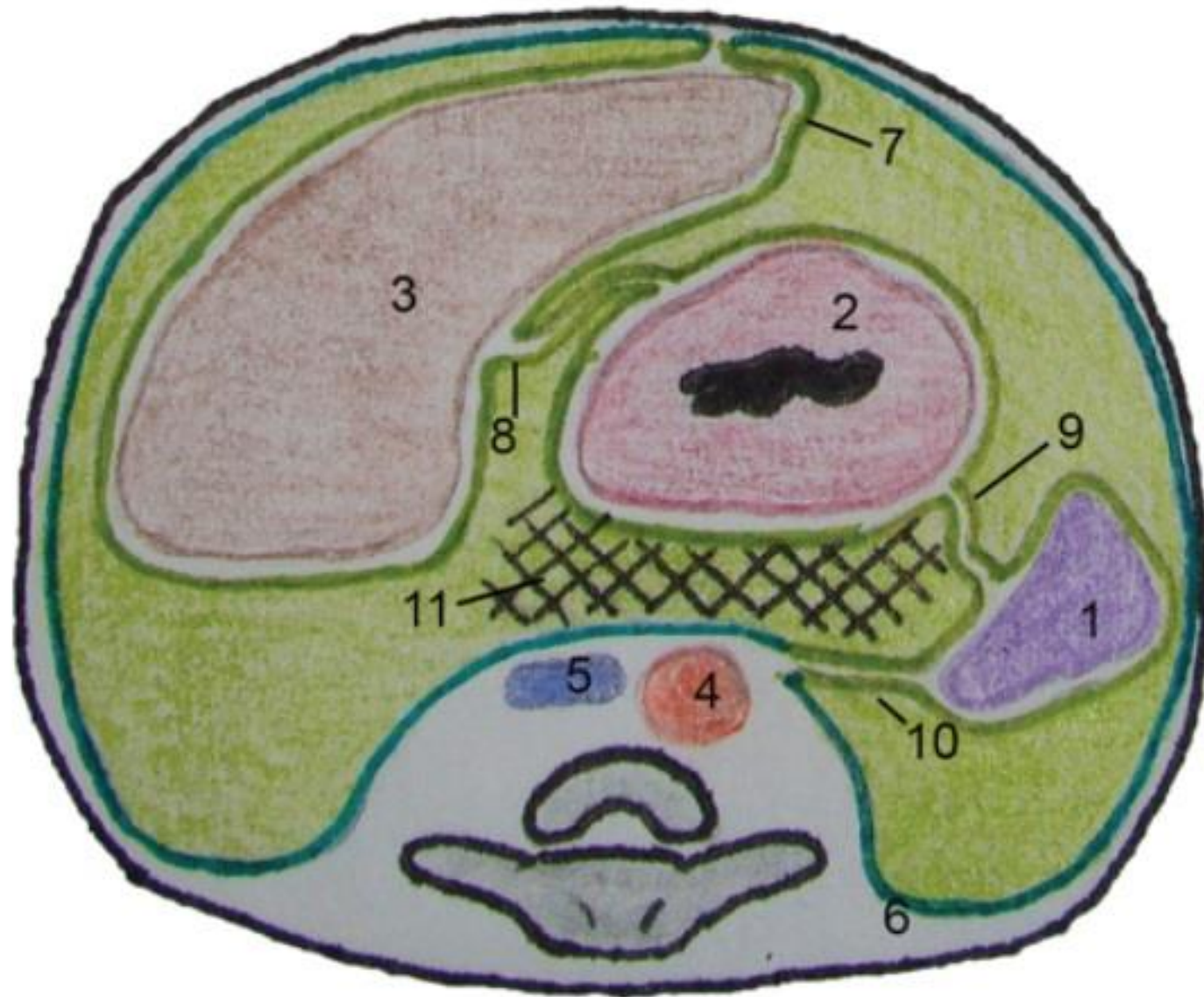
# Embryologie du tube digestif



# Etage gastrique avant rotation

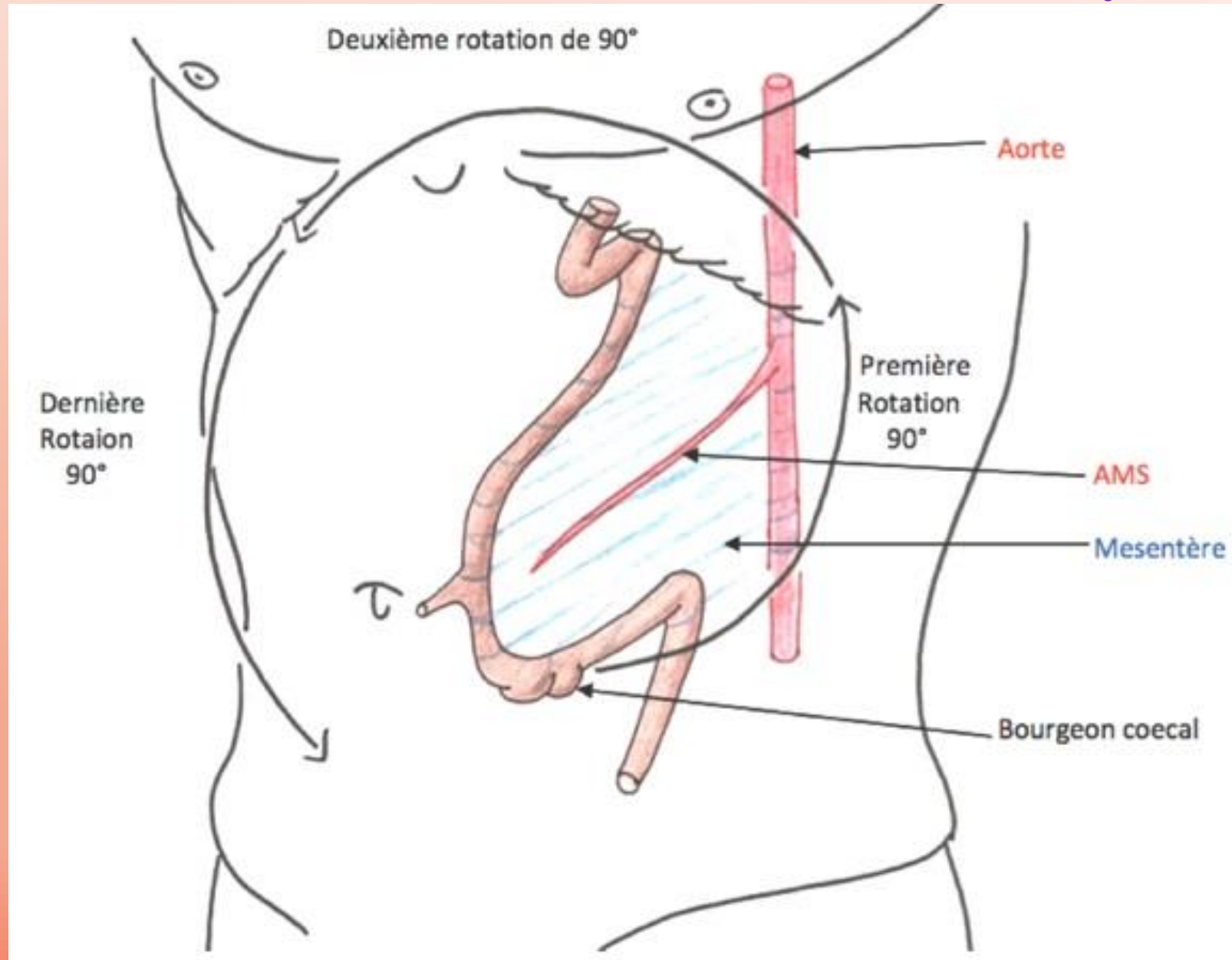


# Etage gastrique après rotation



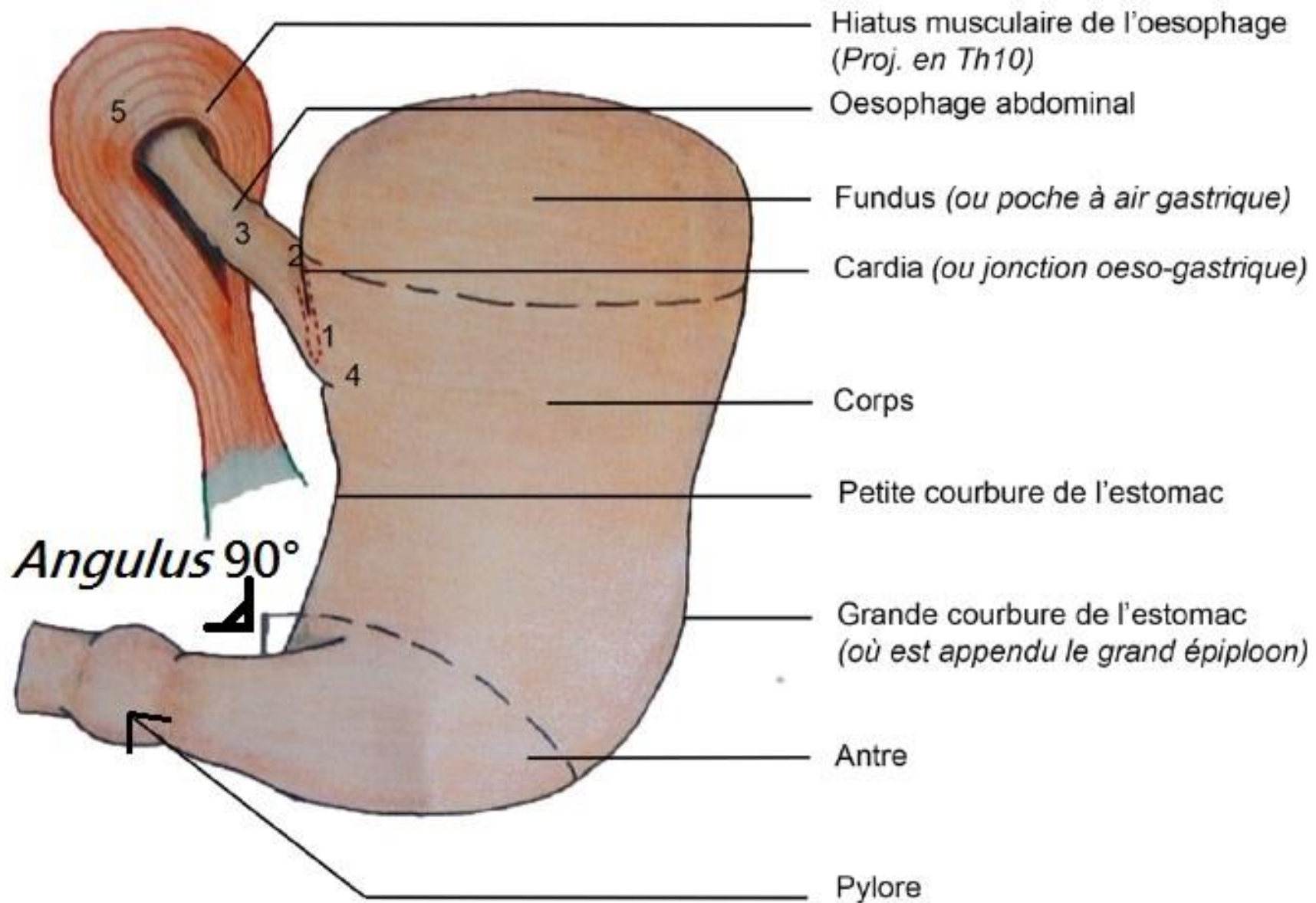


# Rotation de l'anse intestinale primitive



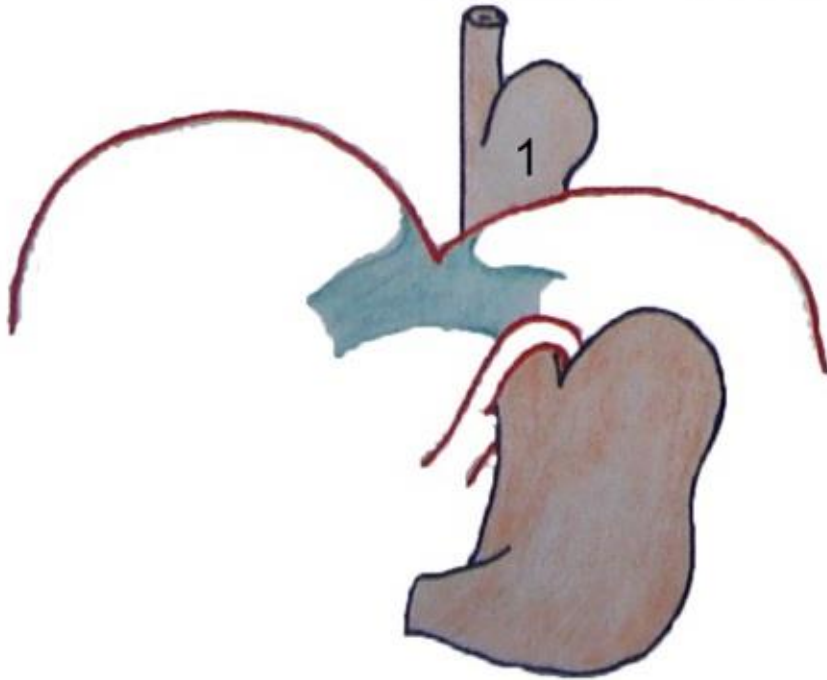


# L'estomac



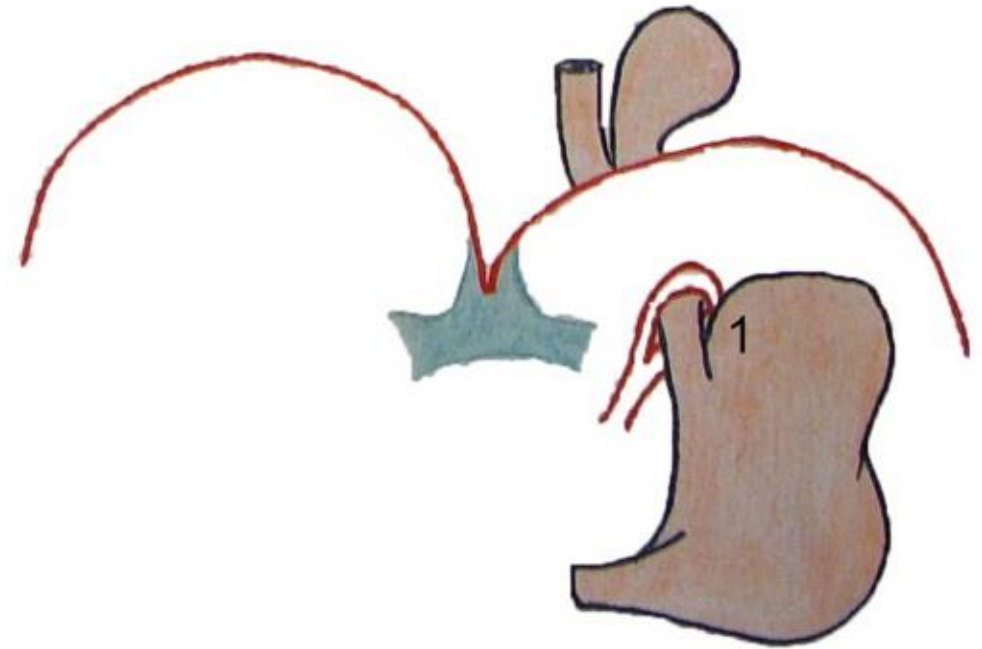
# Les hernies hiatales

Hernie par glissement

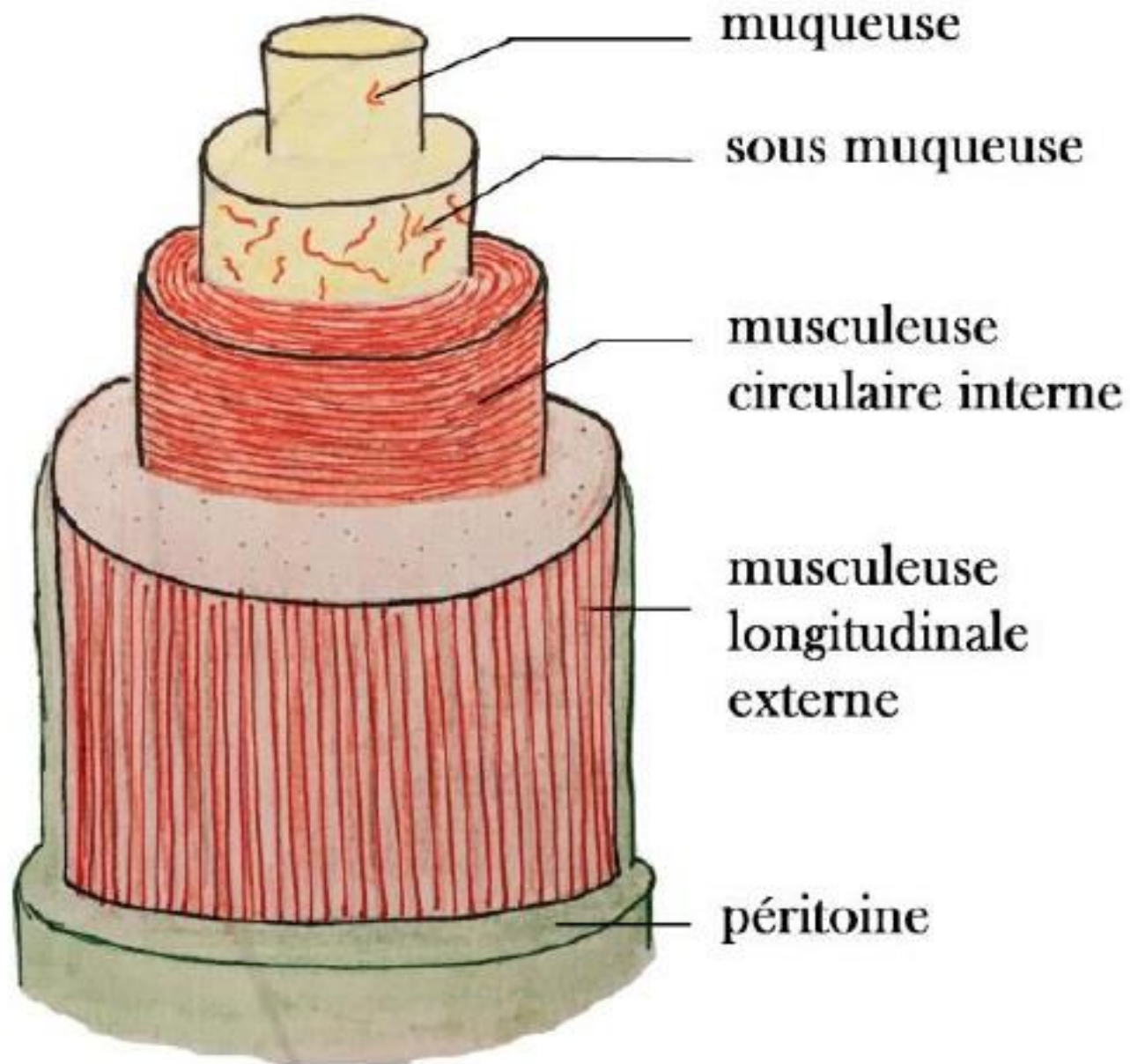


1 : Cardia

Hernie par roulement

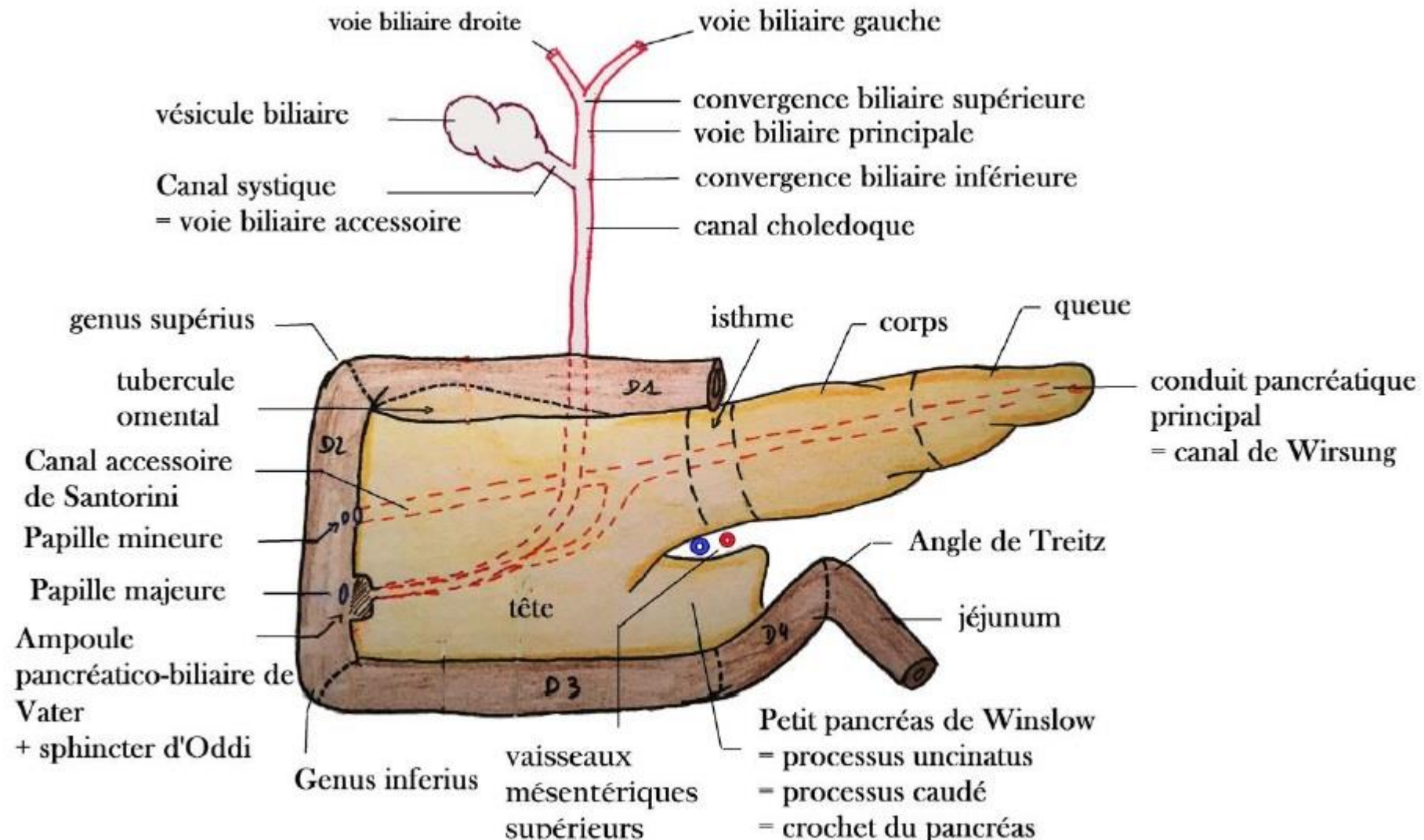


# Constitution du Tube Digestif

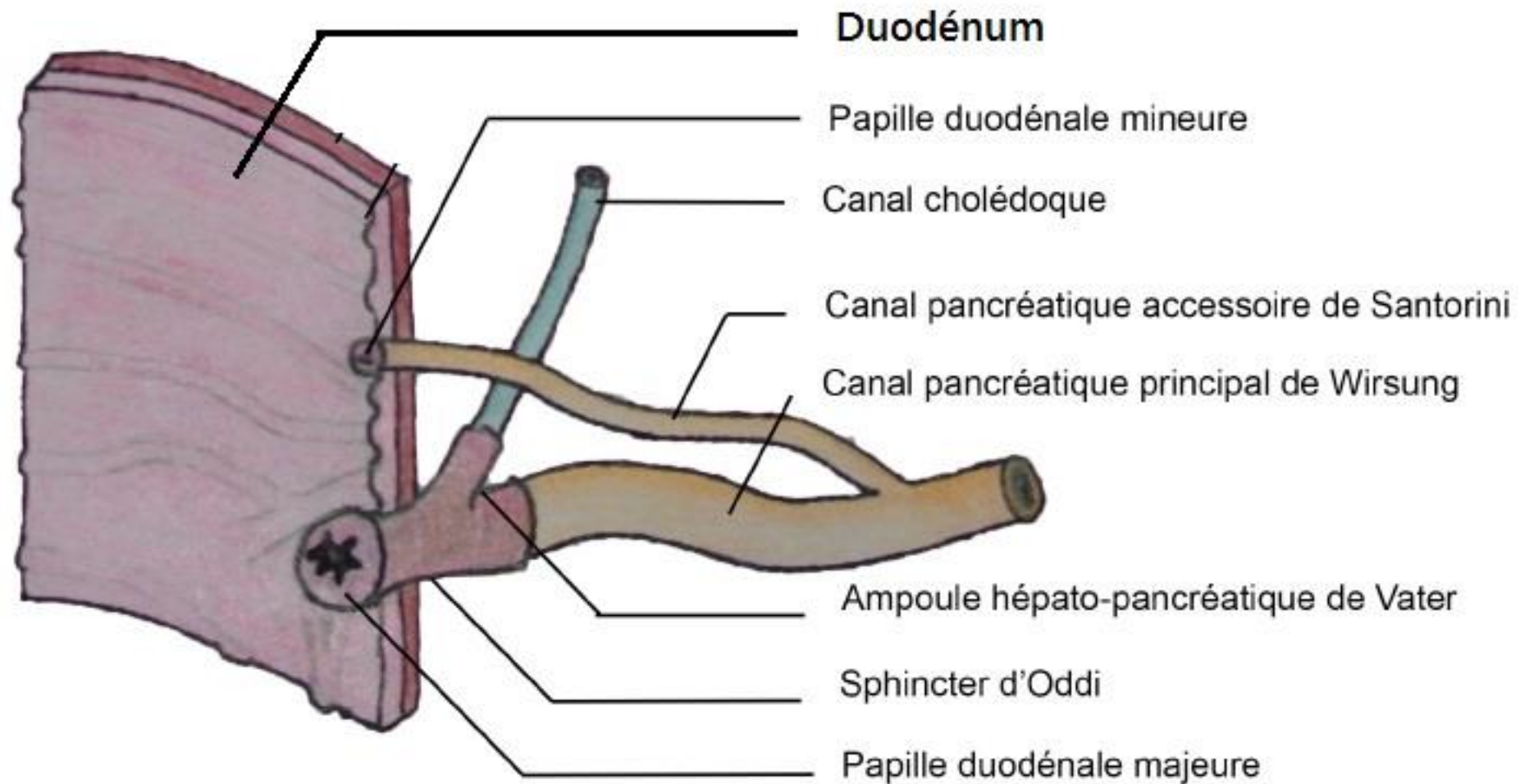




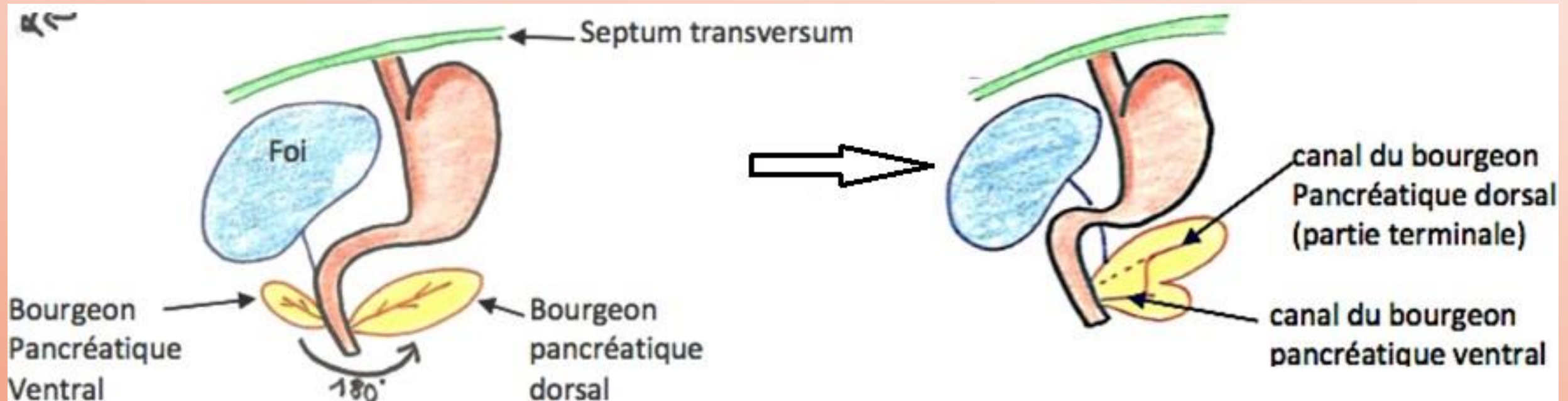
# Carrefour bilio-duodéno-pancréatique: les voies biliaires



# Carrefour bilio-duodéno-pancréatique: ZOOM

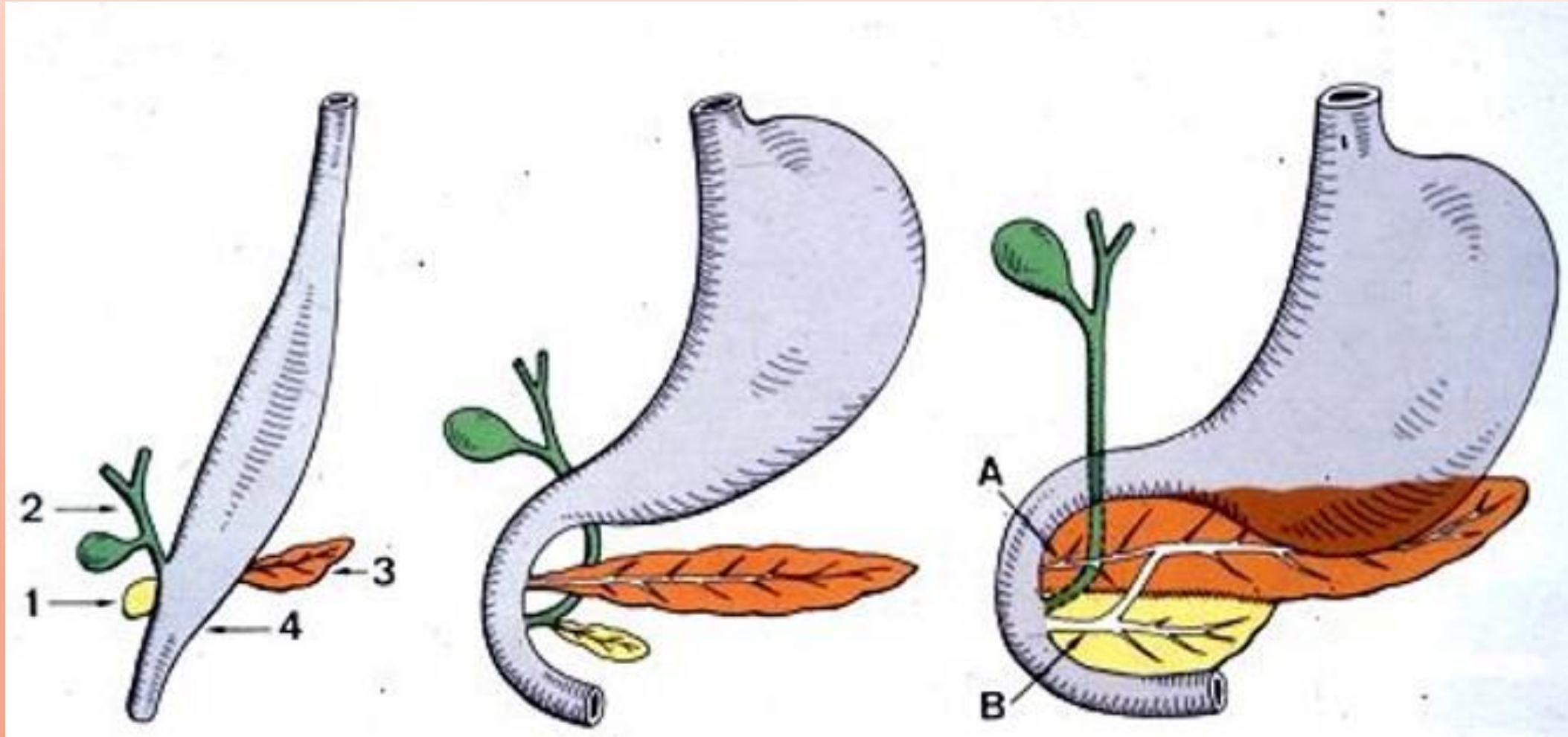


# Embryologie du pancréas

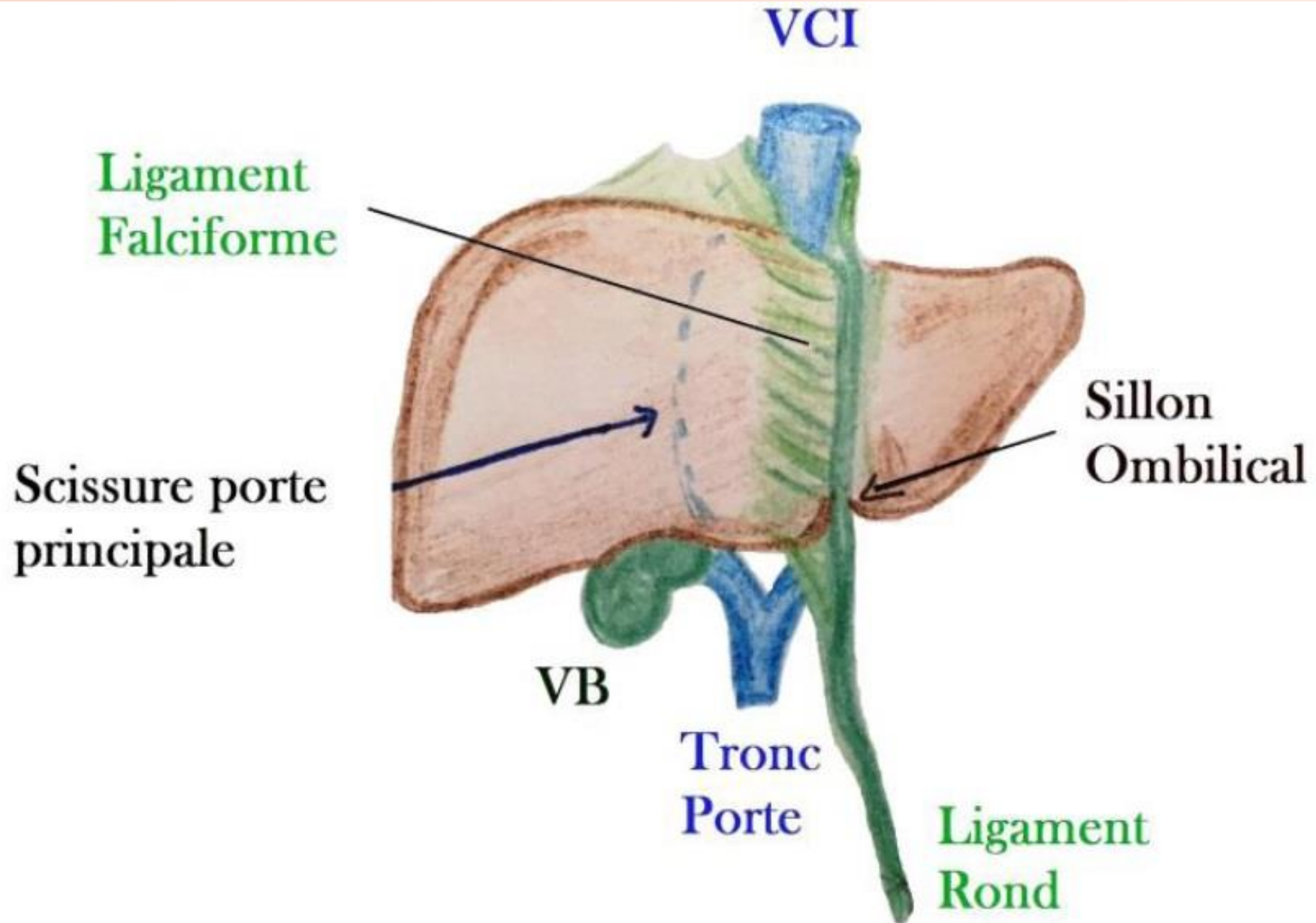




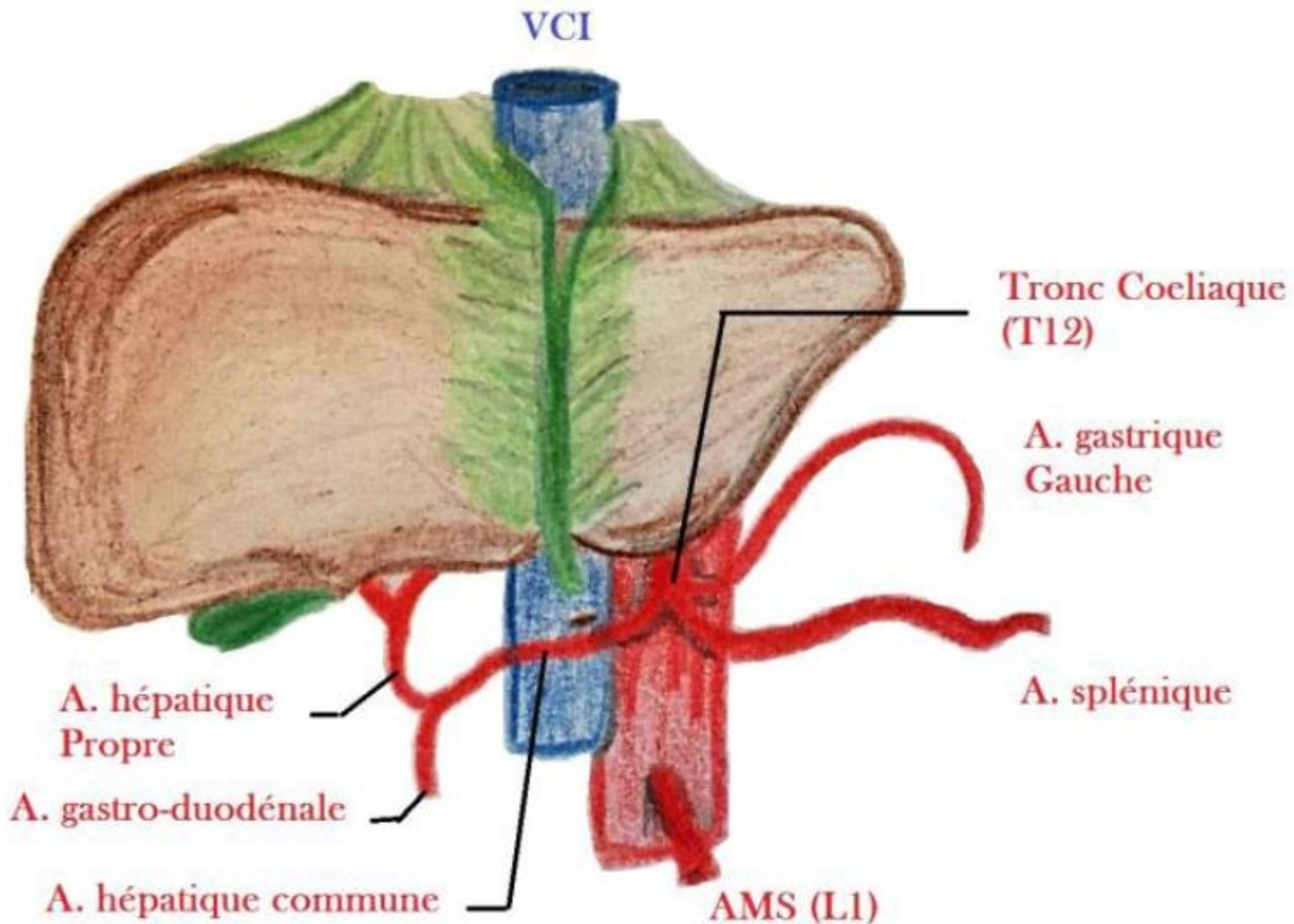
# Embryologie du pancréas



# Le foie

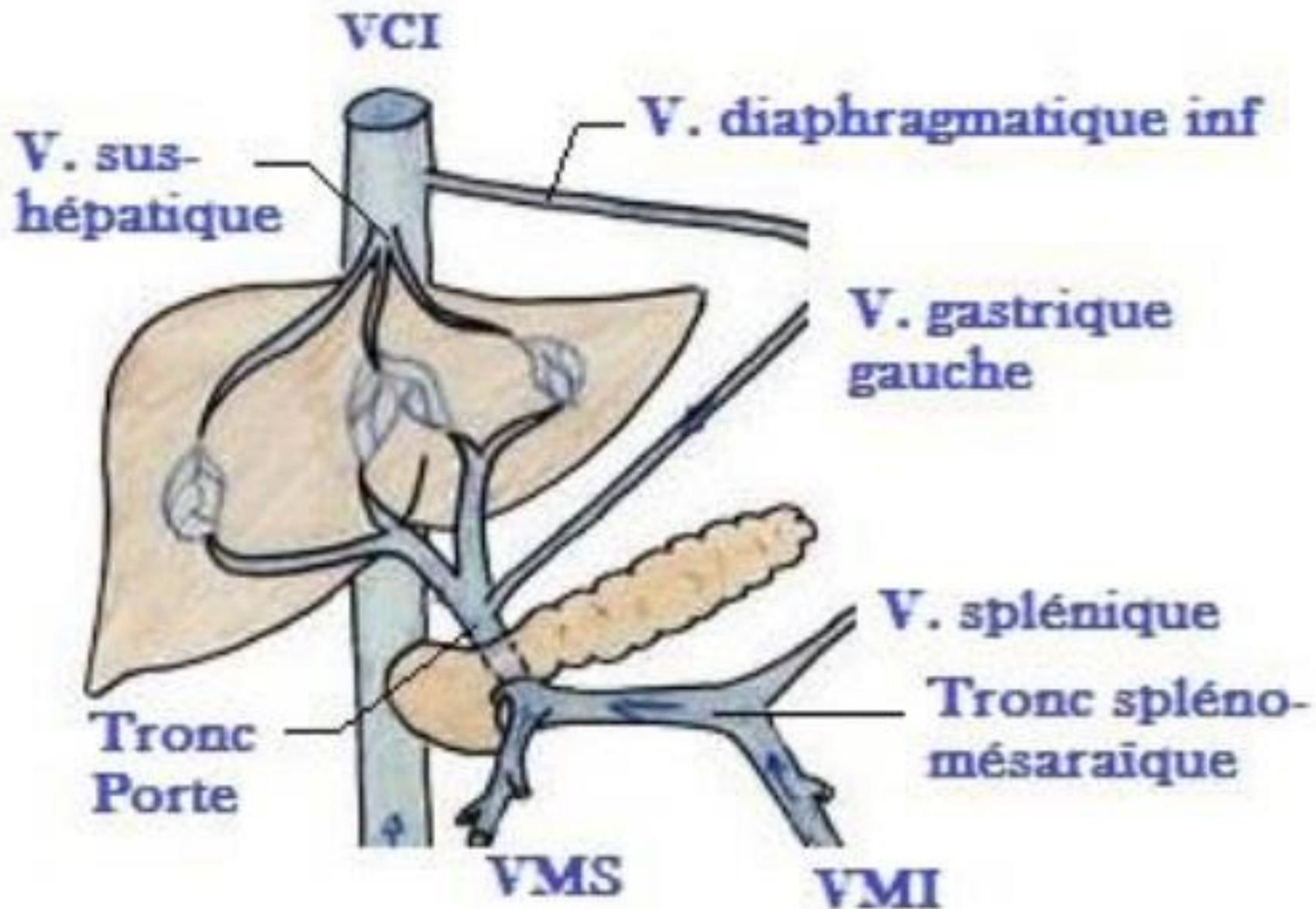


# Vascularisation artérielle du foie

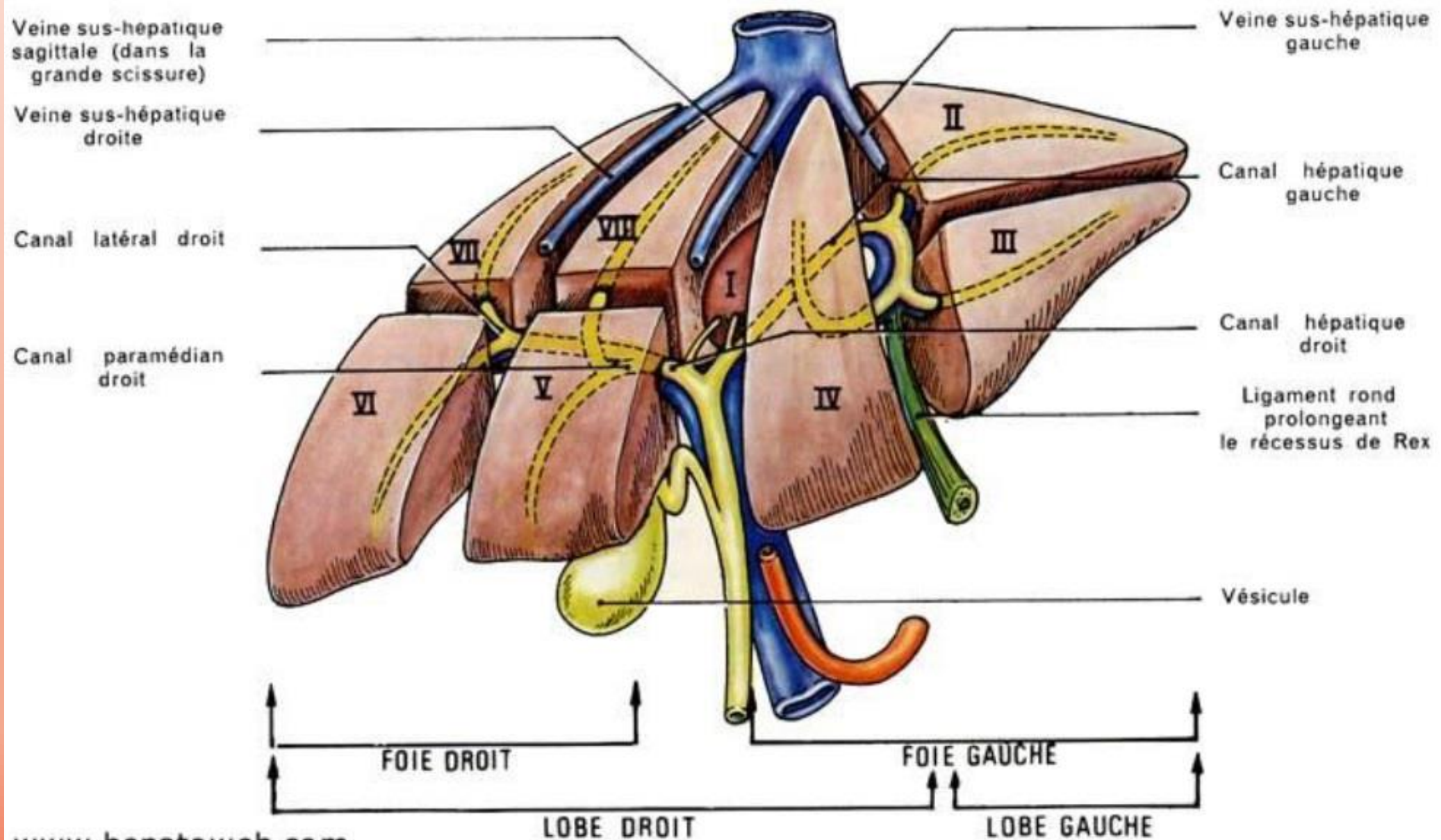




# Vascularisation veineuse du foie

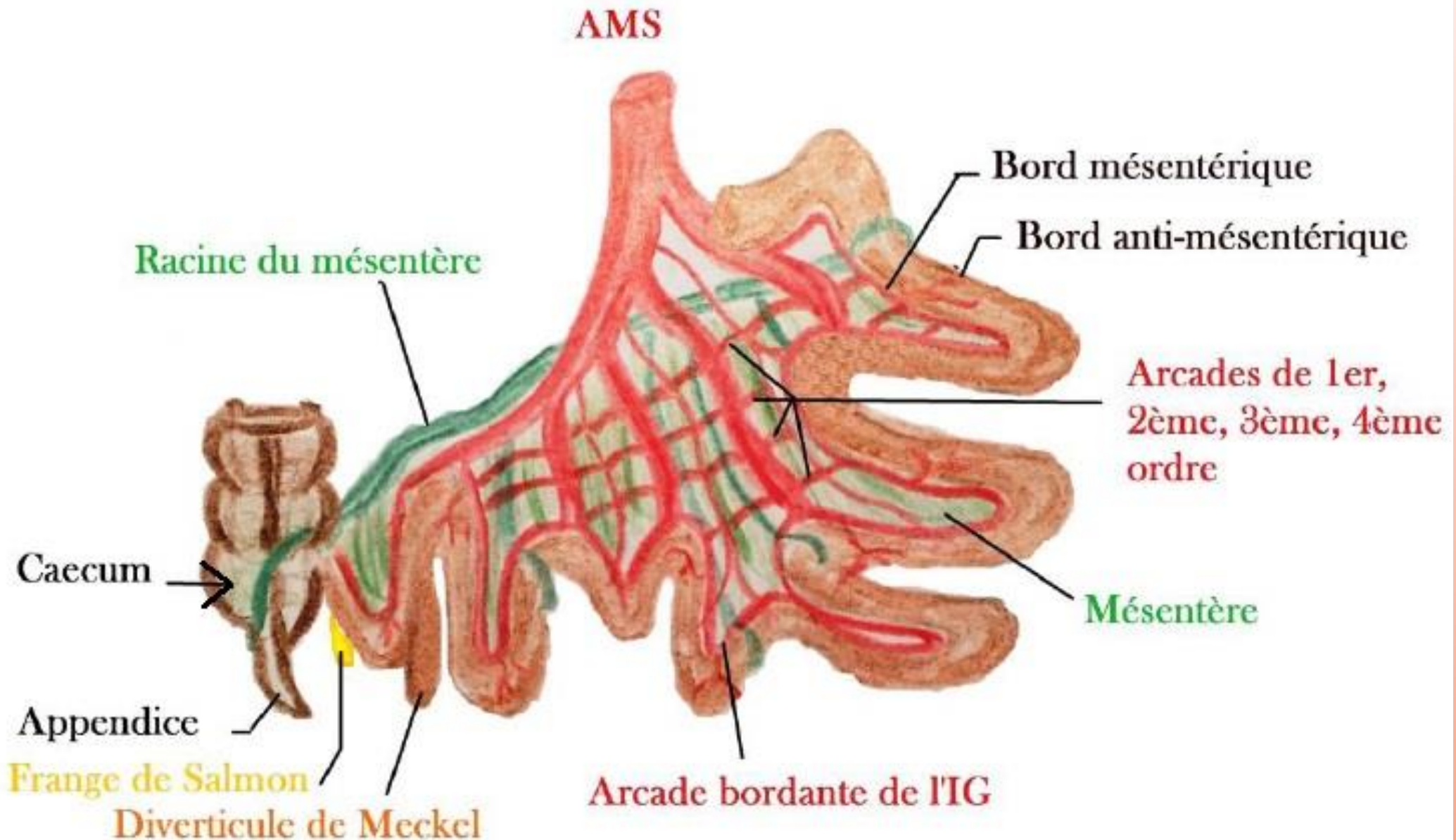


# Segmentation hépatique



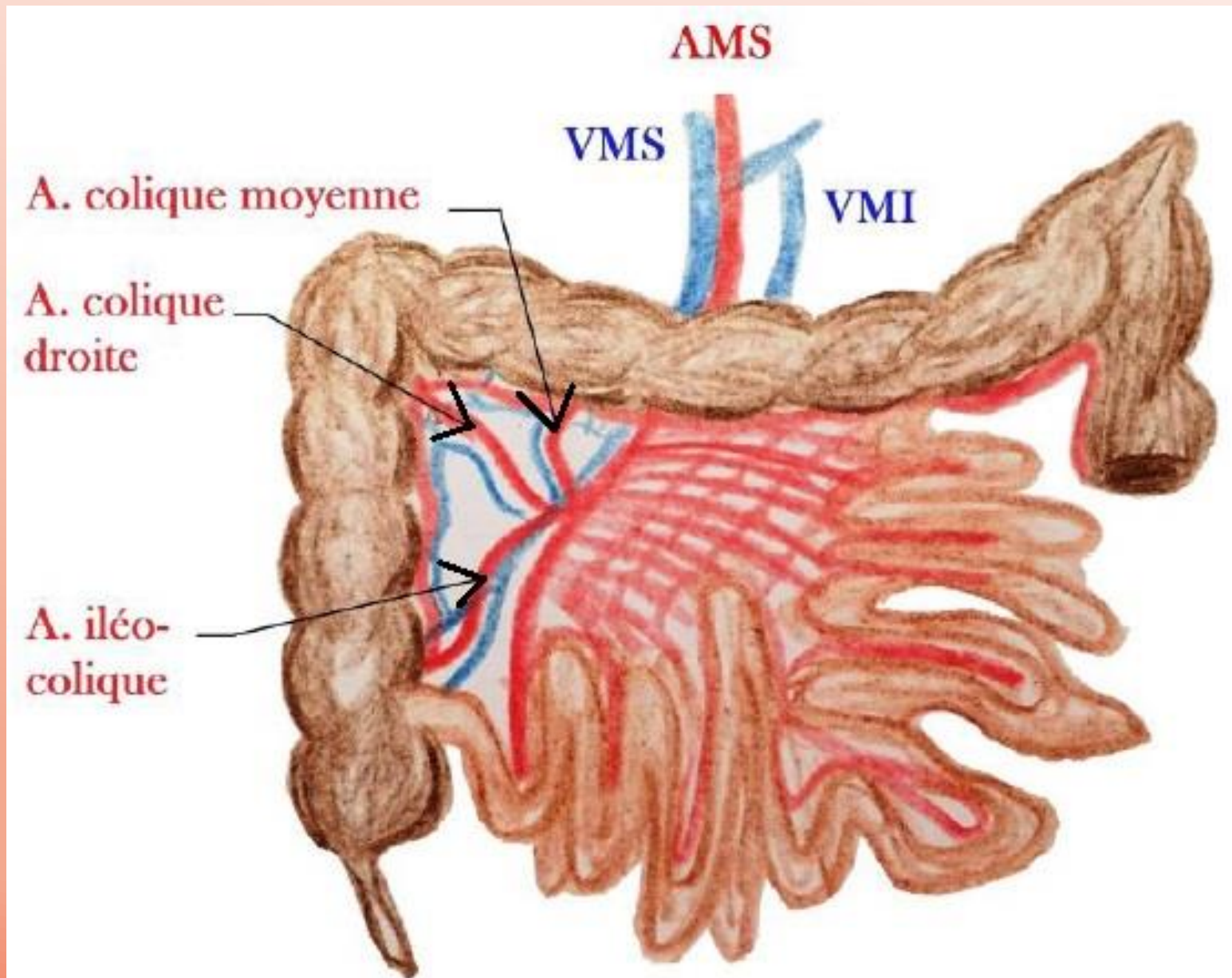


# Vue générale de l'intestin

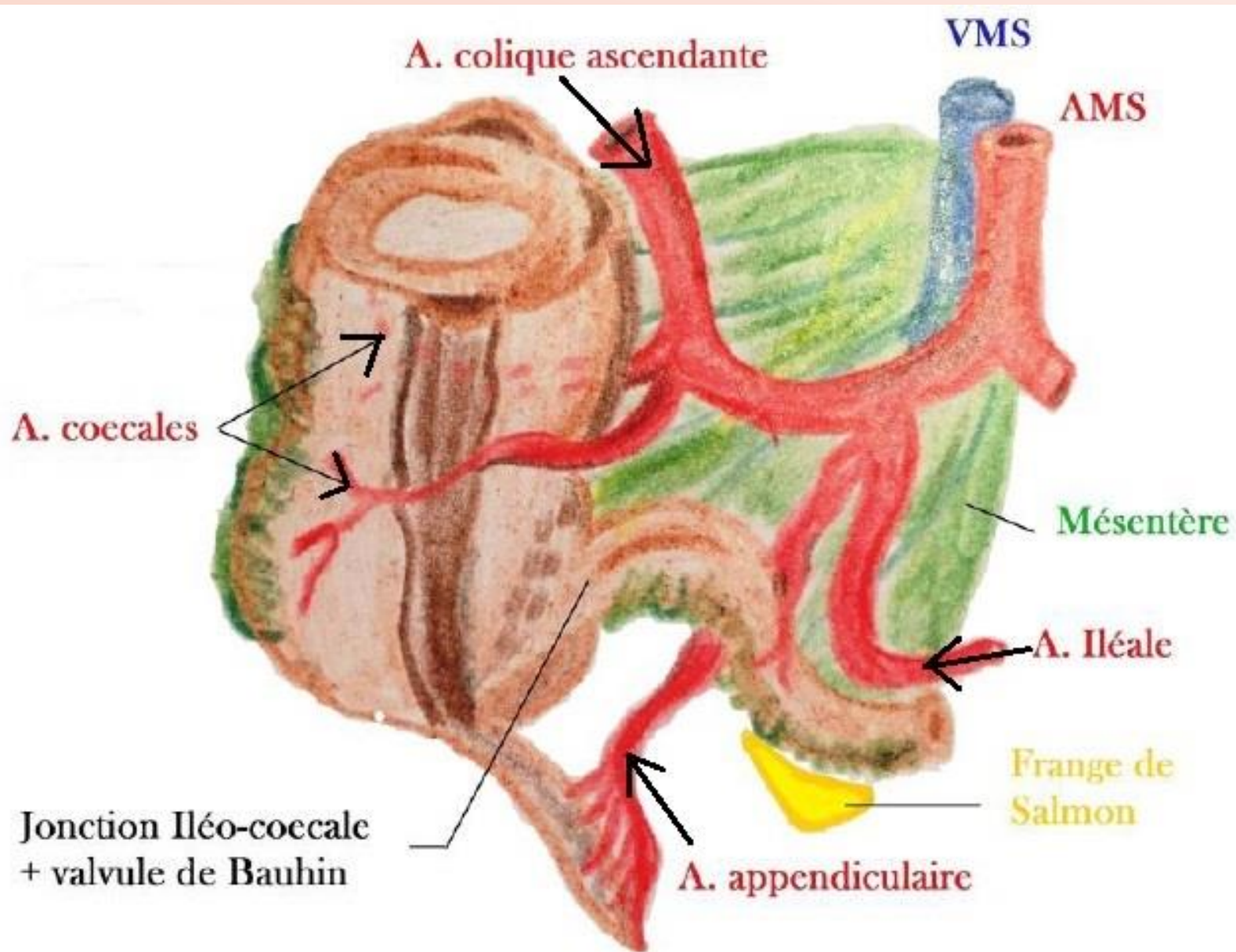




# Vascularisation de l'intestin grêle

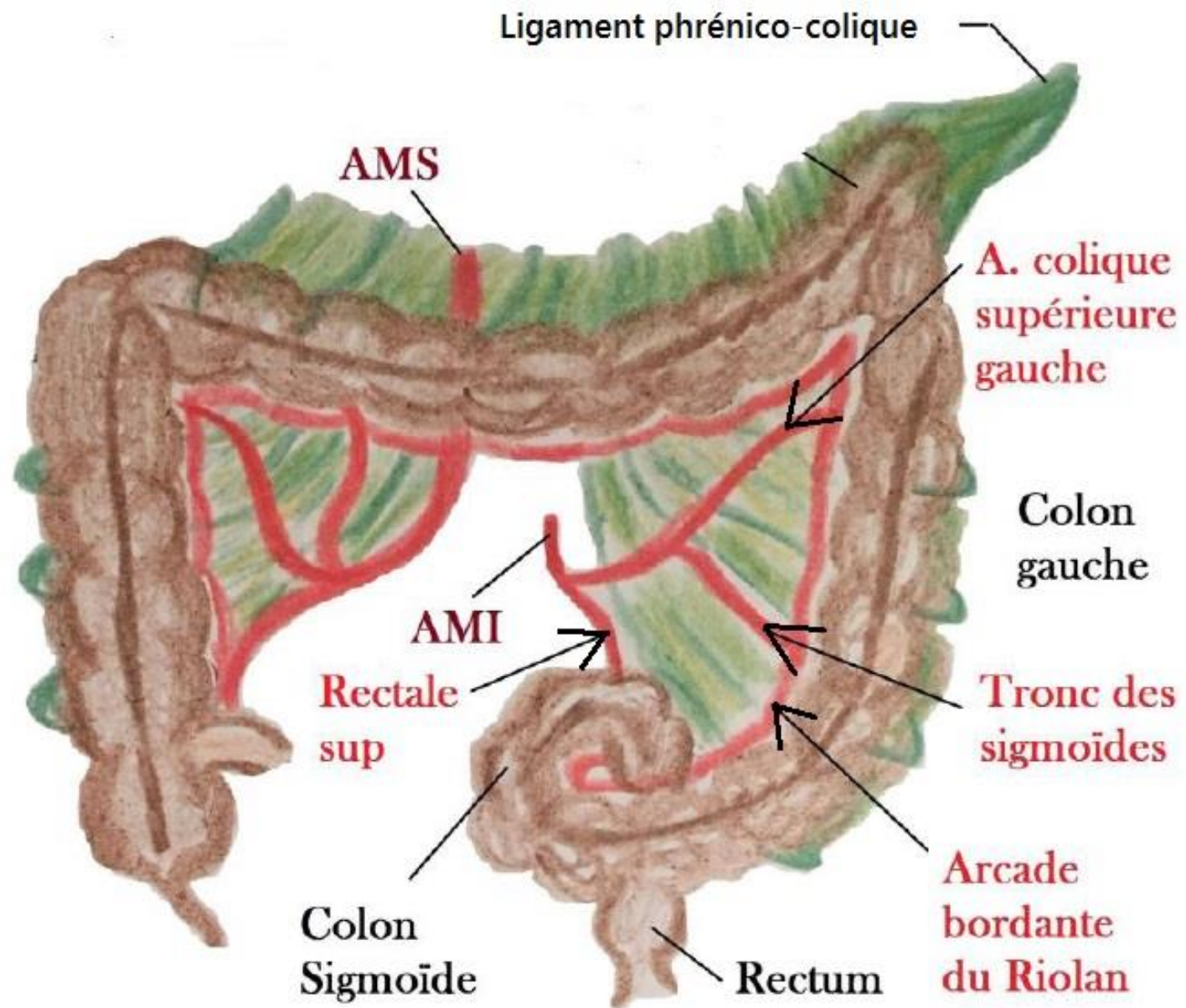


# Jonction Iléo-Caecale





# Le colon





# Anastomose porto-cave

