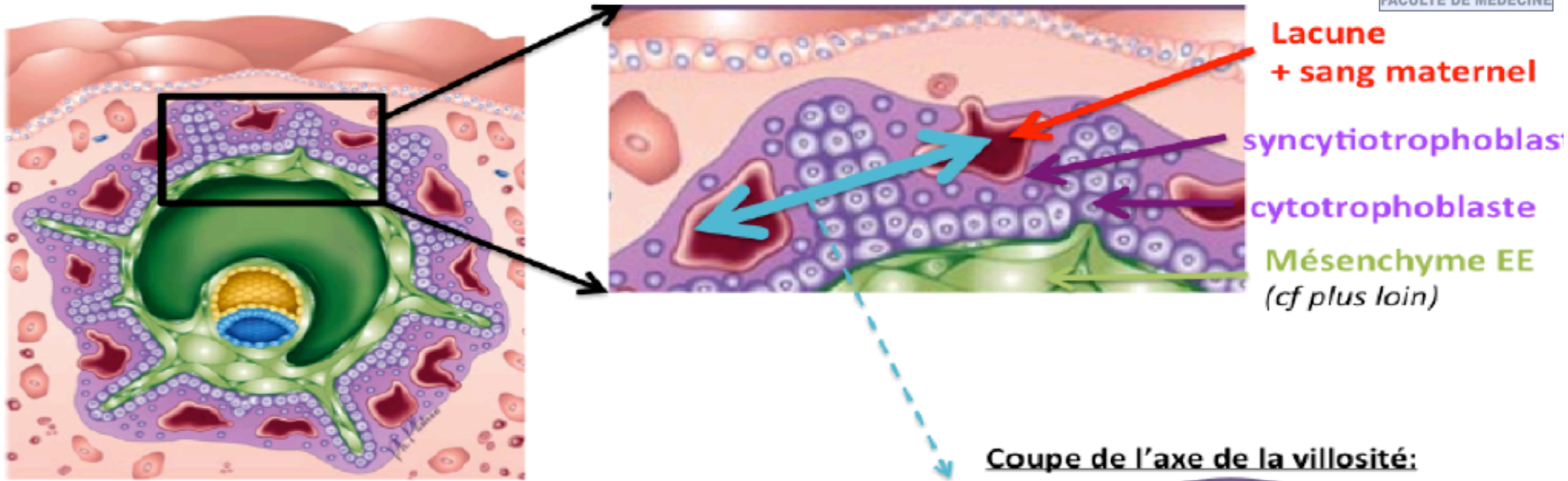
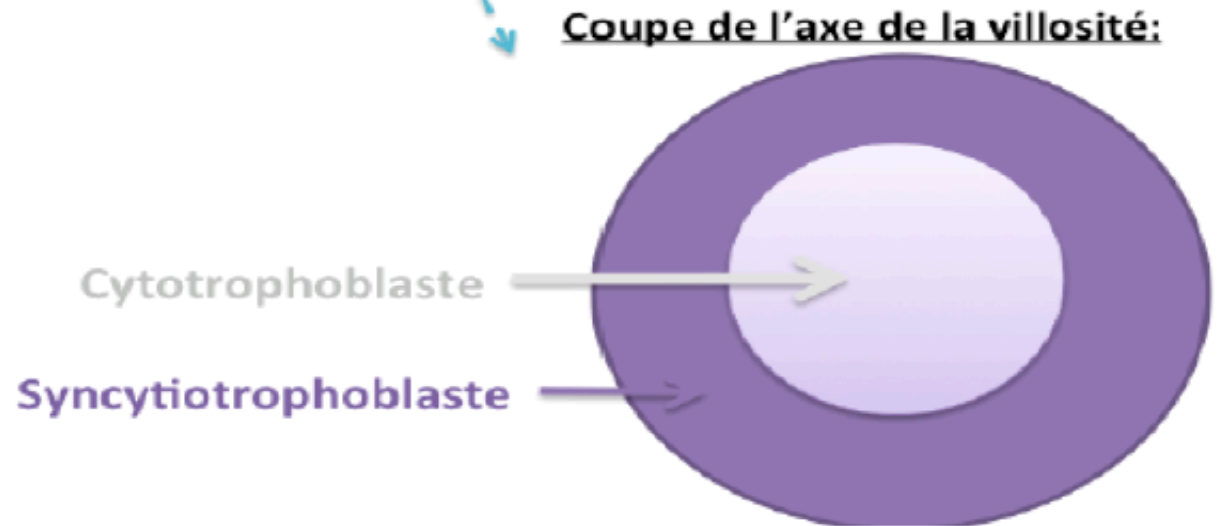

Les villosités PRIMAIRES

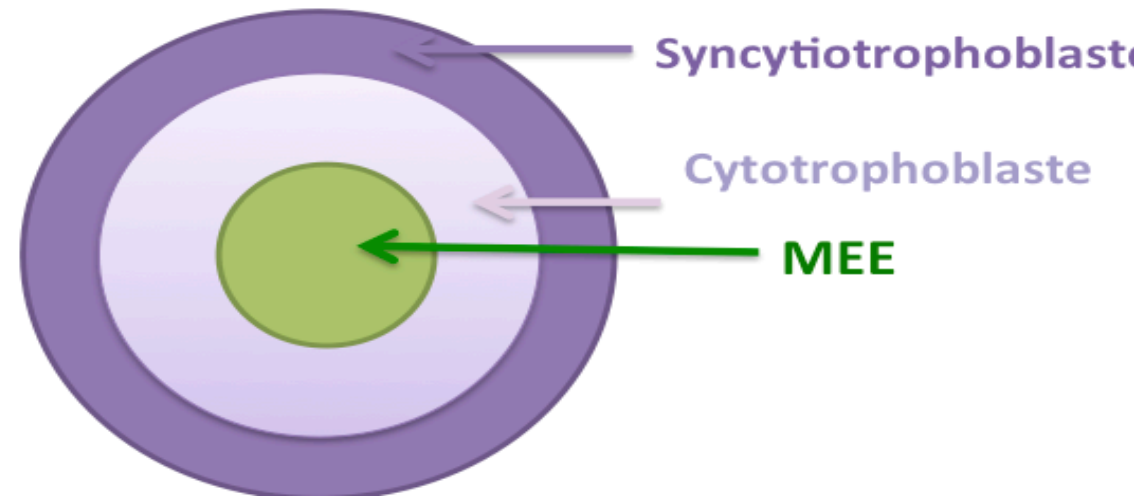
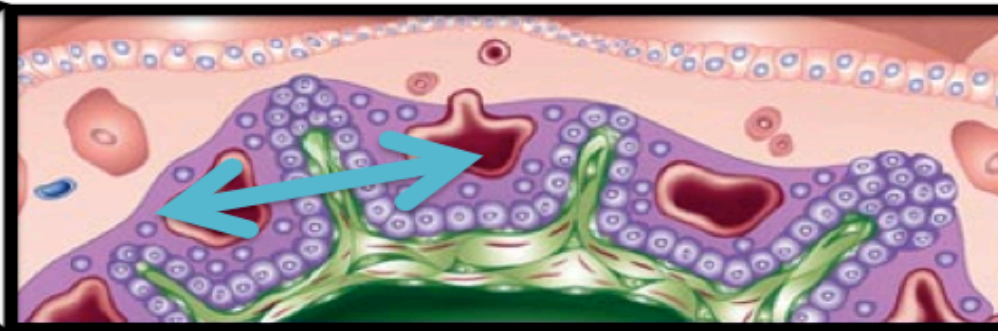
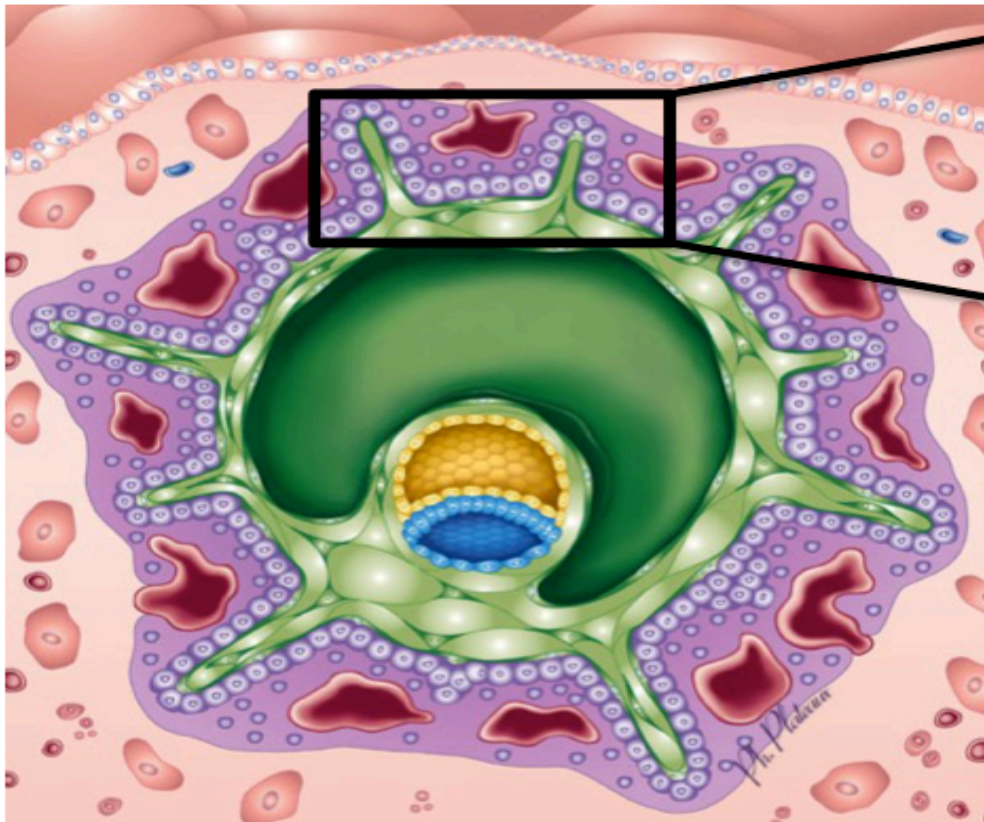


On a un **bourgeonnement syncytiotrophoblastique** avec un **axe cytotrophoblastique à l'intérieur** (version ronéo 2012-2013)

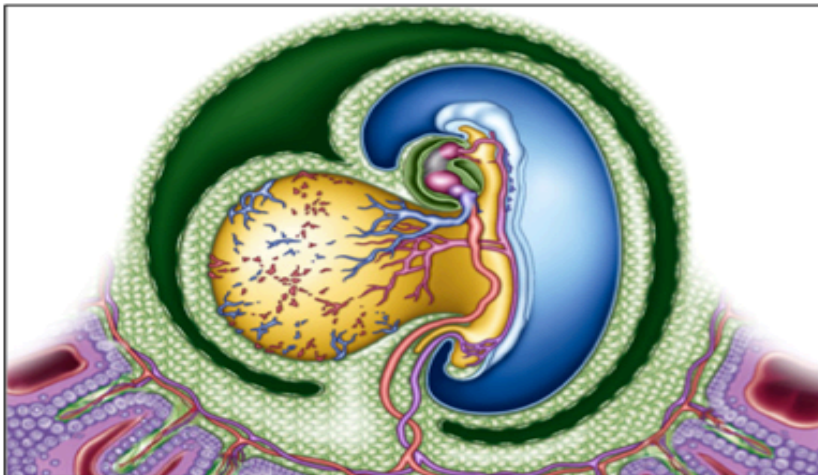
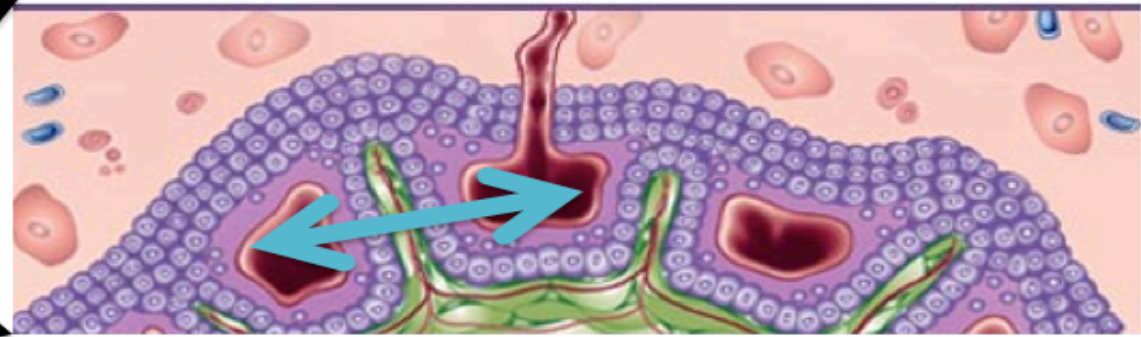
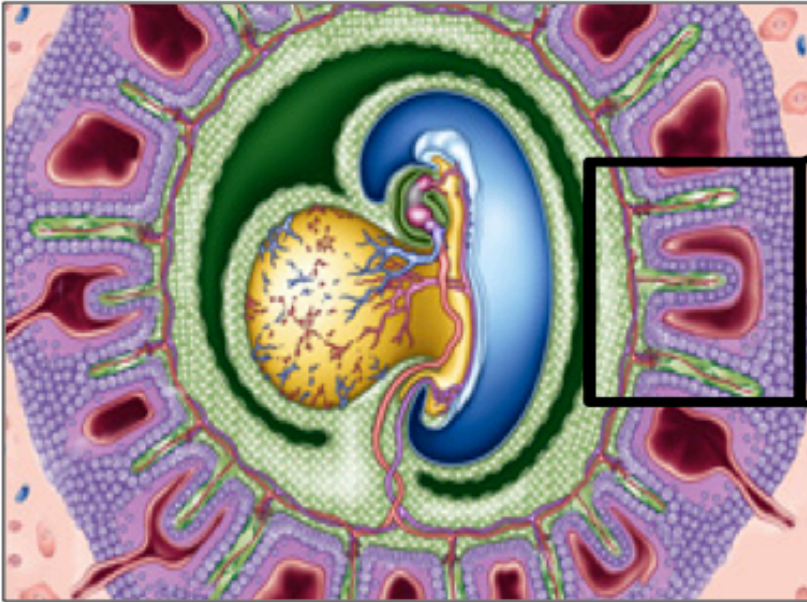




Villosités SECONDAIRES



Villosités TERTIAIRES

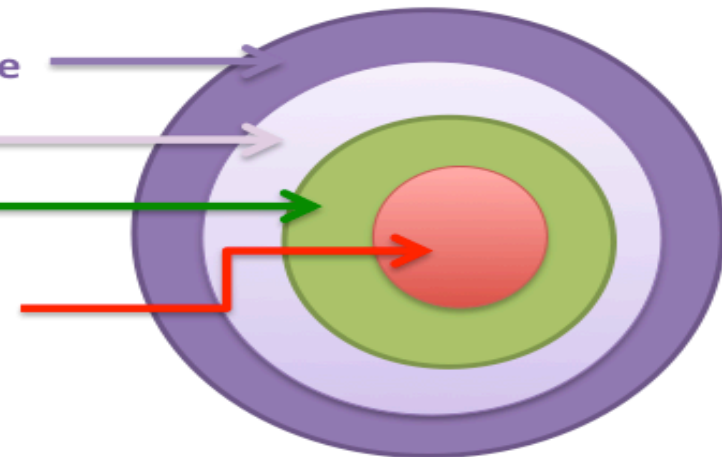


Syncytiotrophoblaste

Cytotrophoblaste

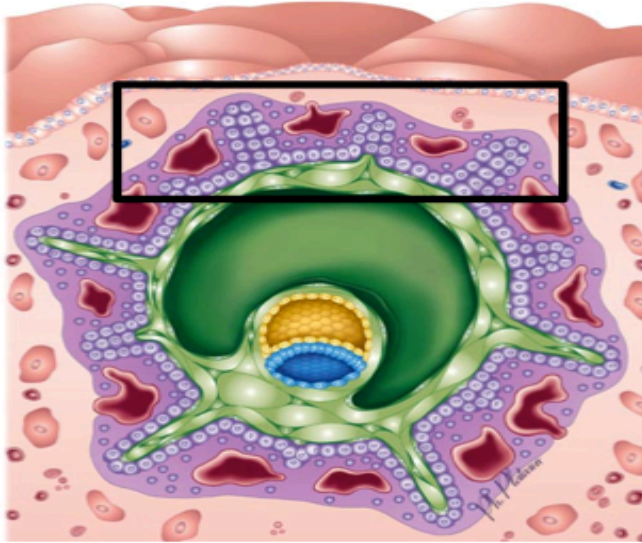
MEE

Vaisseaux sanguins
foetaux

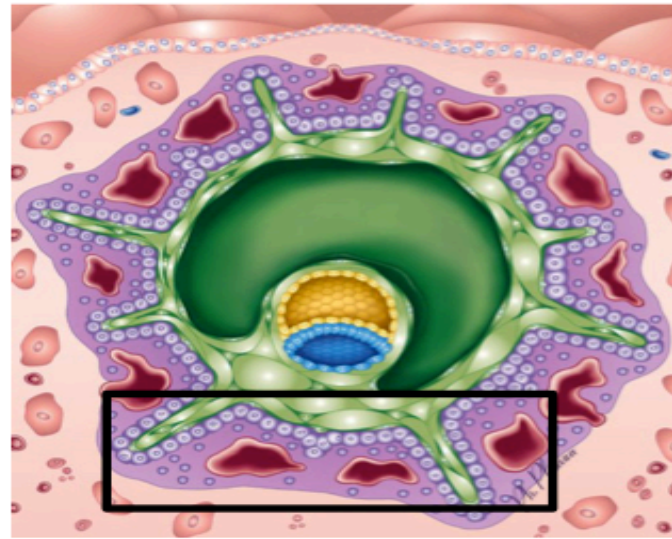


Fiche récapitulative des villosités

Villosités PRIMAIRES



Villosités SECONDAIRES



Villosités TERTIAIRES

