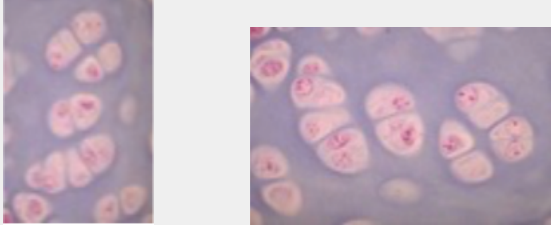
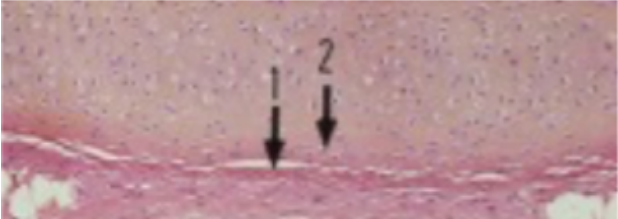

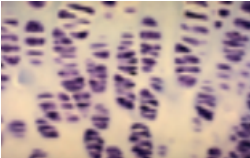
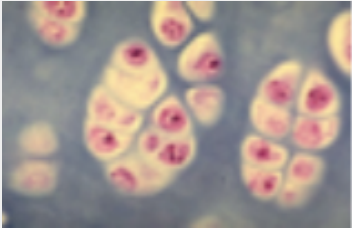
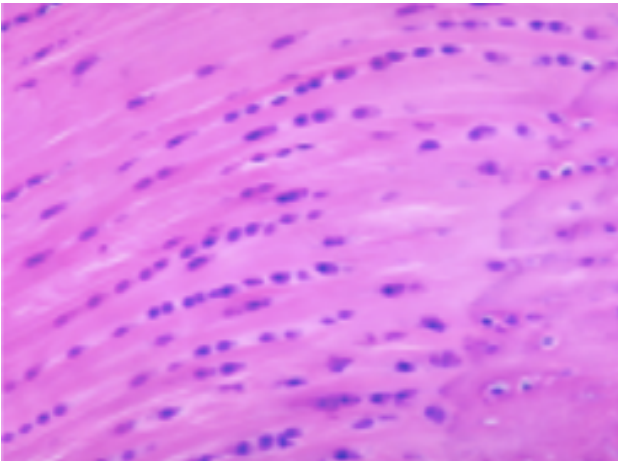
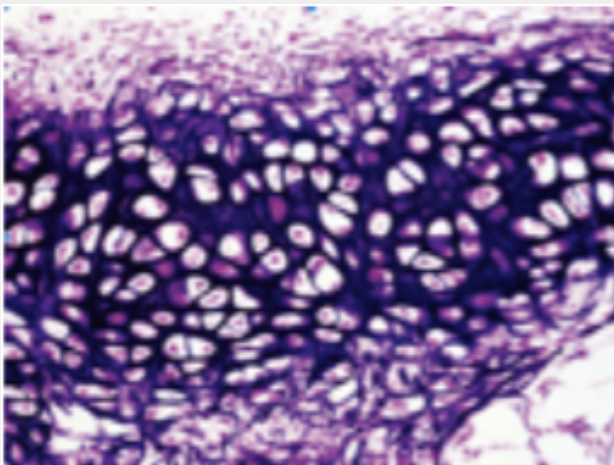
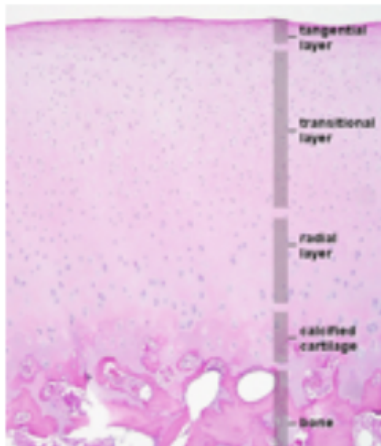


Coupes histologiques

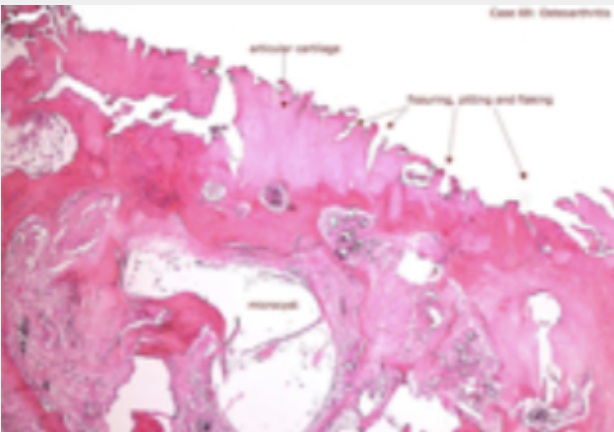
Photo	Légende
	<p>Tissu cartilagineux Chondrocytes MO</p>
	<p>Tissu cartilagineux Périchondre 1 : externe / 2 : interne MO</p>
	<p>Chondrocyte ME</p>
	<p>Croissance interstitielle MO</p>
	<p>Croissance interstitielle MO</p>
	<p>Cartilage fibreux (=fibrocartilage) MO</p>



Cartilage élastique  
MO



Cartilage articulaire  
MO



Arthrose  
MO