


An anatomical illustration of a bird's head and neck, viewed from the side. The illustration is color-coded to highlight different anatomical regions: the top of the head is light blue, the back of the head and neck is green, the throat and upper chest area is pink, the lower chest and belly area is orange, and the neck and throat area is yellow. The bird's beak is dark grey. The background is white.

# ANATOMIE DE LA TÊTE ET DU COU – UE<sub>12</sub>

---

# Mais Keske c'est?

---




15h de cours (4 ou 5 ronéos)

Assurés en totalité par le Pr De Peretti (FDP pour les intimes)

15 QCMs au Concours (en 20min)

60 points faciles!!

Les tuteurs: Virgile (alias Santiperetti) et Lan Bao (aka Lan Baobab)





# OSTÉOLOGIE DU CRÂNE

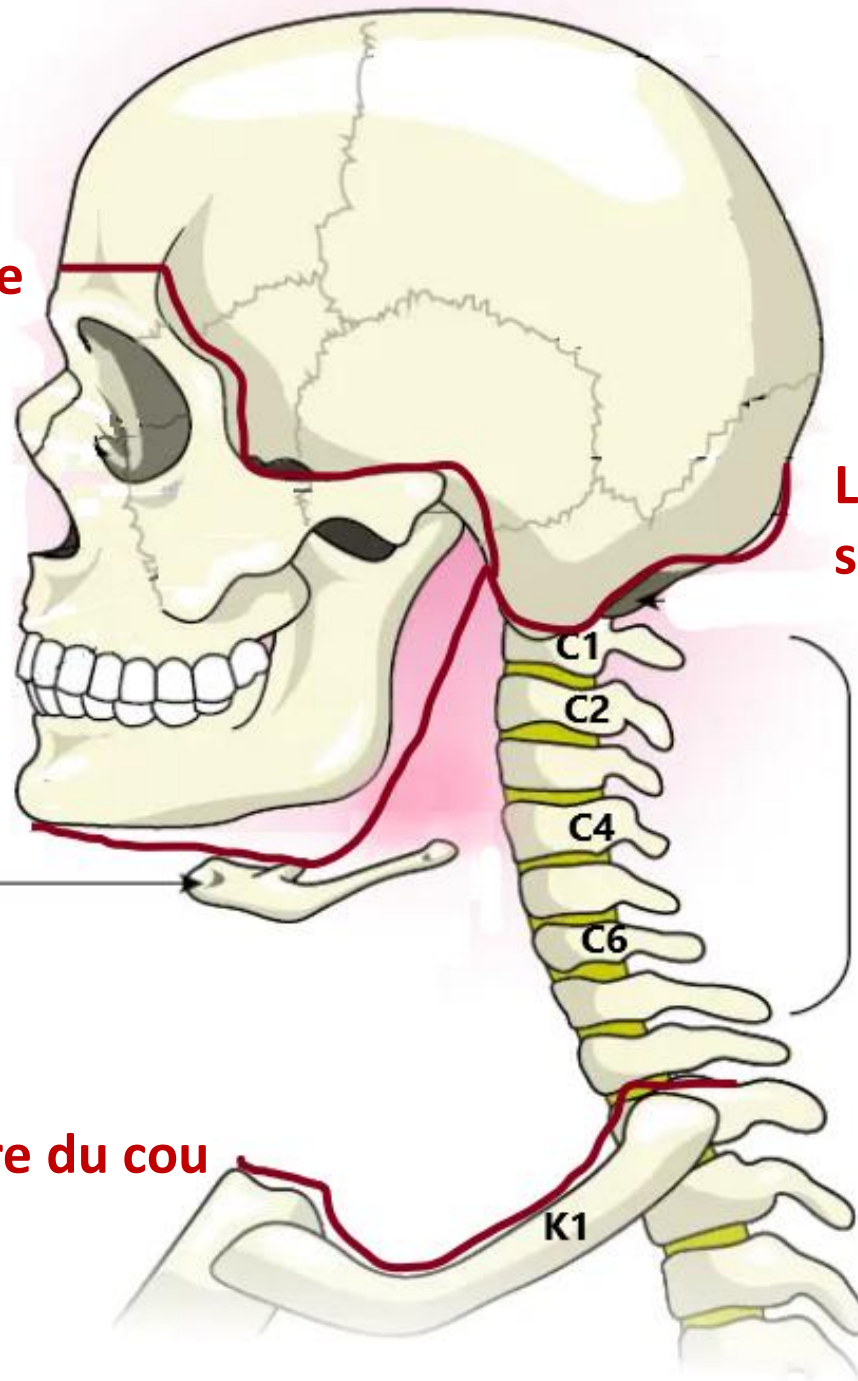
**Ligne supérieure de la face**

**Ligne inférieure de la face =  
supérieure du cou**

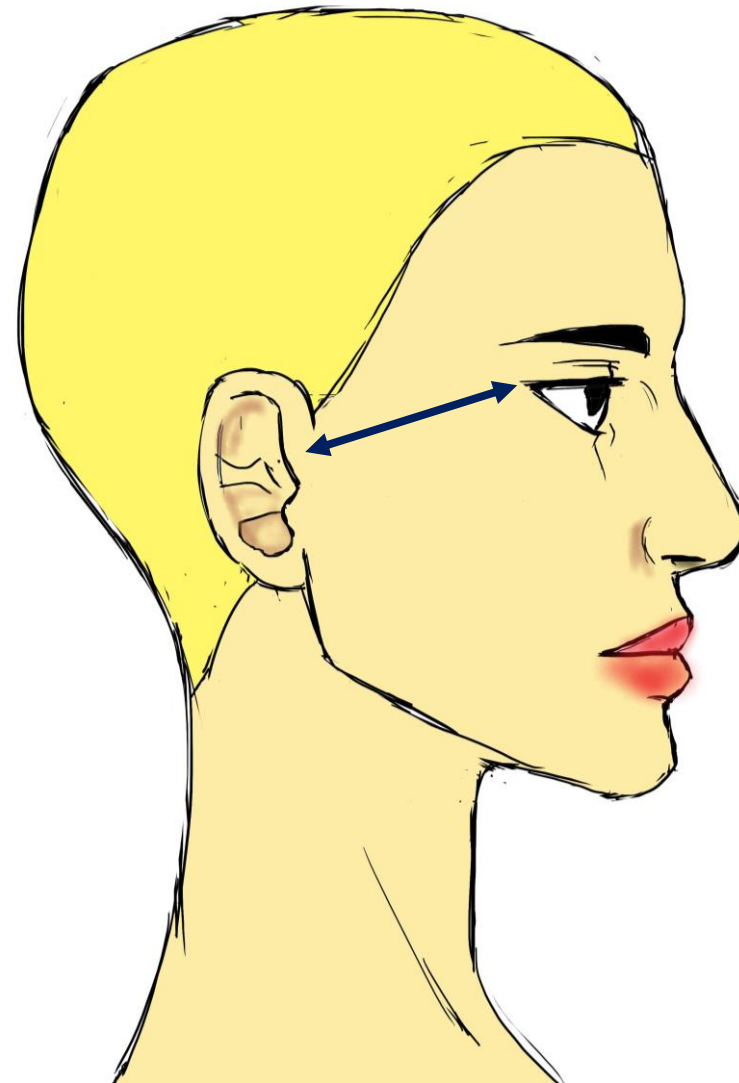
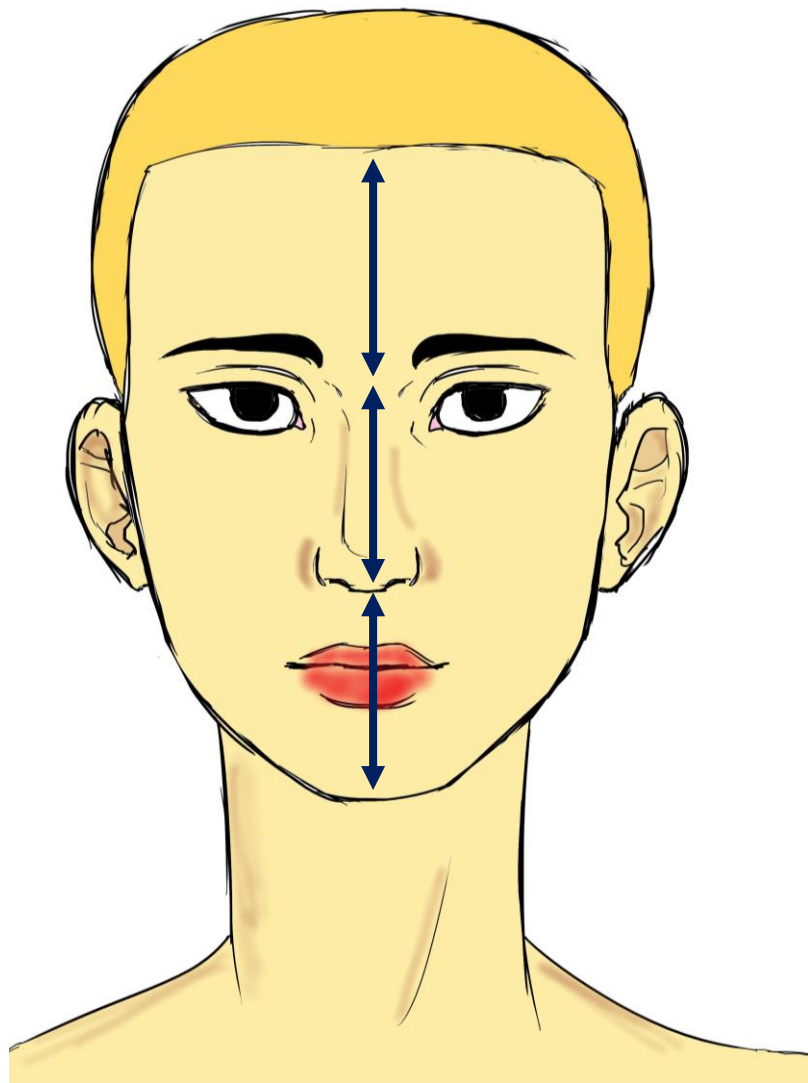
Os hyoïde

Vertèbres (ou rachis)  
Cervicales

**Ligne inférieure du cou**



# Règle du pouce de Léonard de Vinci

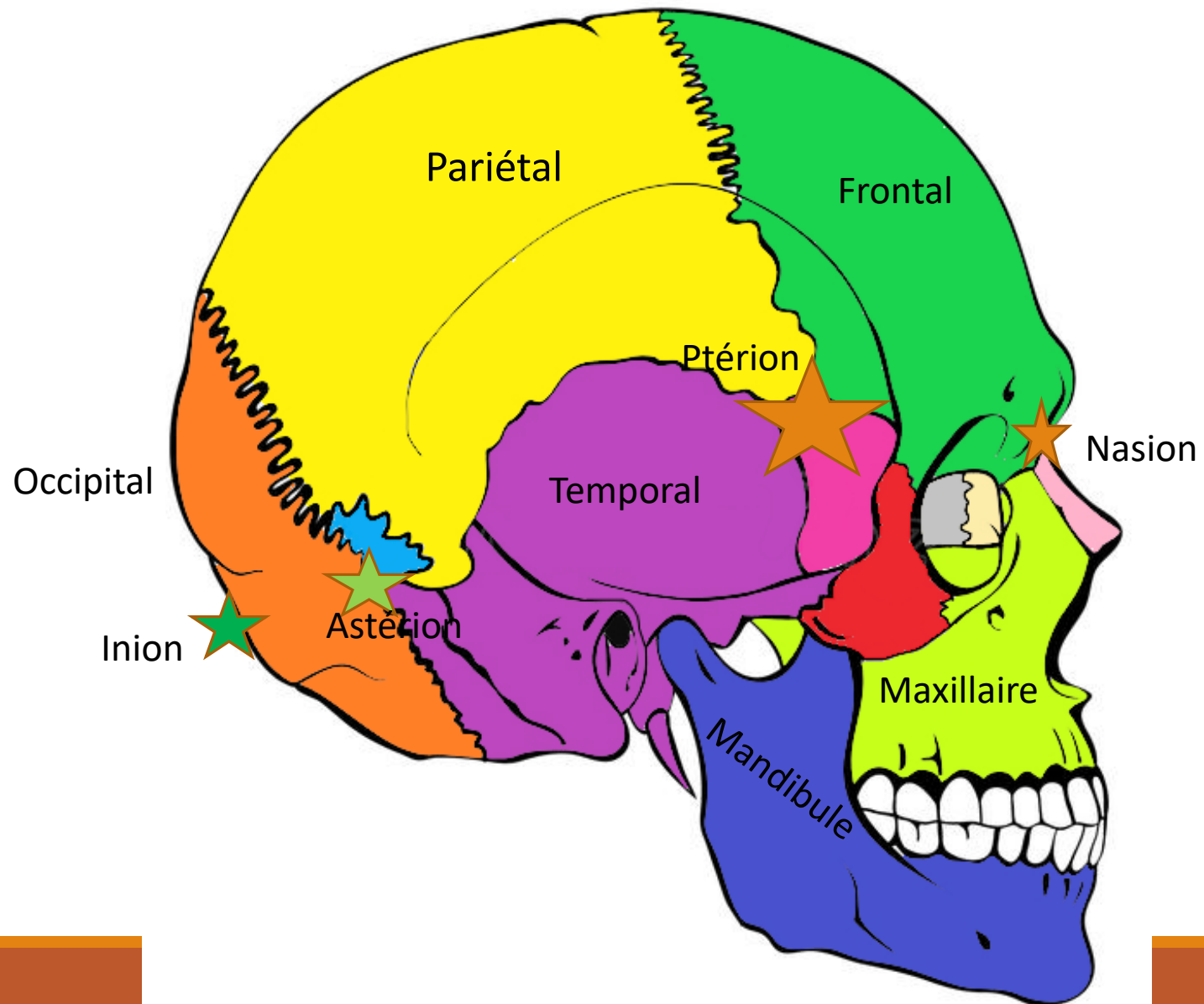


**LEVEL UP!!**

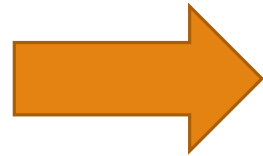


**LEVEL 1 ACHIEVED**

# Crâne en vue de profil



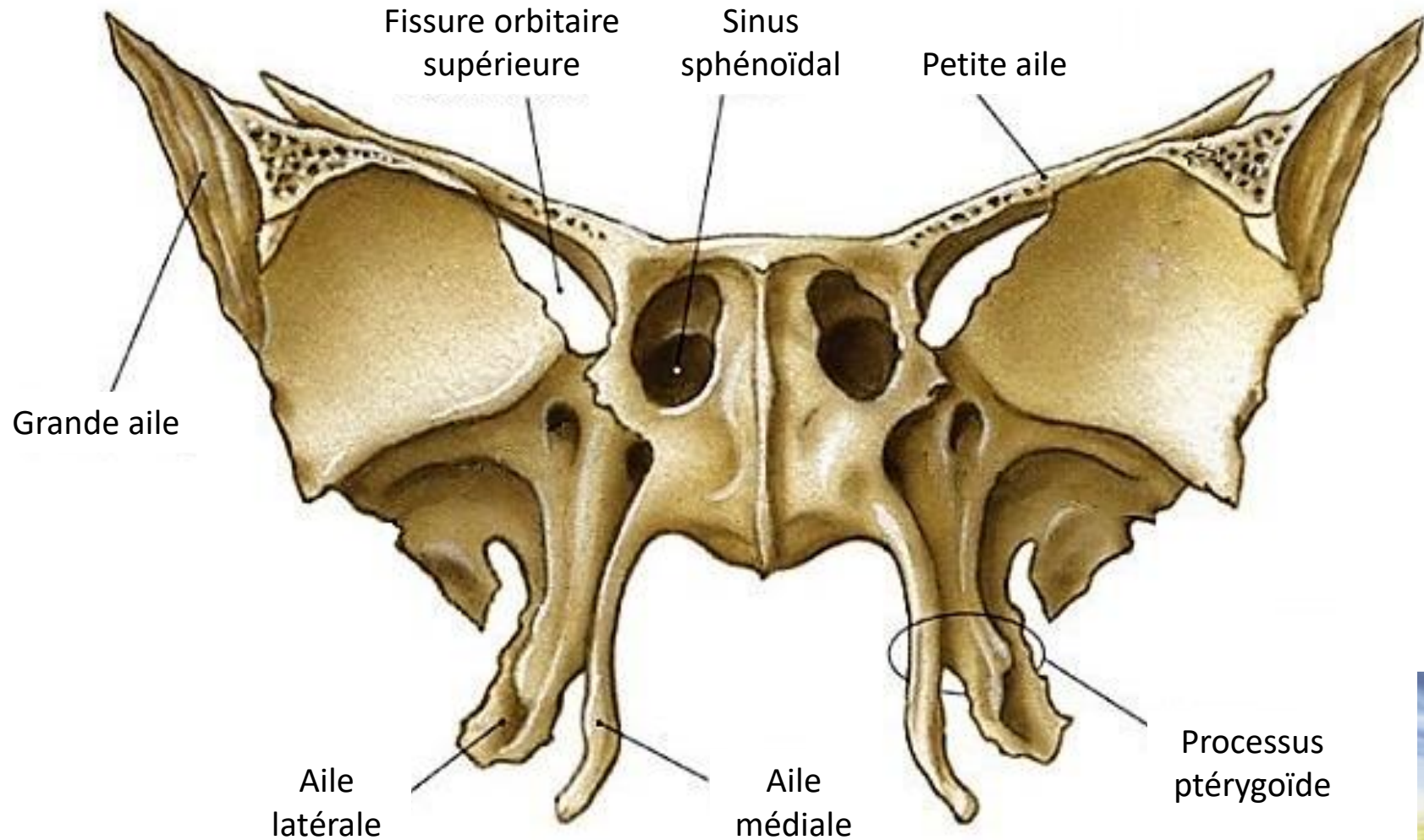
Mandibule



Mendiant

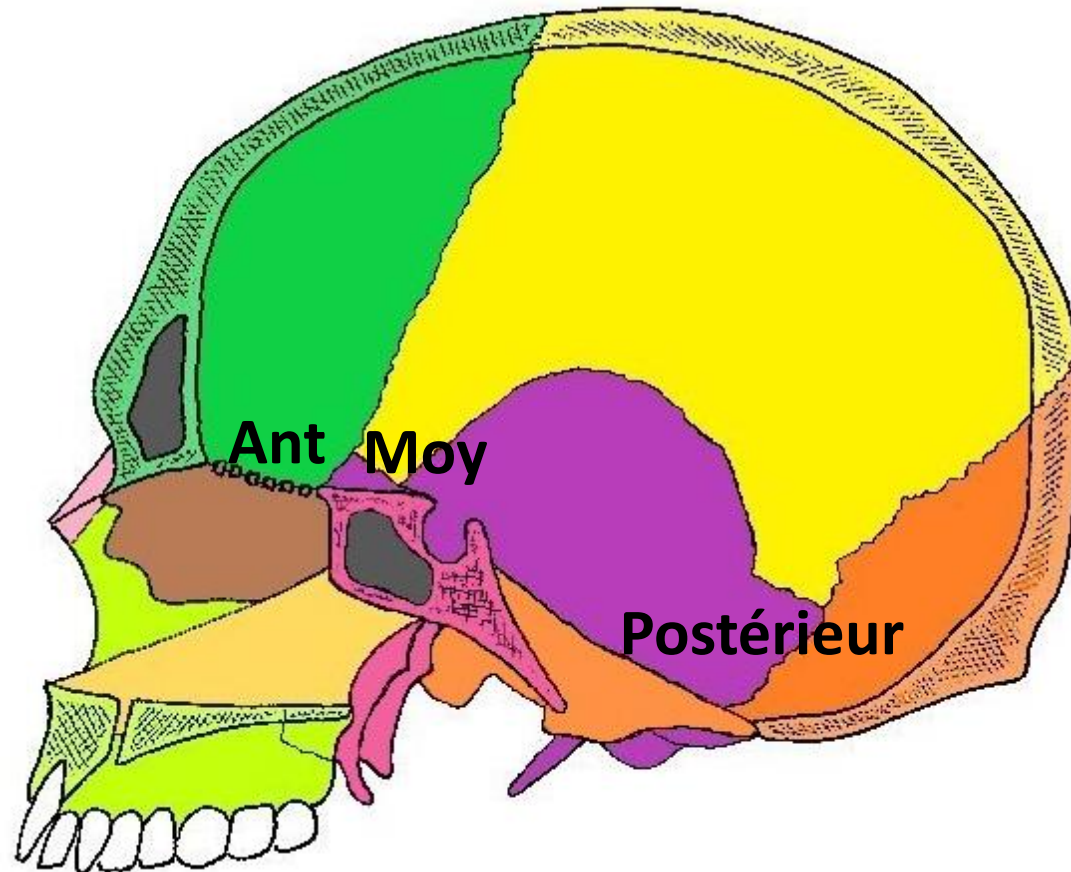


# L'os sphénoïde

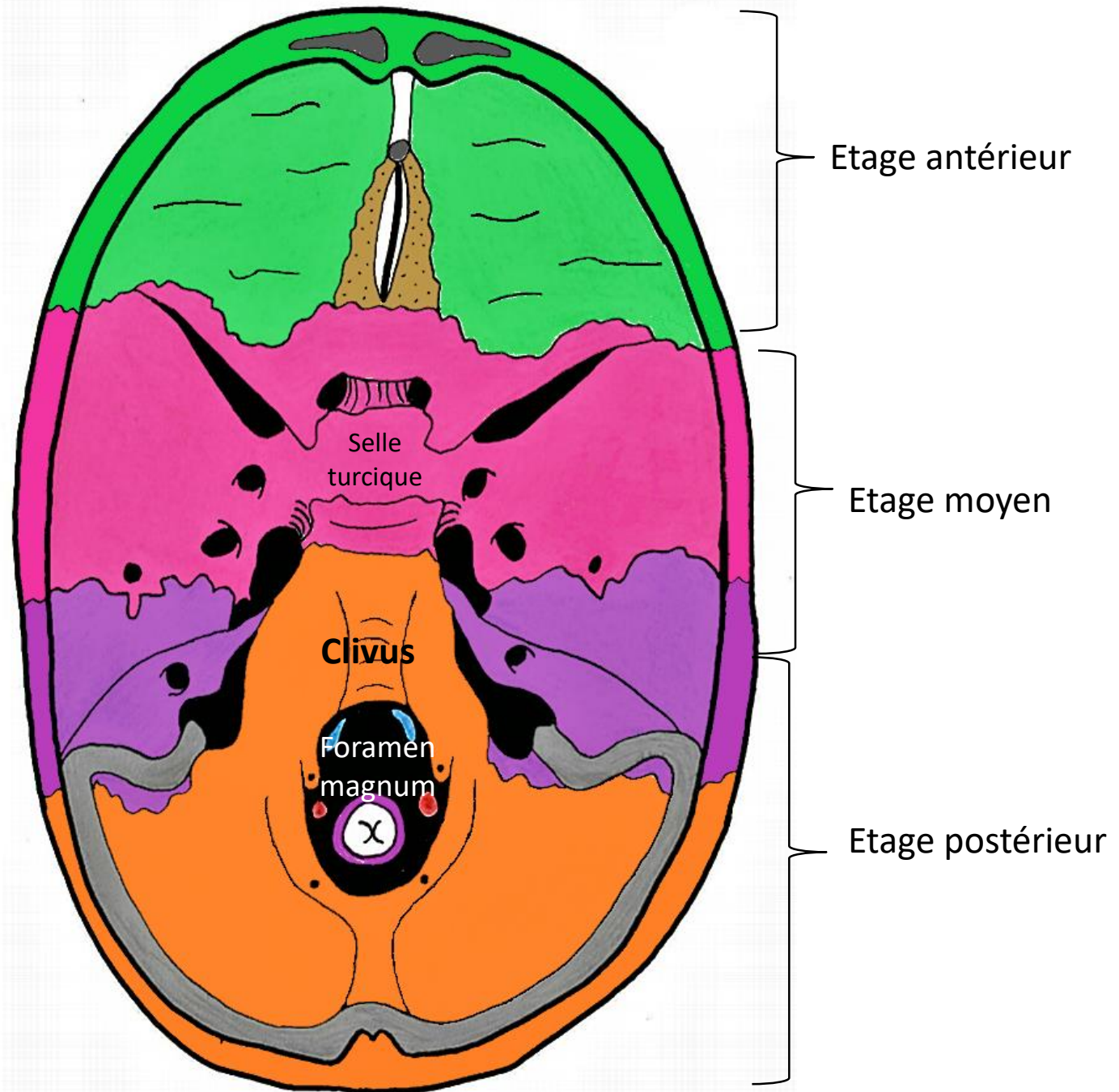


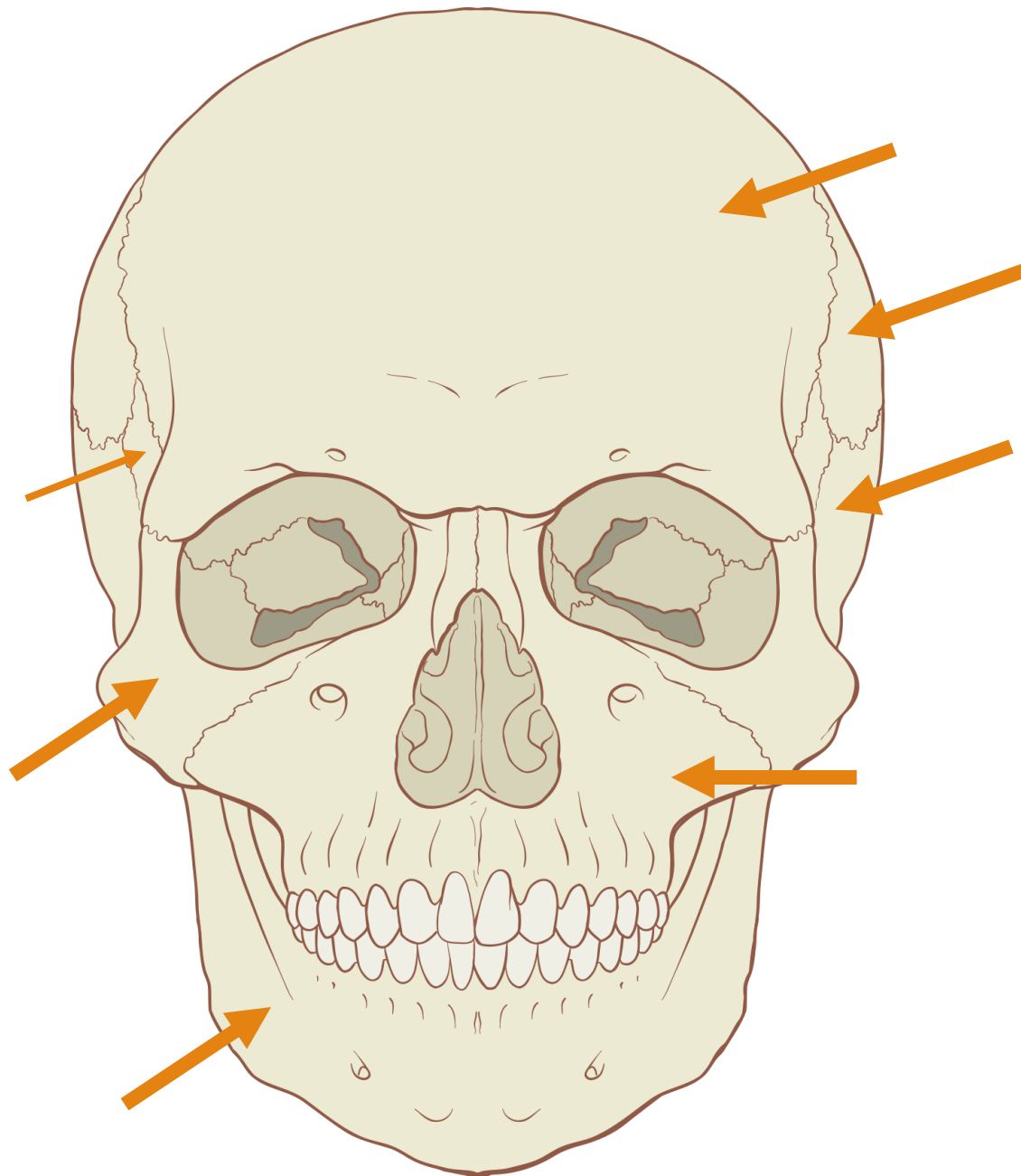
# Base du crâne

---



# Vue endocrânienne





Petit quizz...

Vue?