
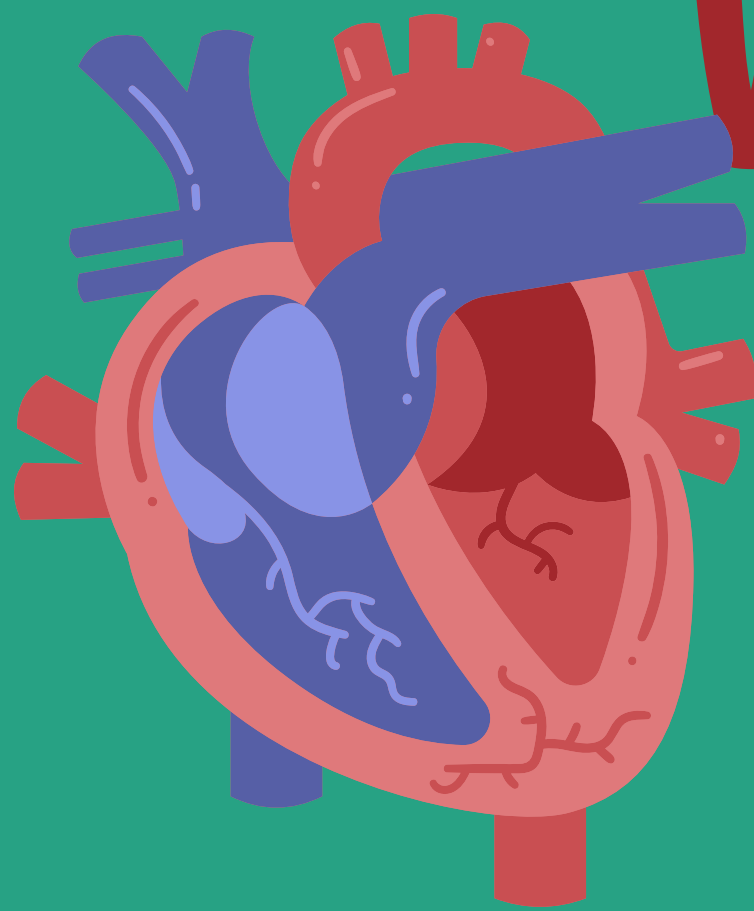
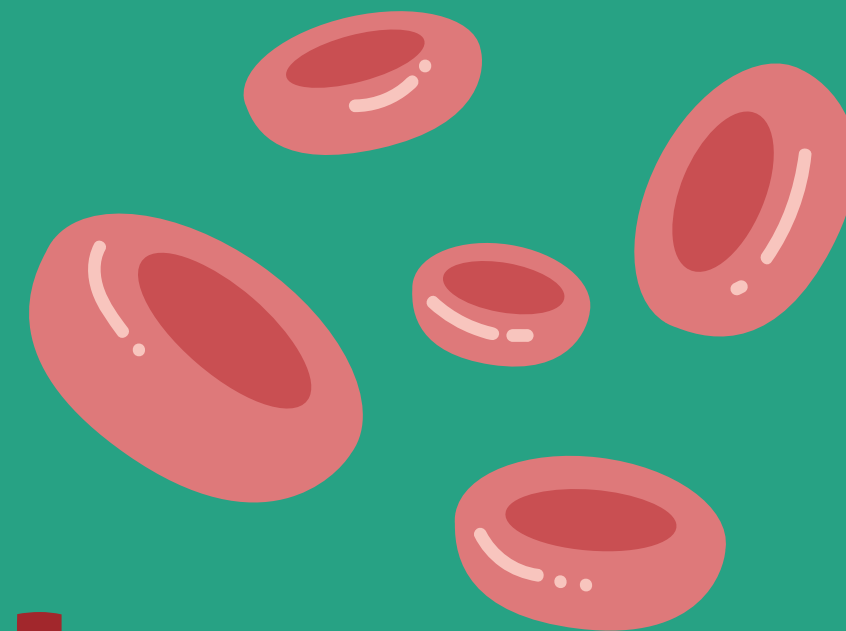
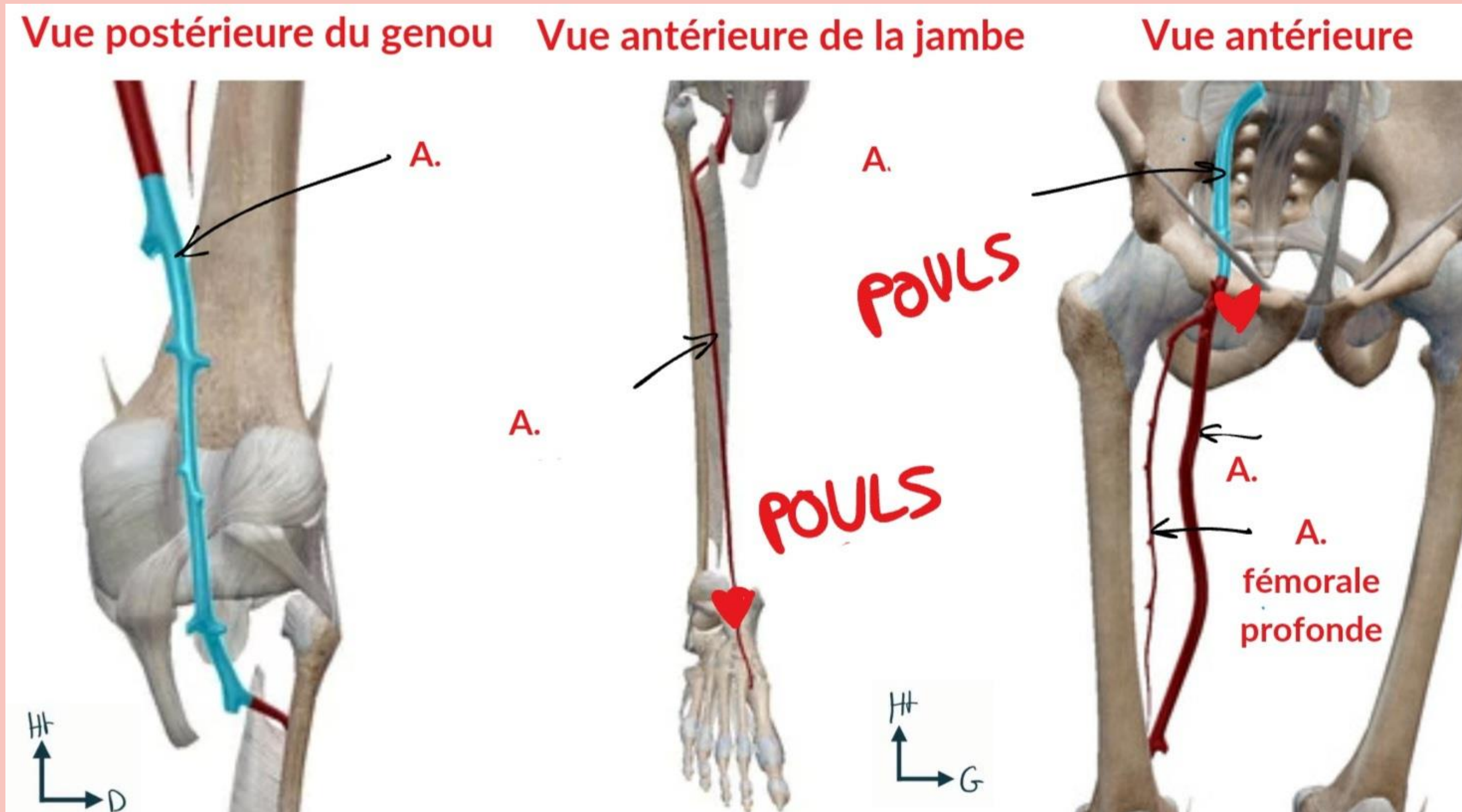



RÉCAP ULTIME VASCULARISATION MEMBRES

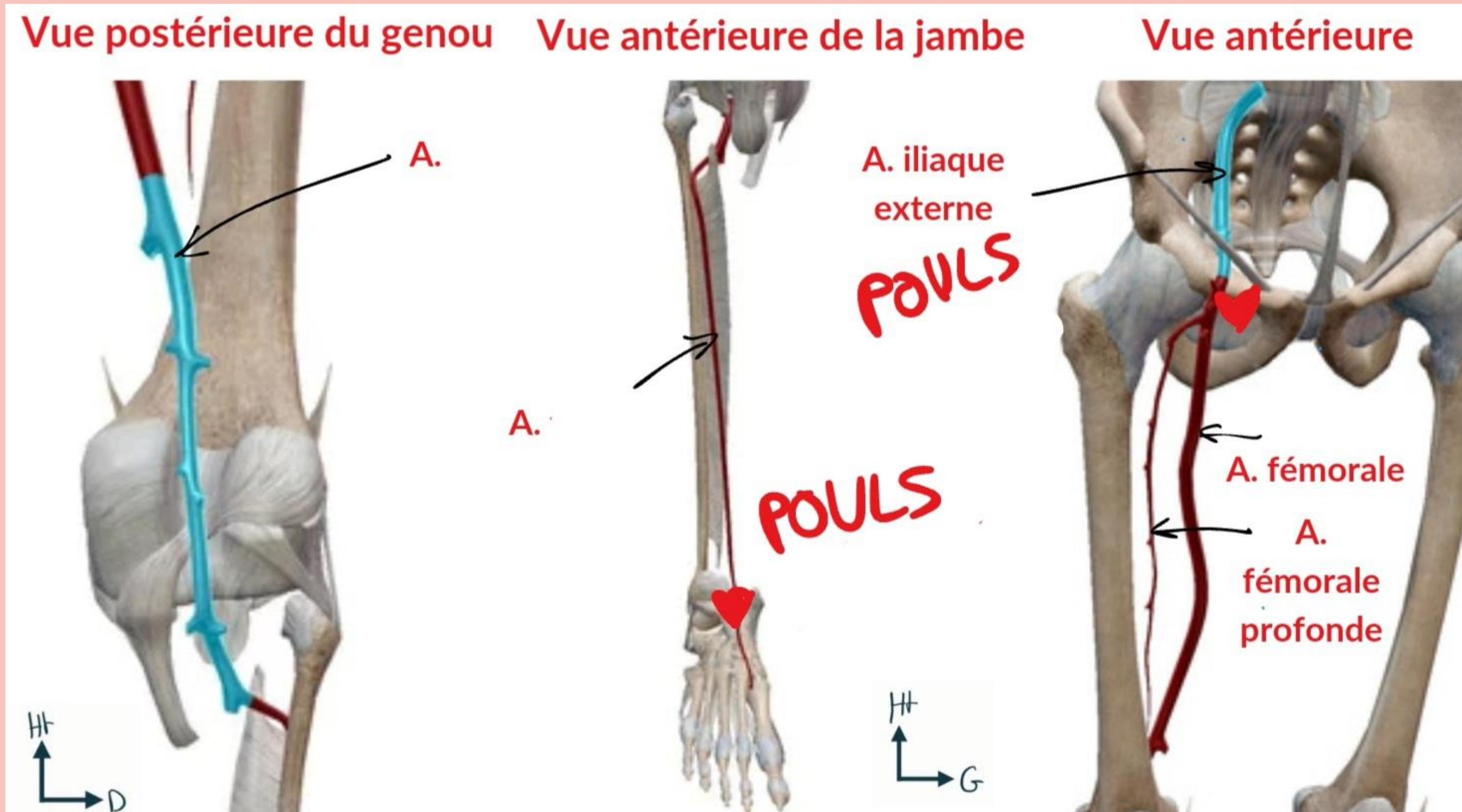

Pour avoir vla la
connaissance à l'exam



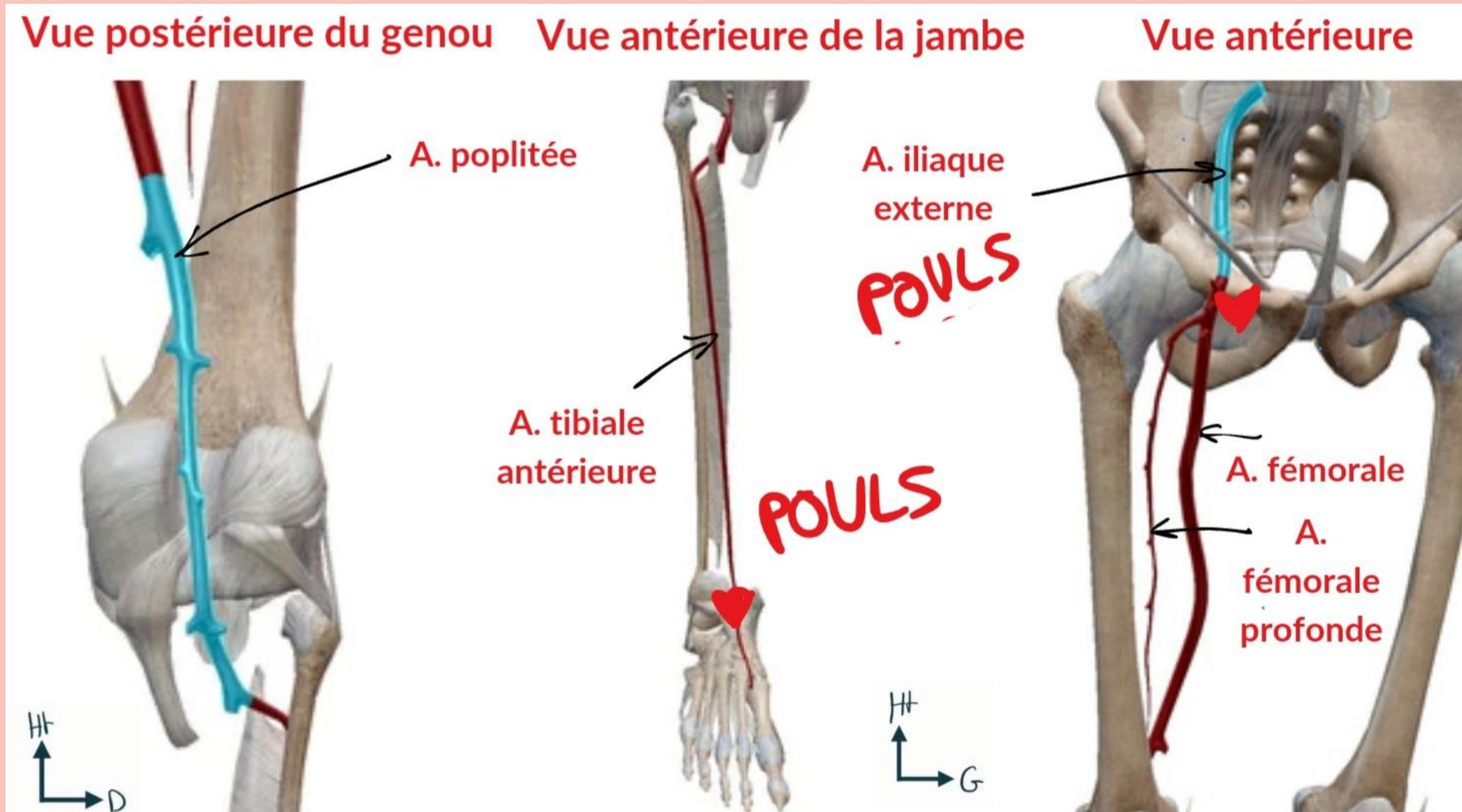

CIRCULATION ARTÉRIELLE MI



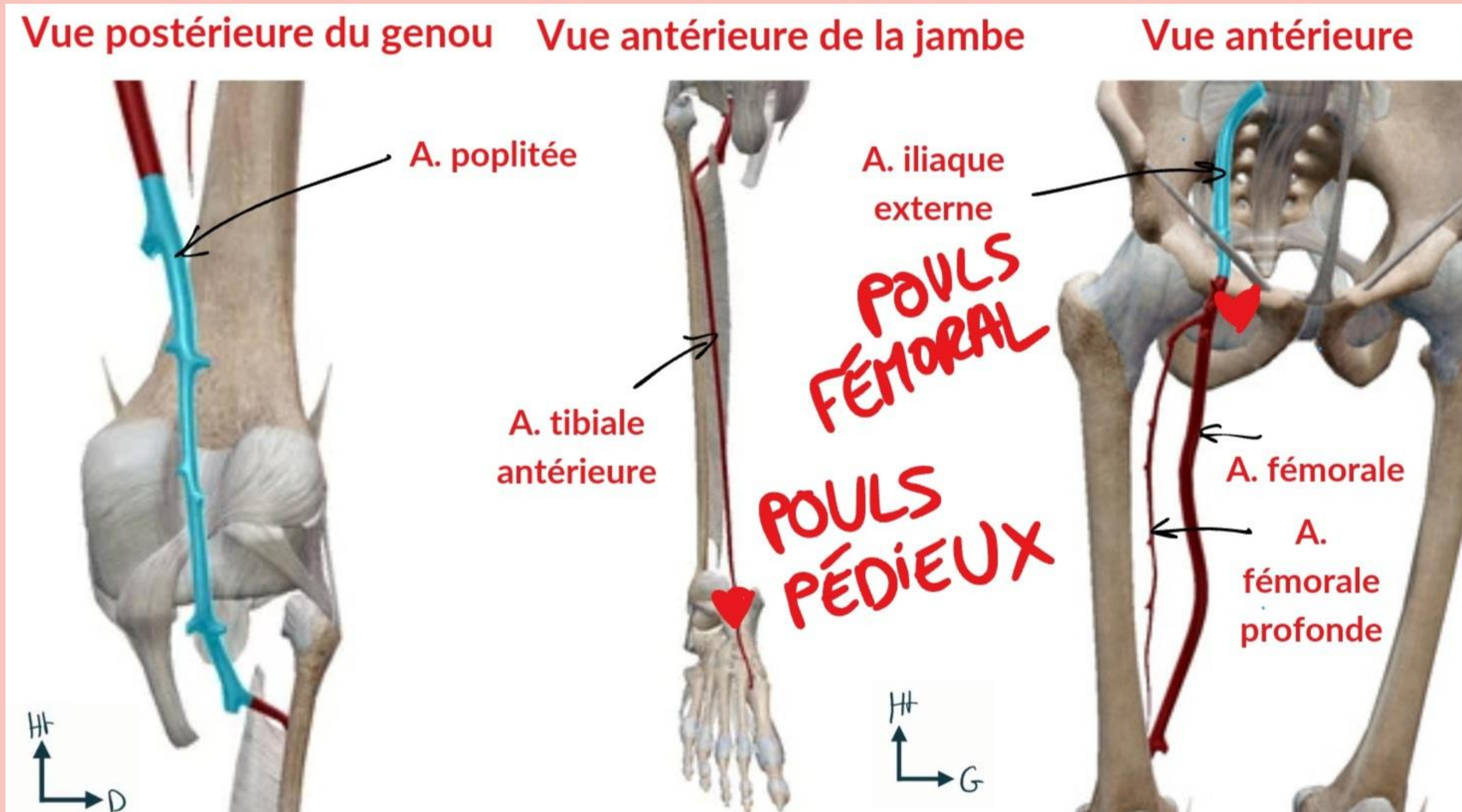

CIRCULATION ARTÉRIELLE MI



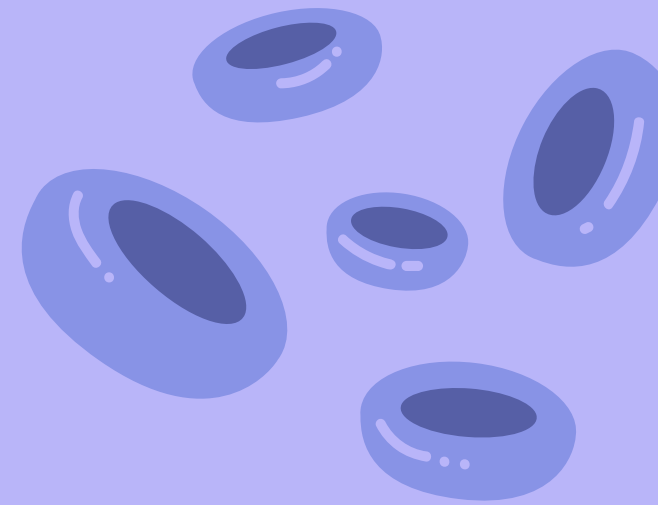
CIRCULATION ARTÉRIELLE MI



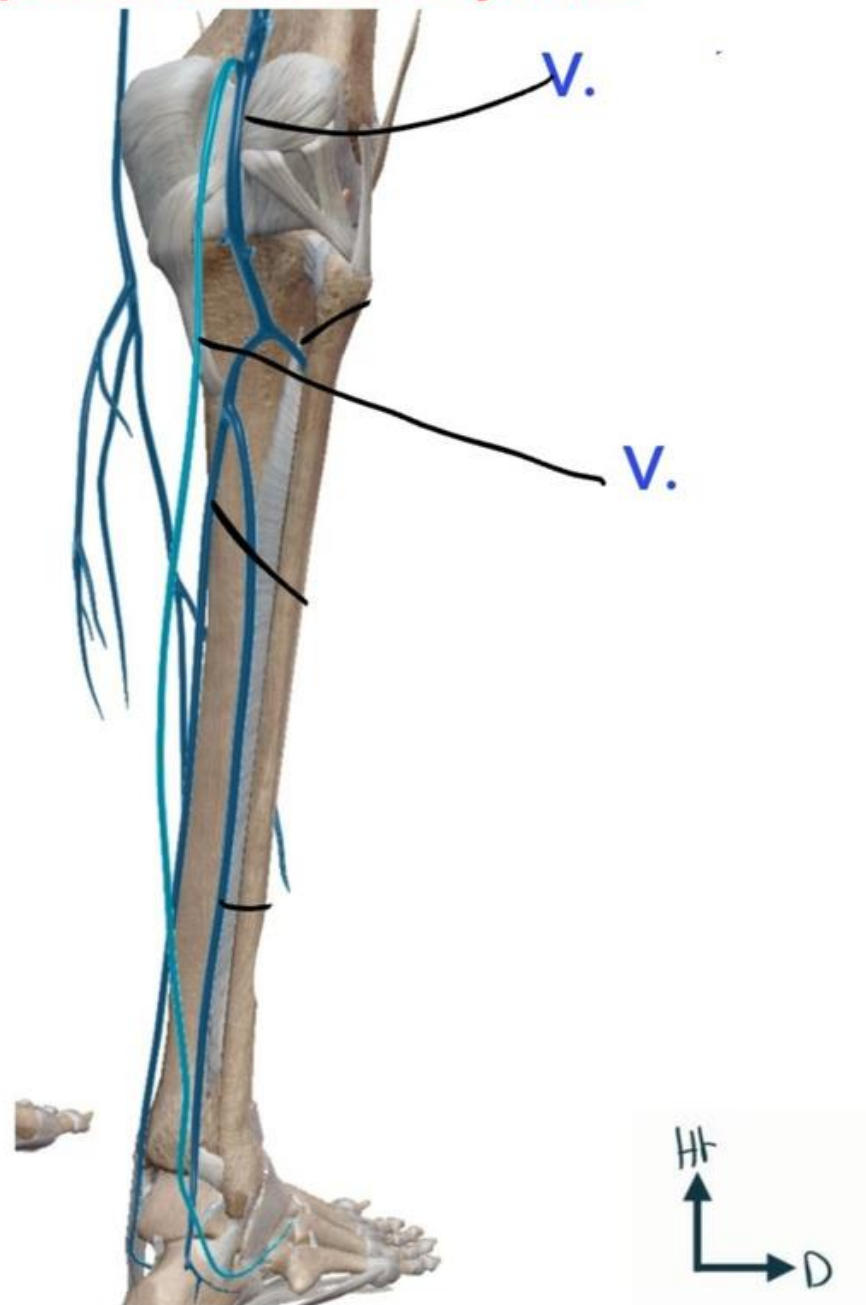
CIRCULATION ARTÉRIELLE MI



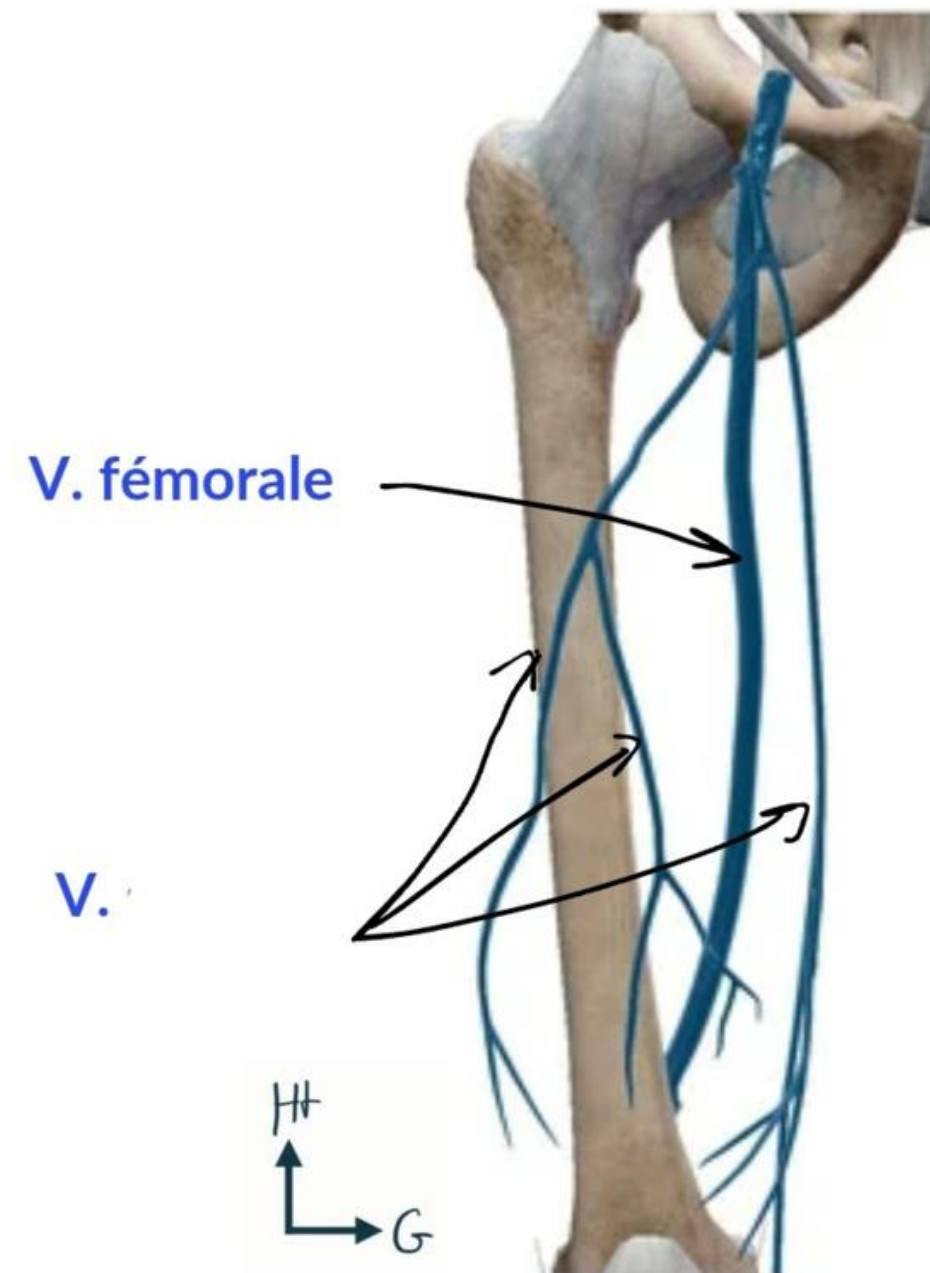
CIRCULATION VEINEUSE MI



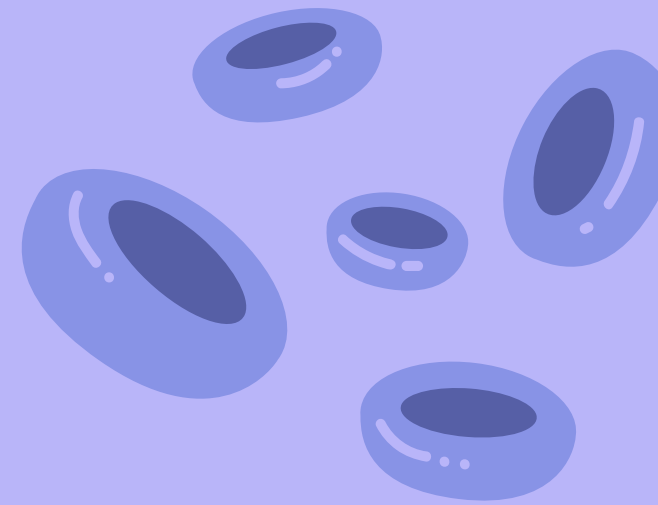
Vue postérieure de la jambe



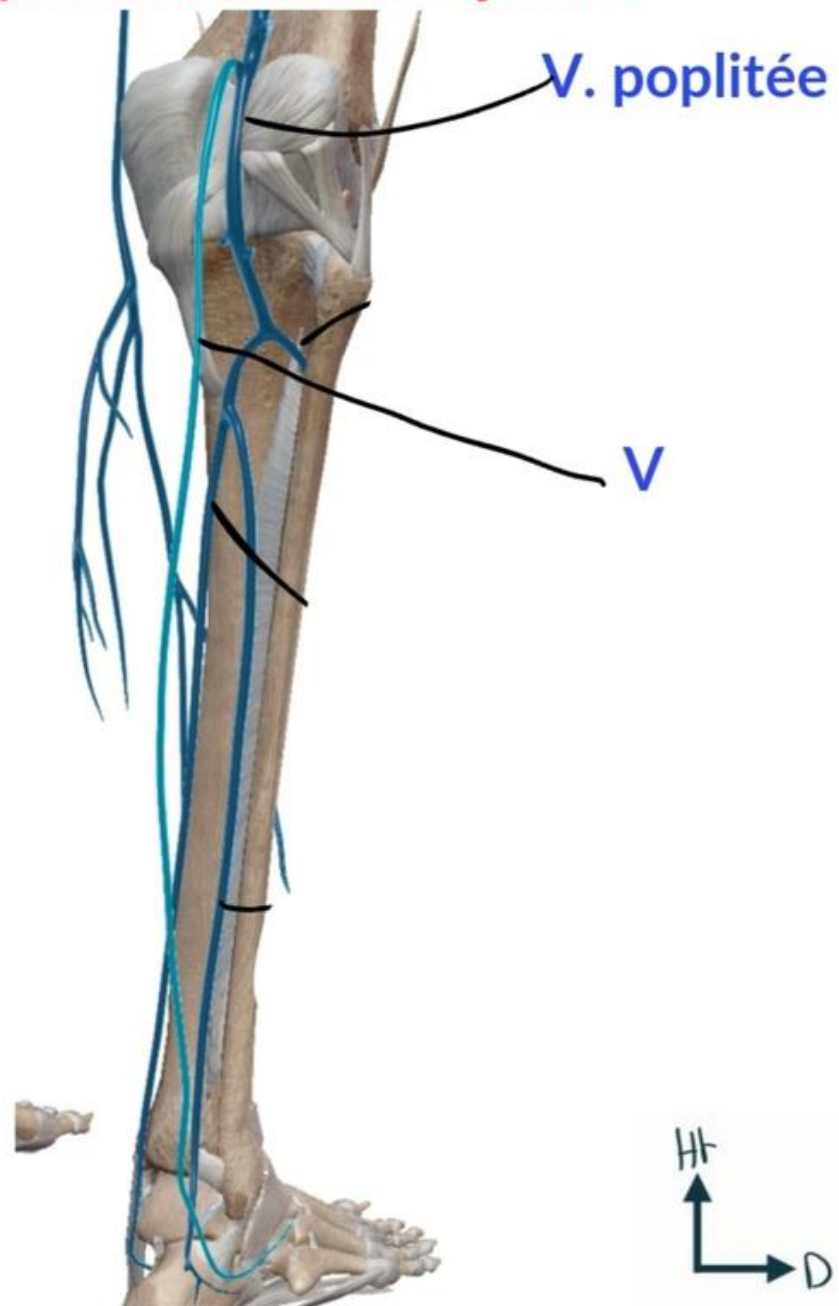
Vue antérieure de la cuisse



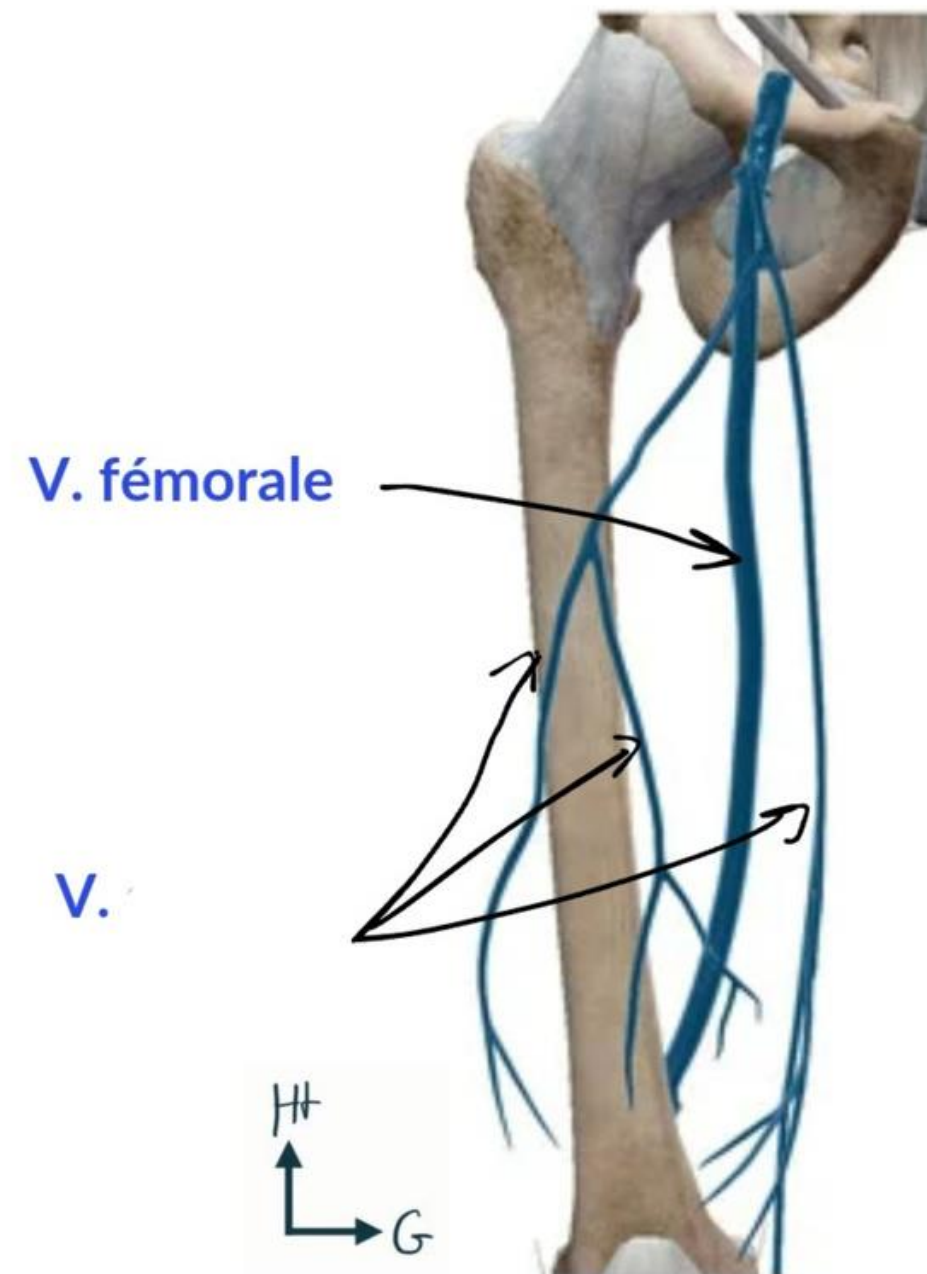
CIRCULATION VEINEUSE MI



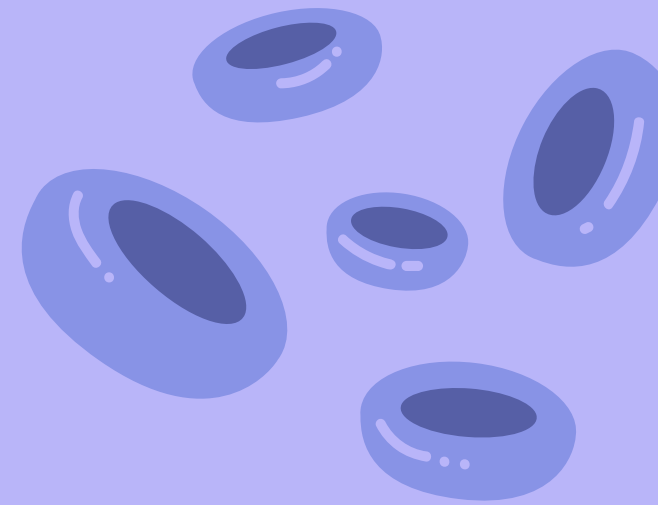
Vue postérieure de la jambe



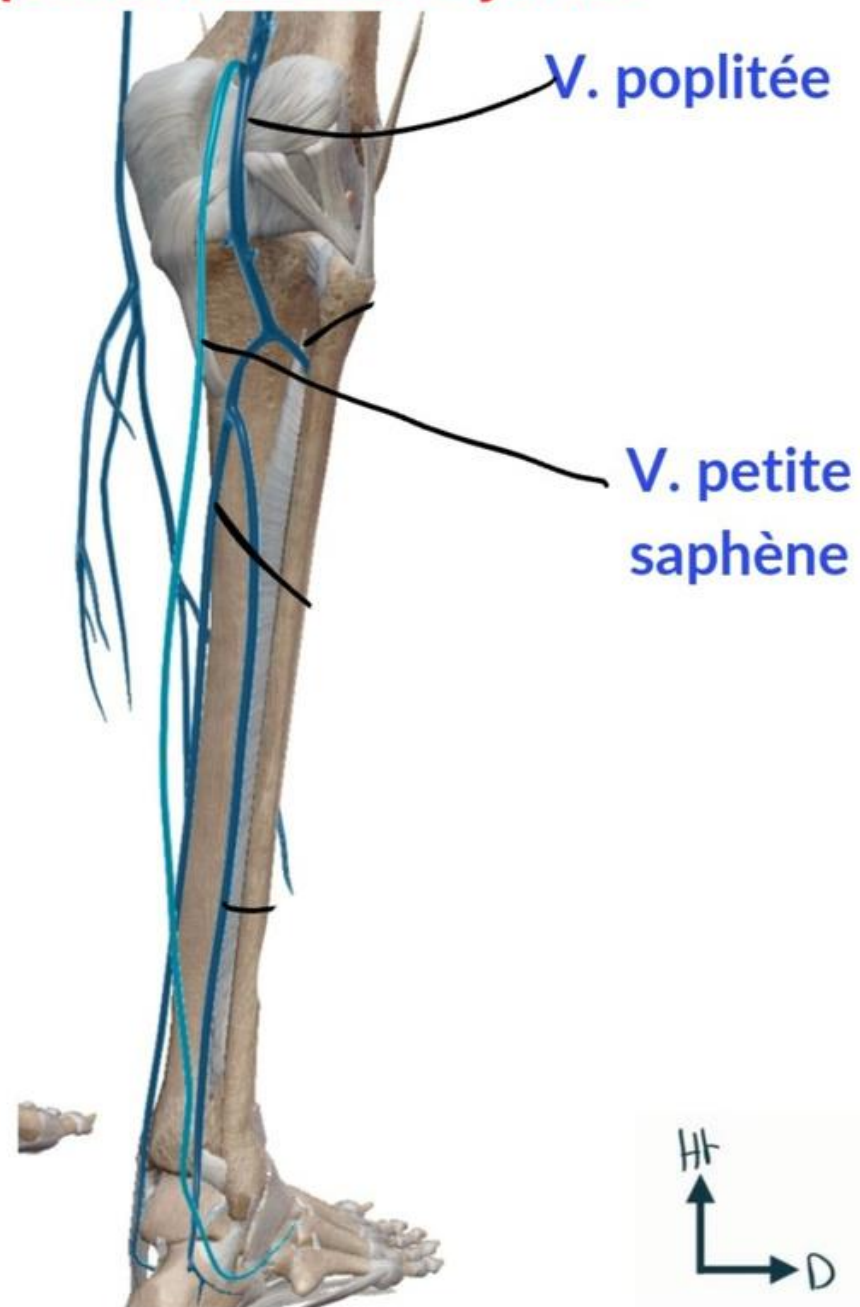
Vue antérieure de la cuisse



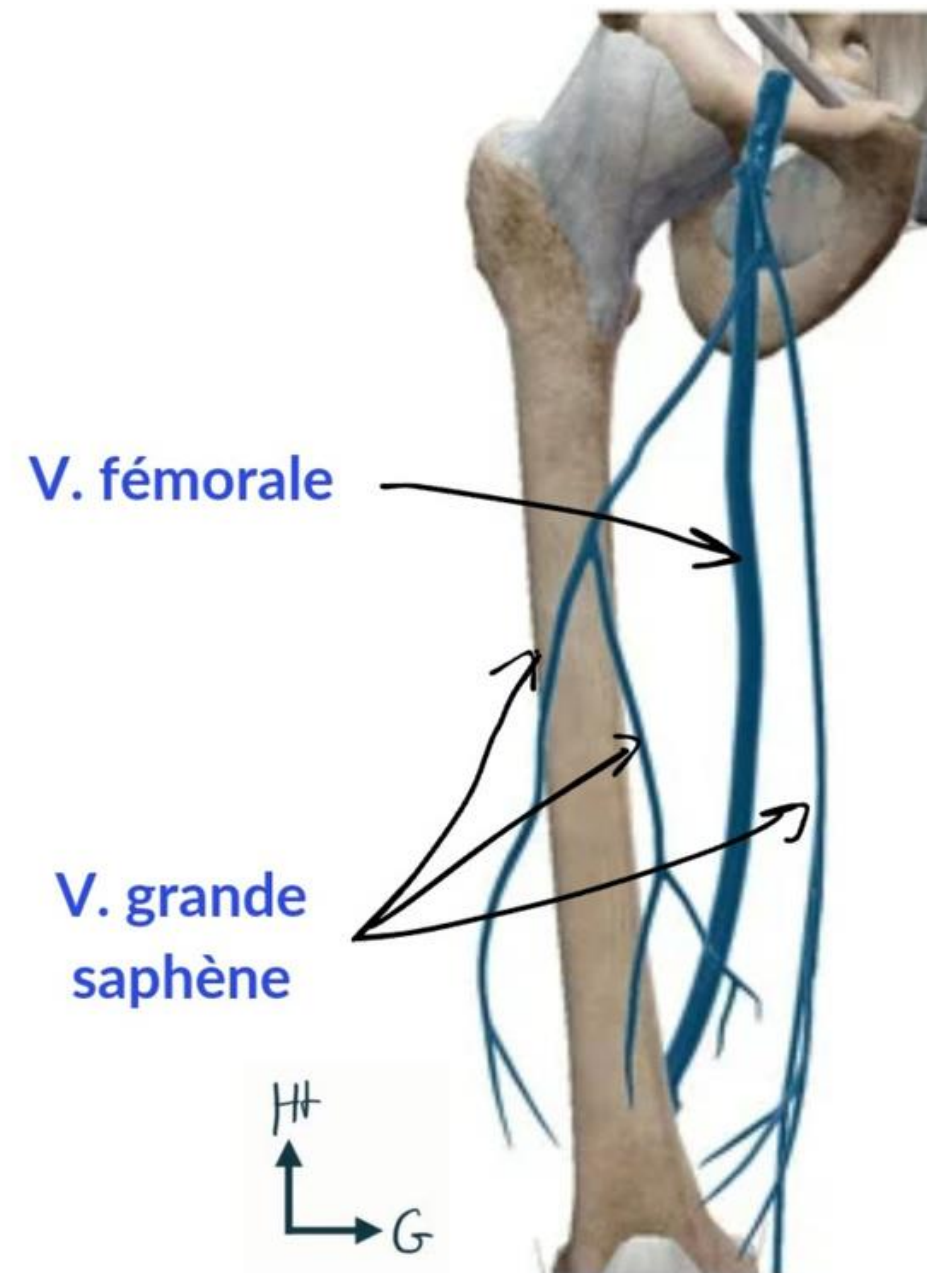
CIRCULATION VEINEUSE MI



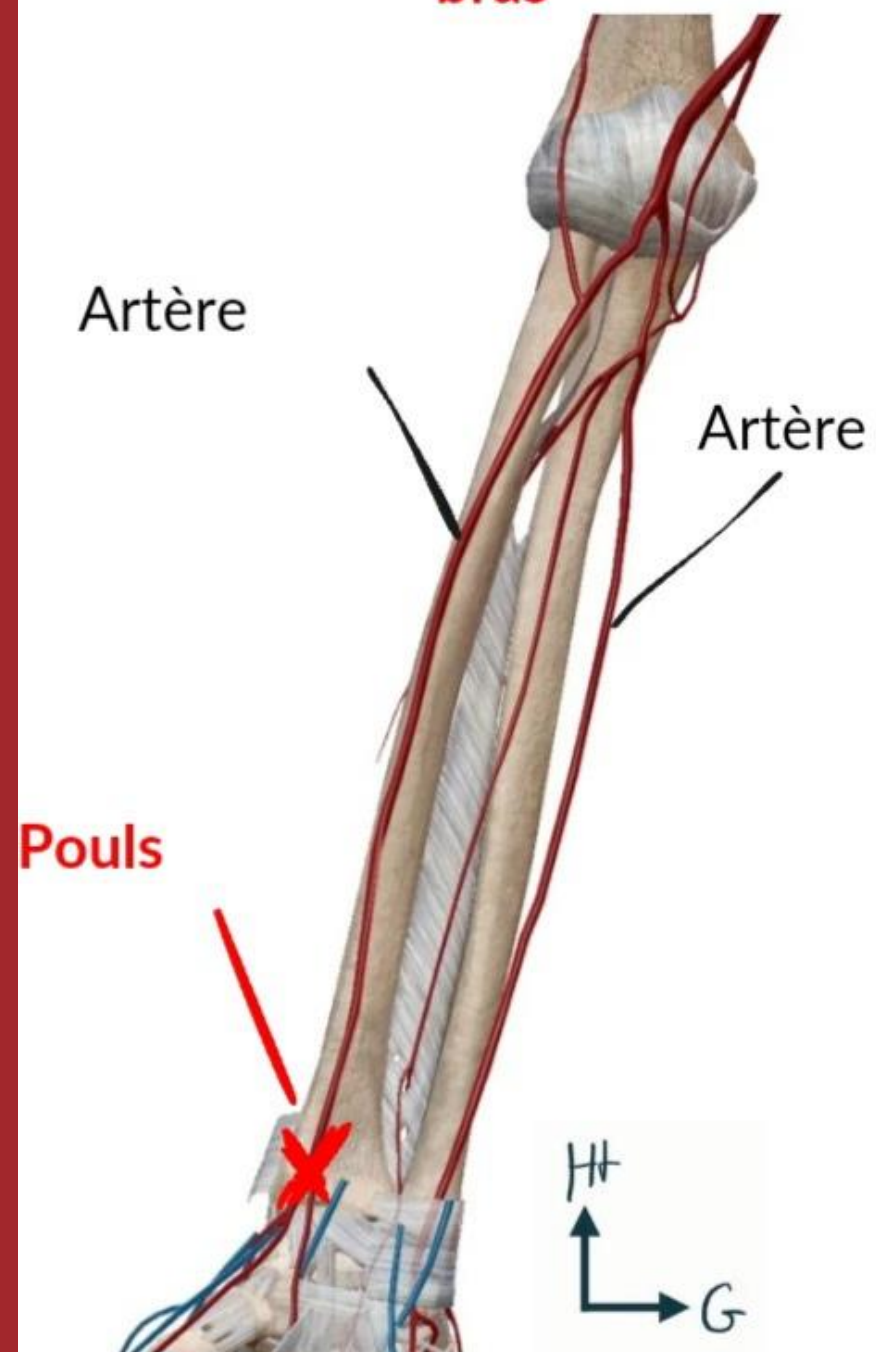
Vue postérieure de la jambe



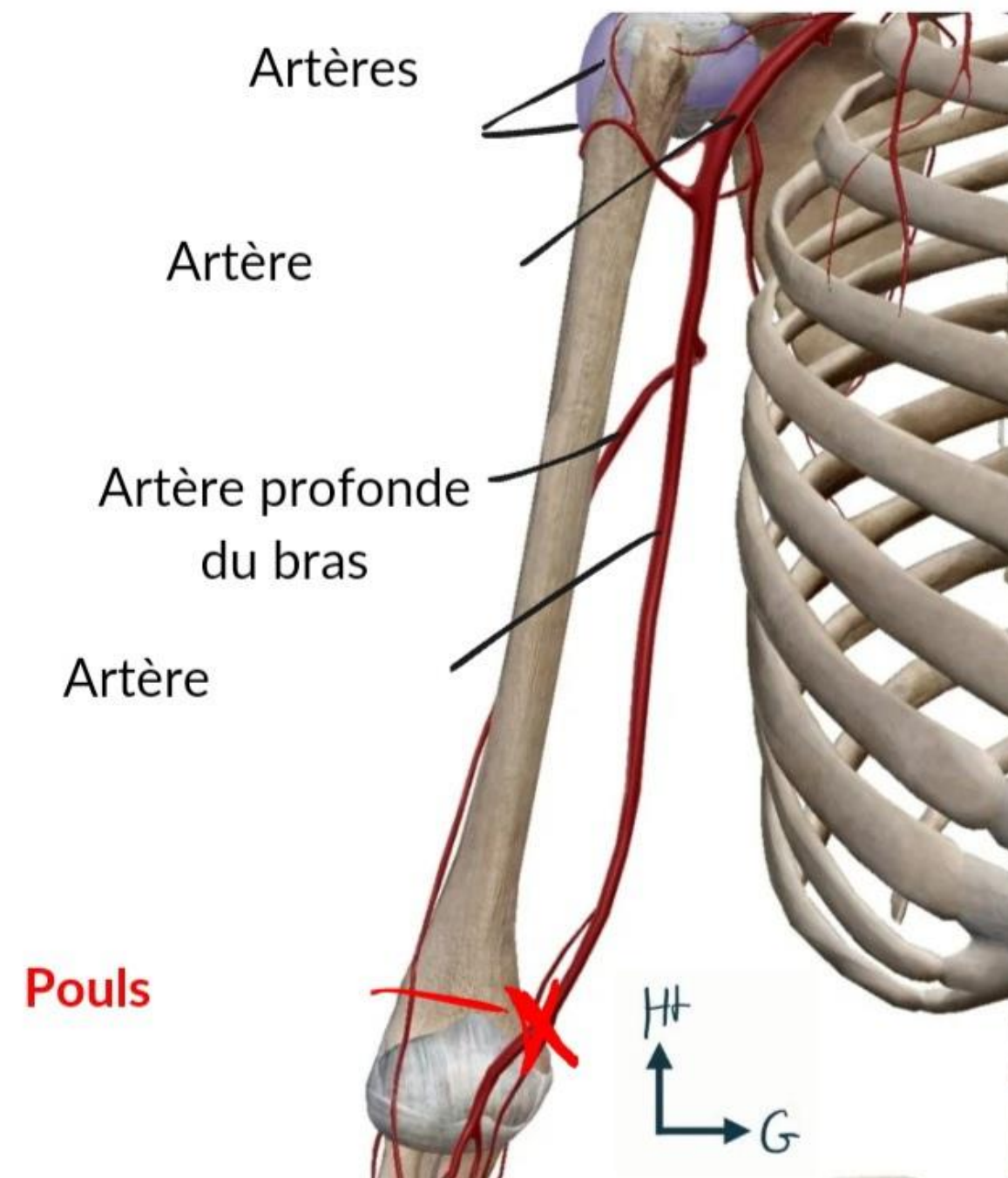
Vue antérieure de la cuisse



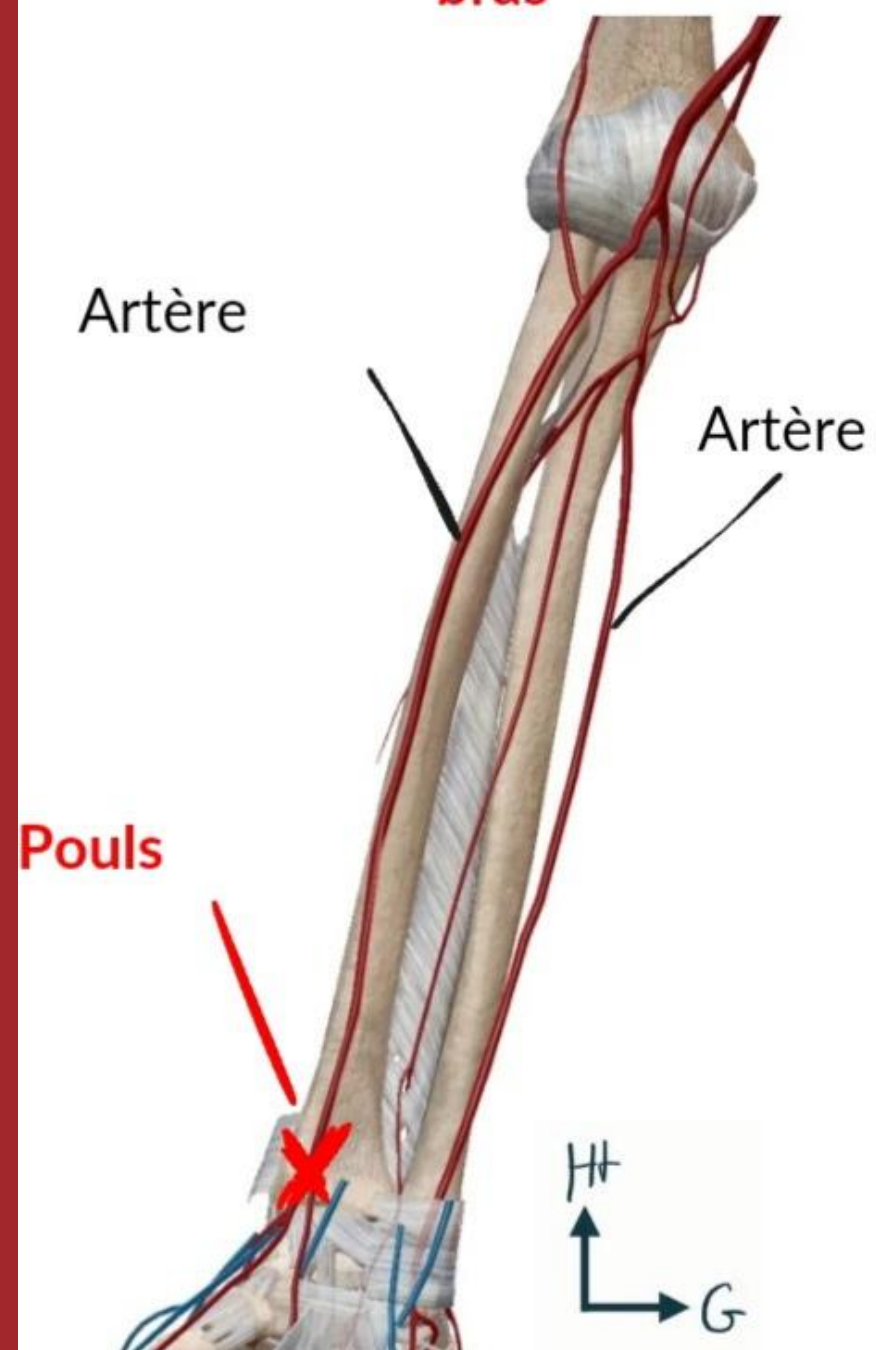
Vue antérieure de l'avant-bras



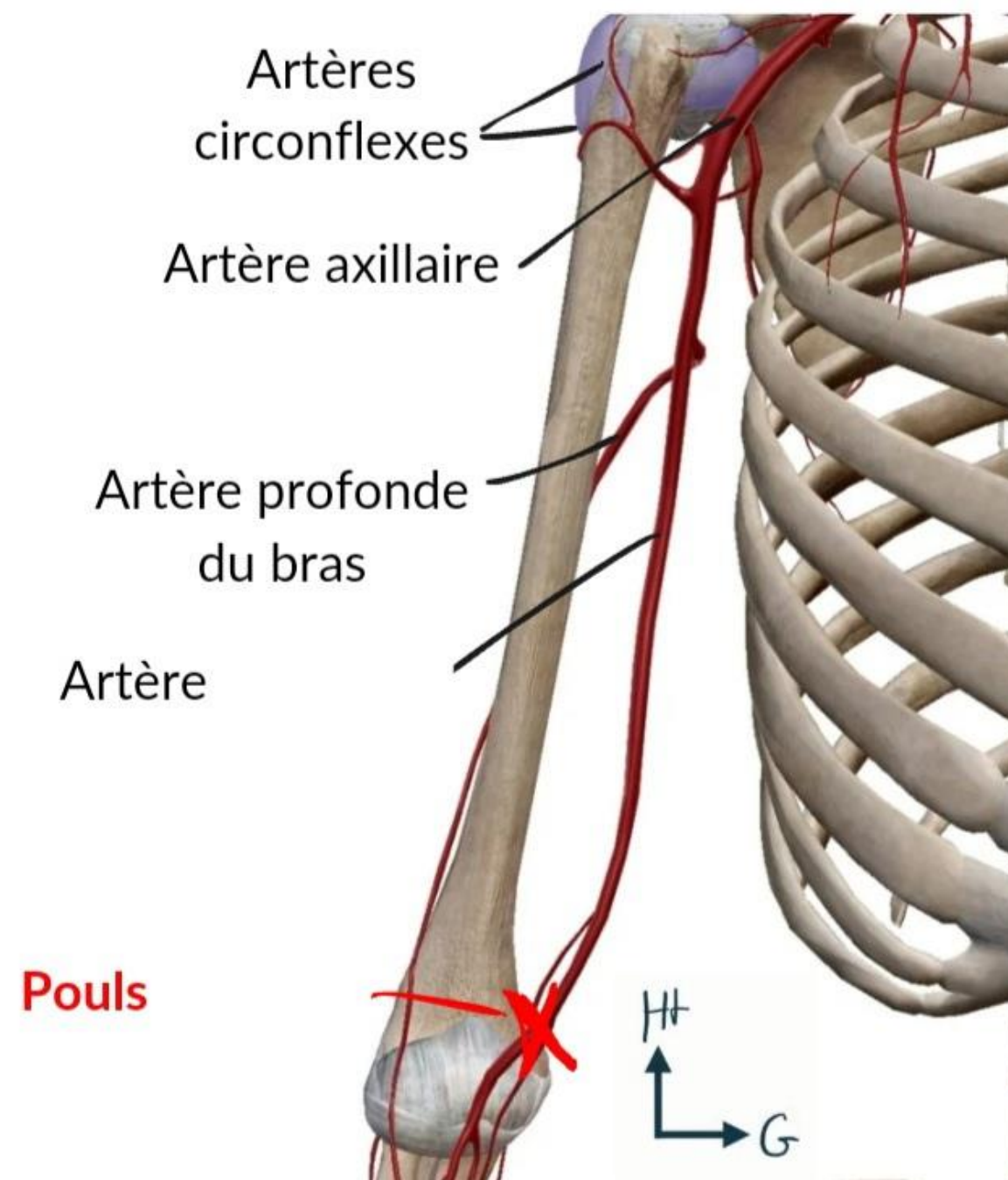
Vue antérieure du bras



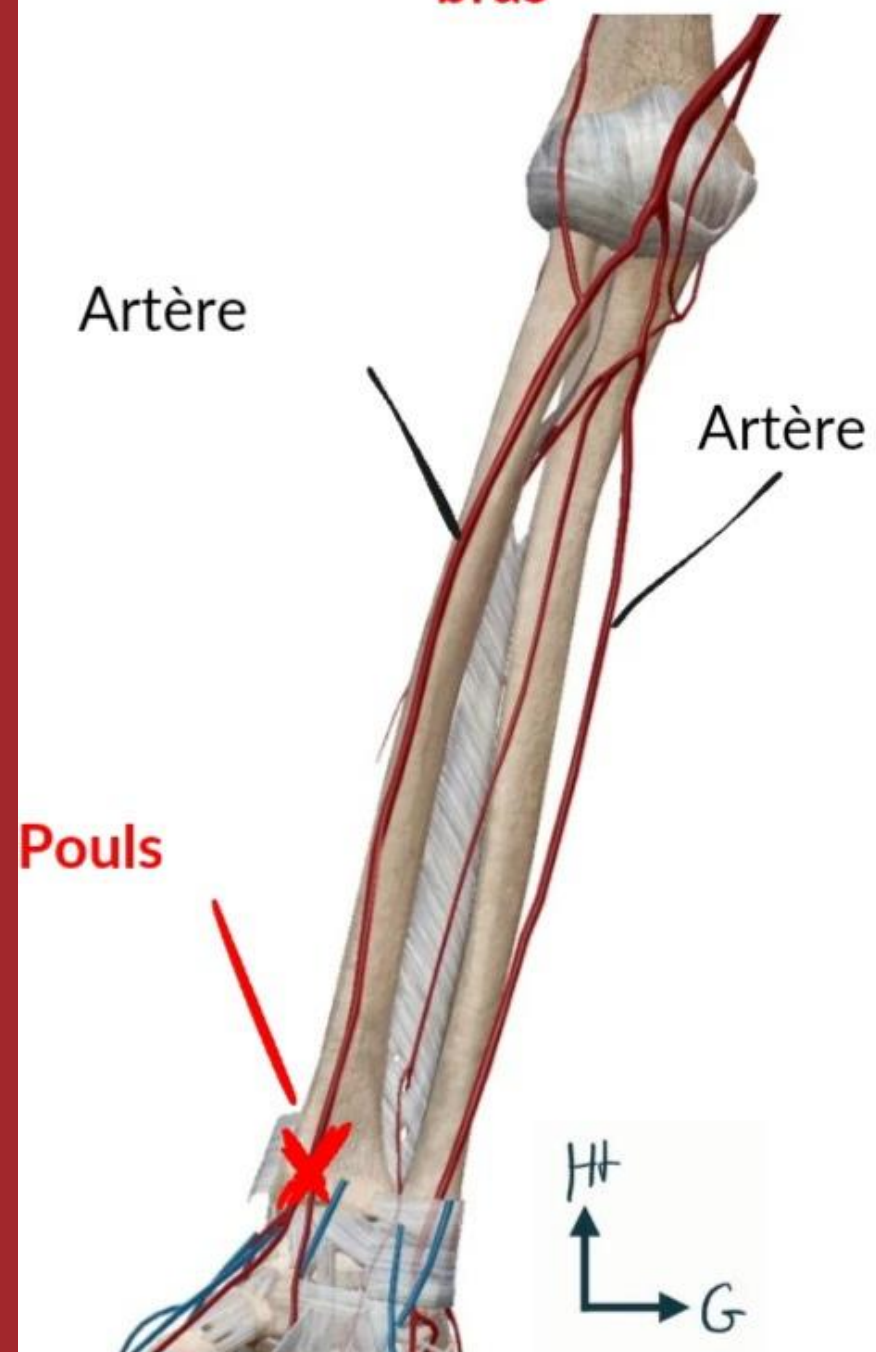
Vue antérieure de l'avant-bras



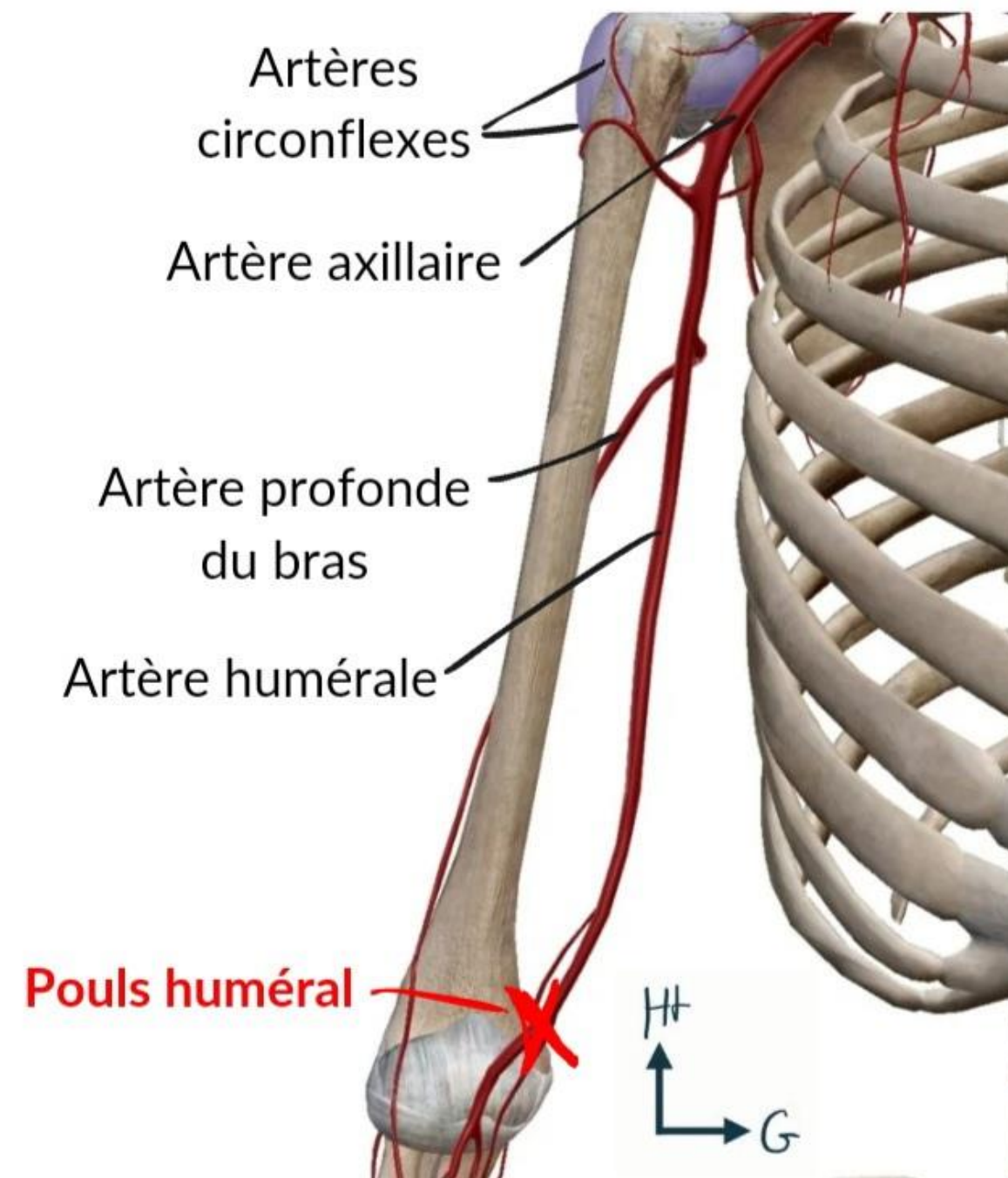
Vue antérieure du bras



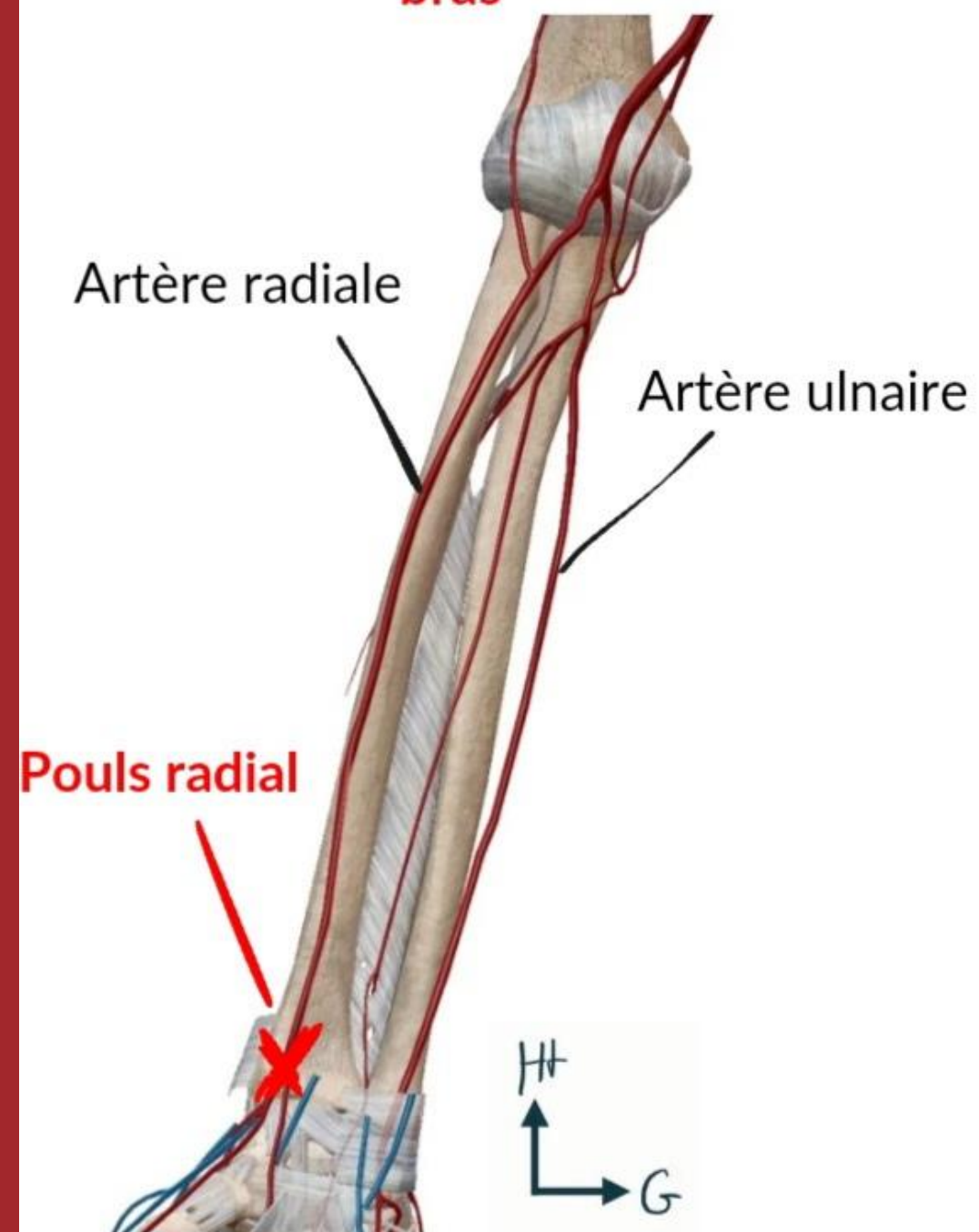
Vue antérieure de l'avant-bras



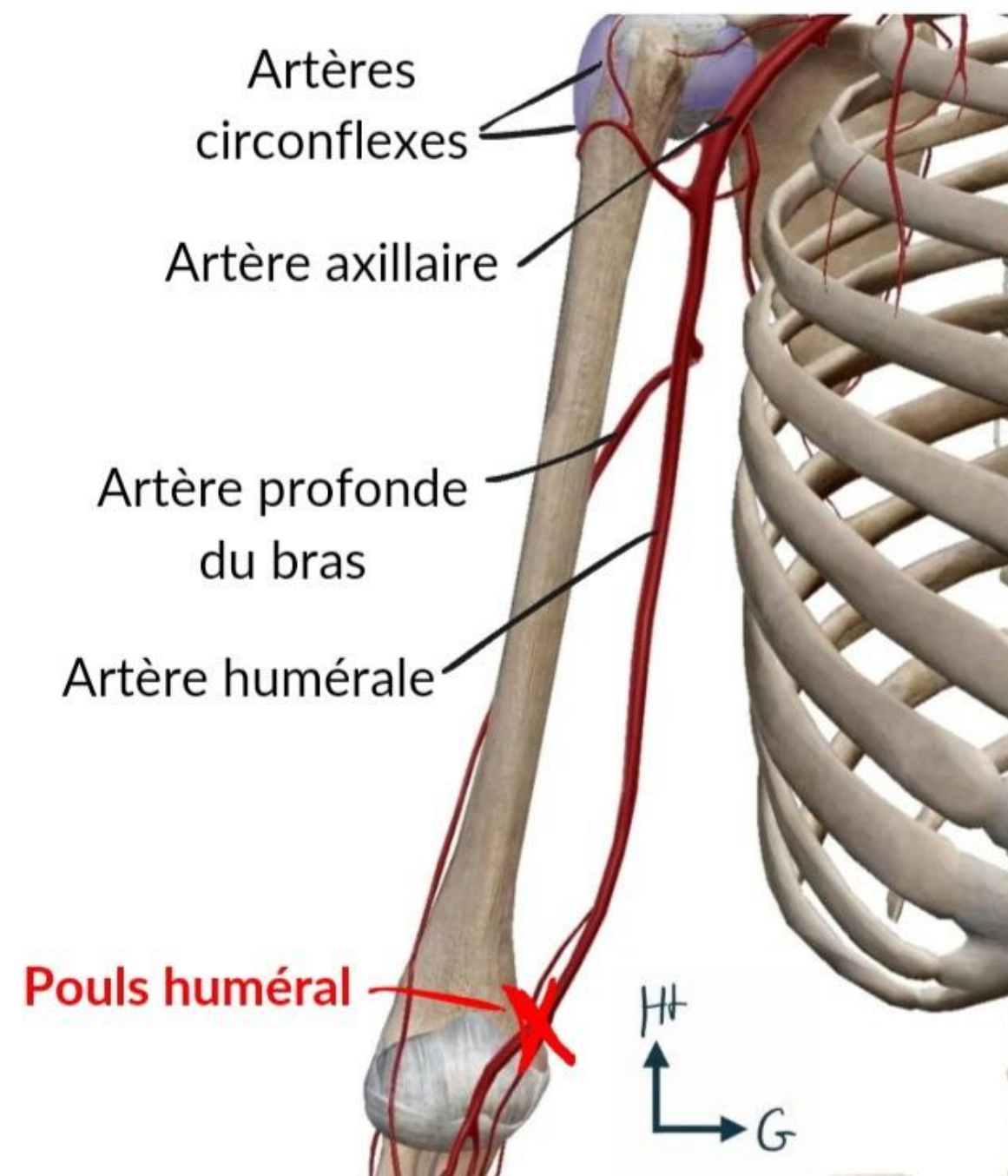
Vue antérieure du bras



Vue antérieure de l'avant-bras

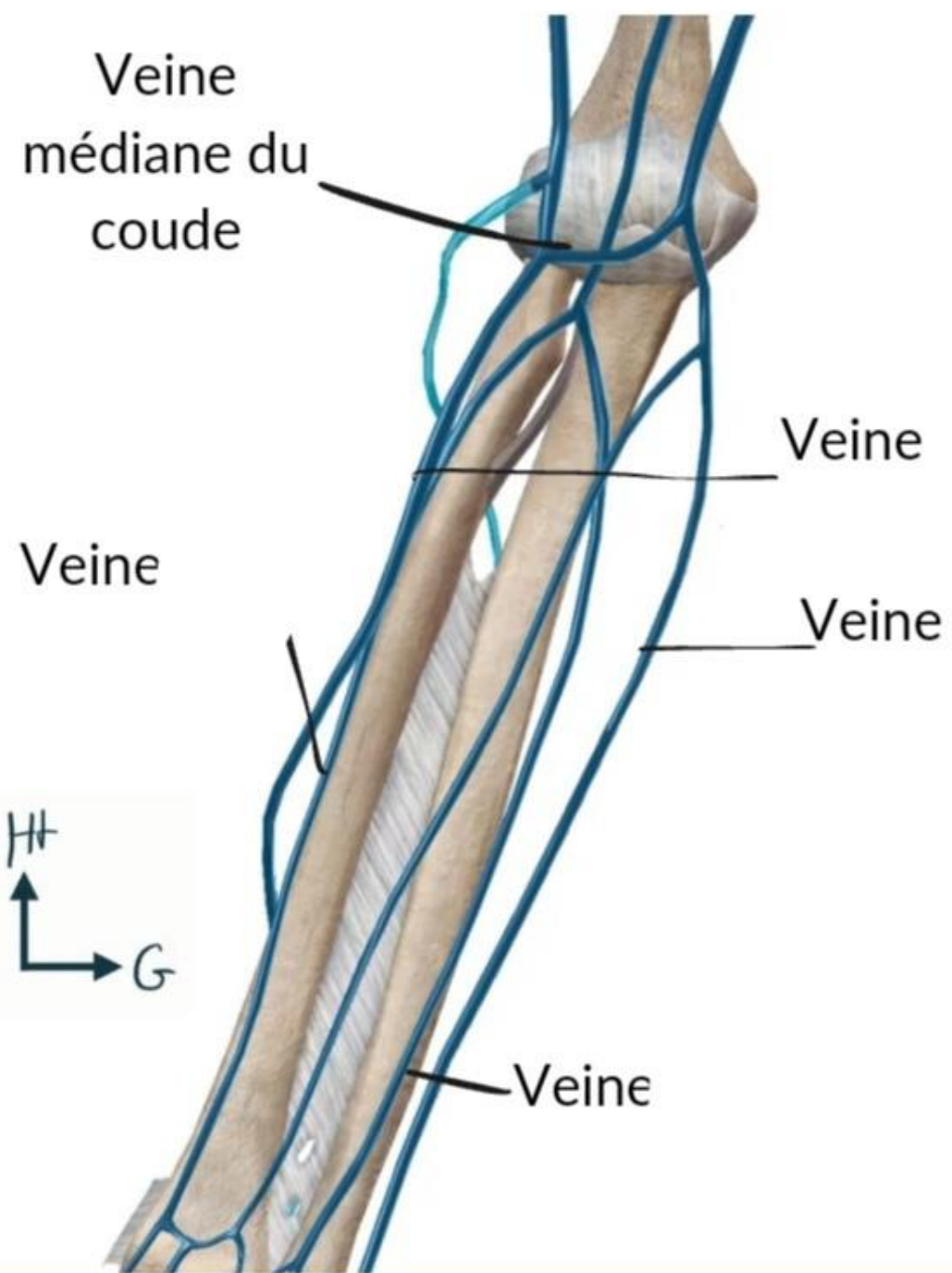


Vue antérieure du bras

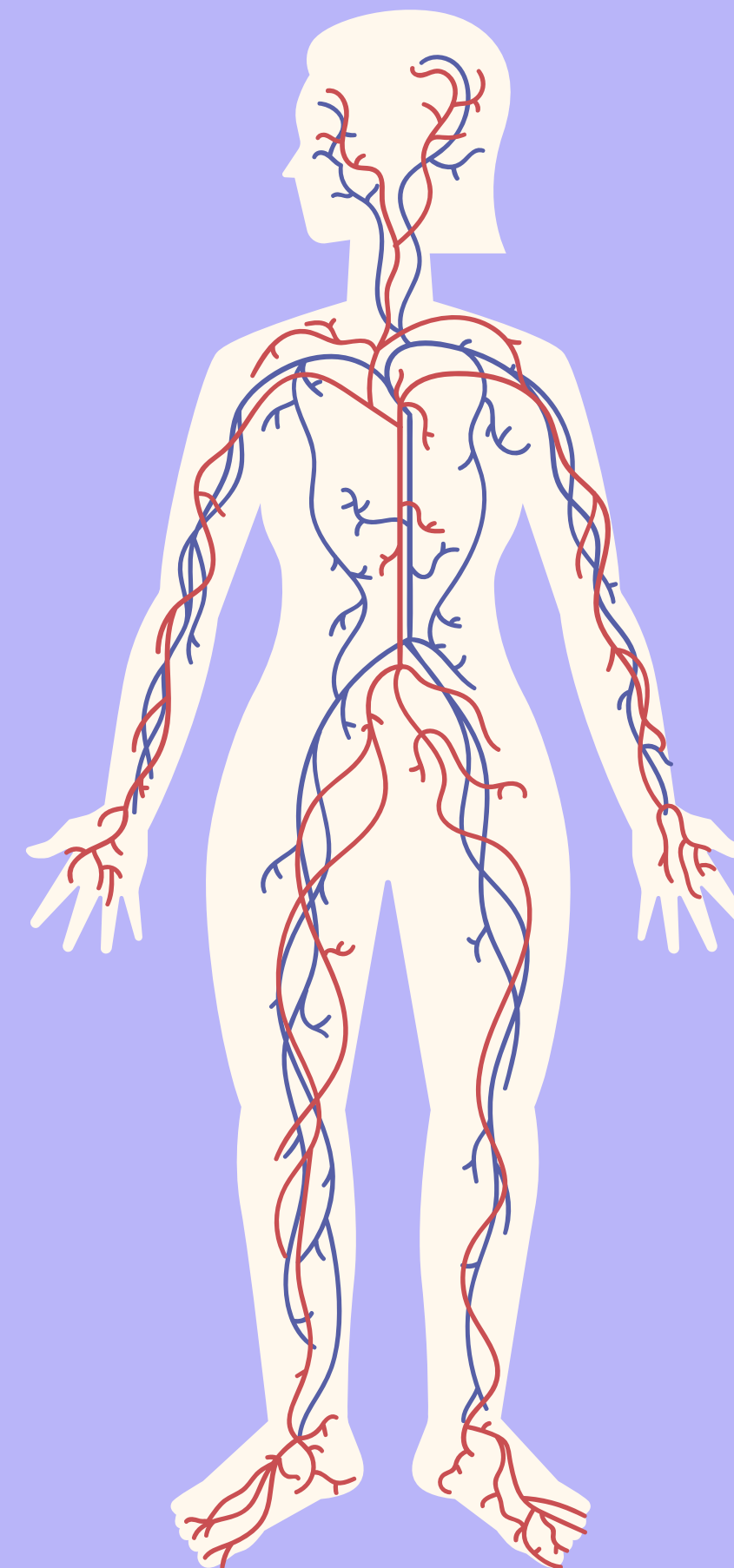
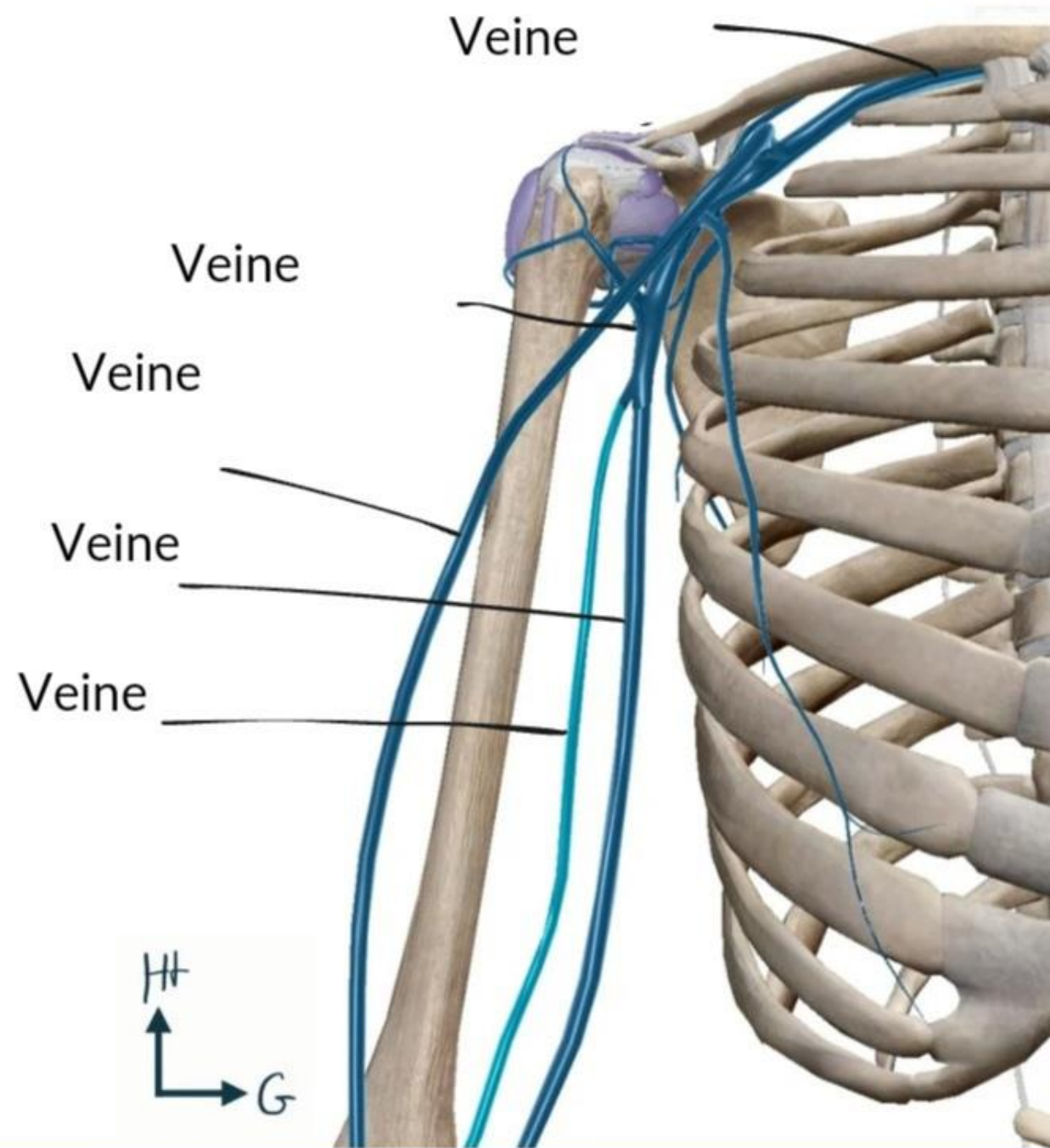


BIRC

Vue antérieure de l'avant-bras

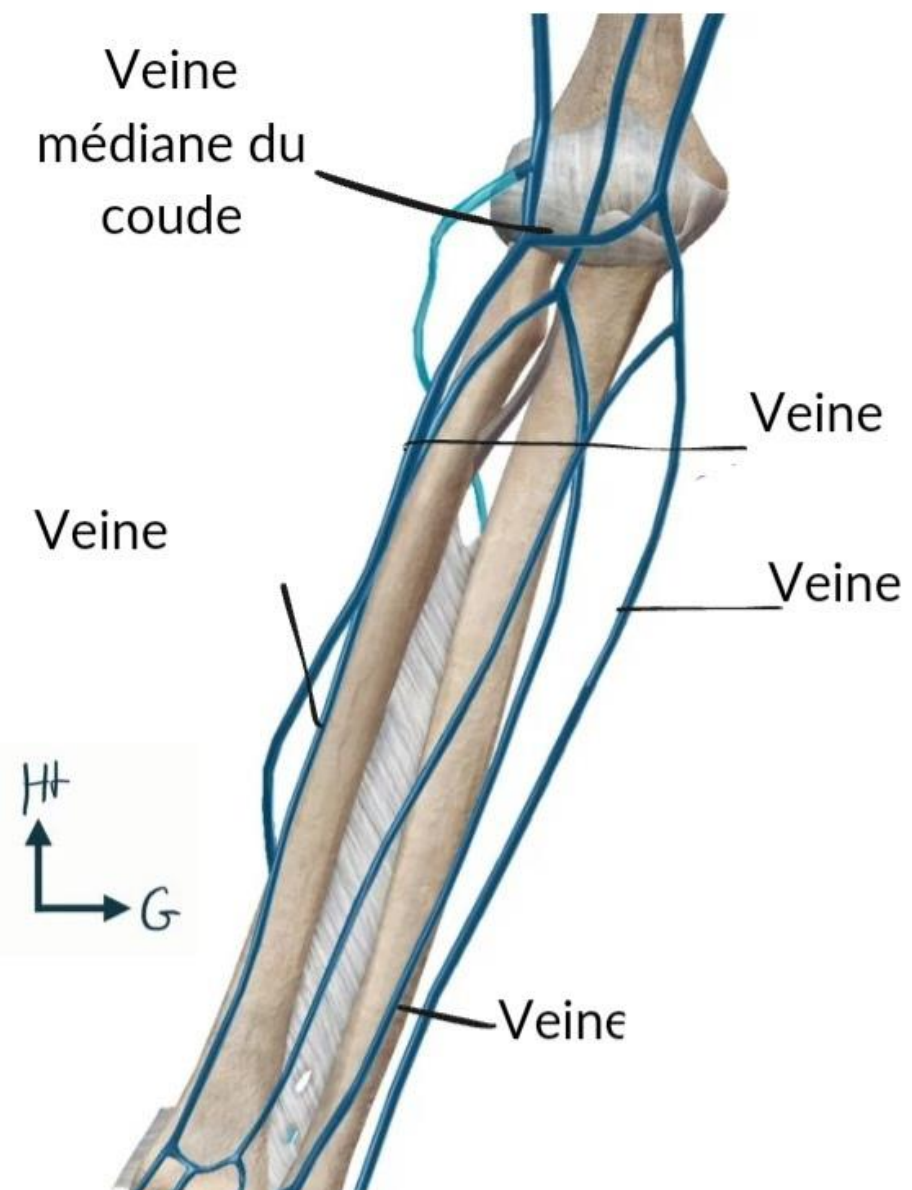


Vue antérieure du bras

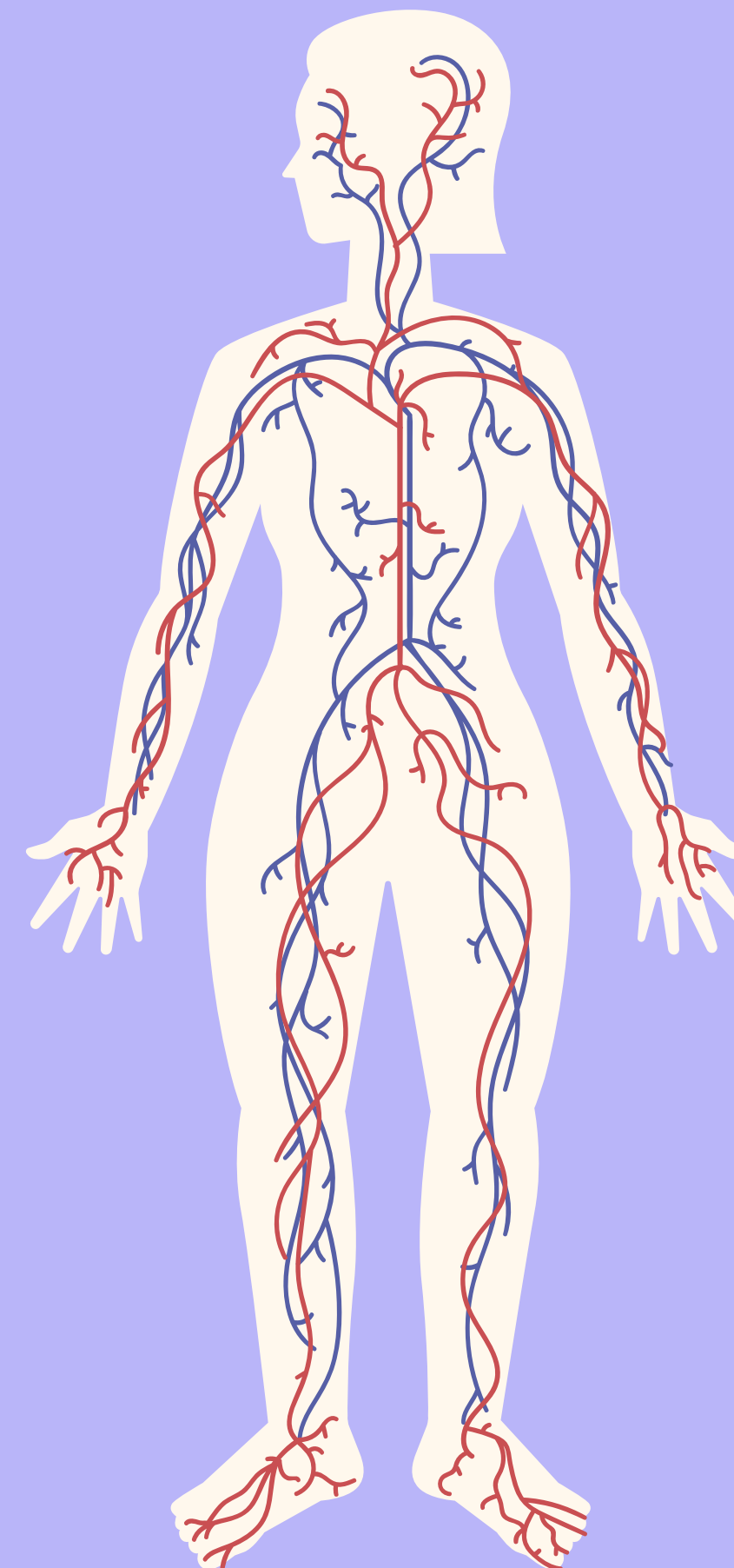
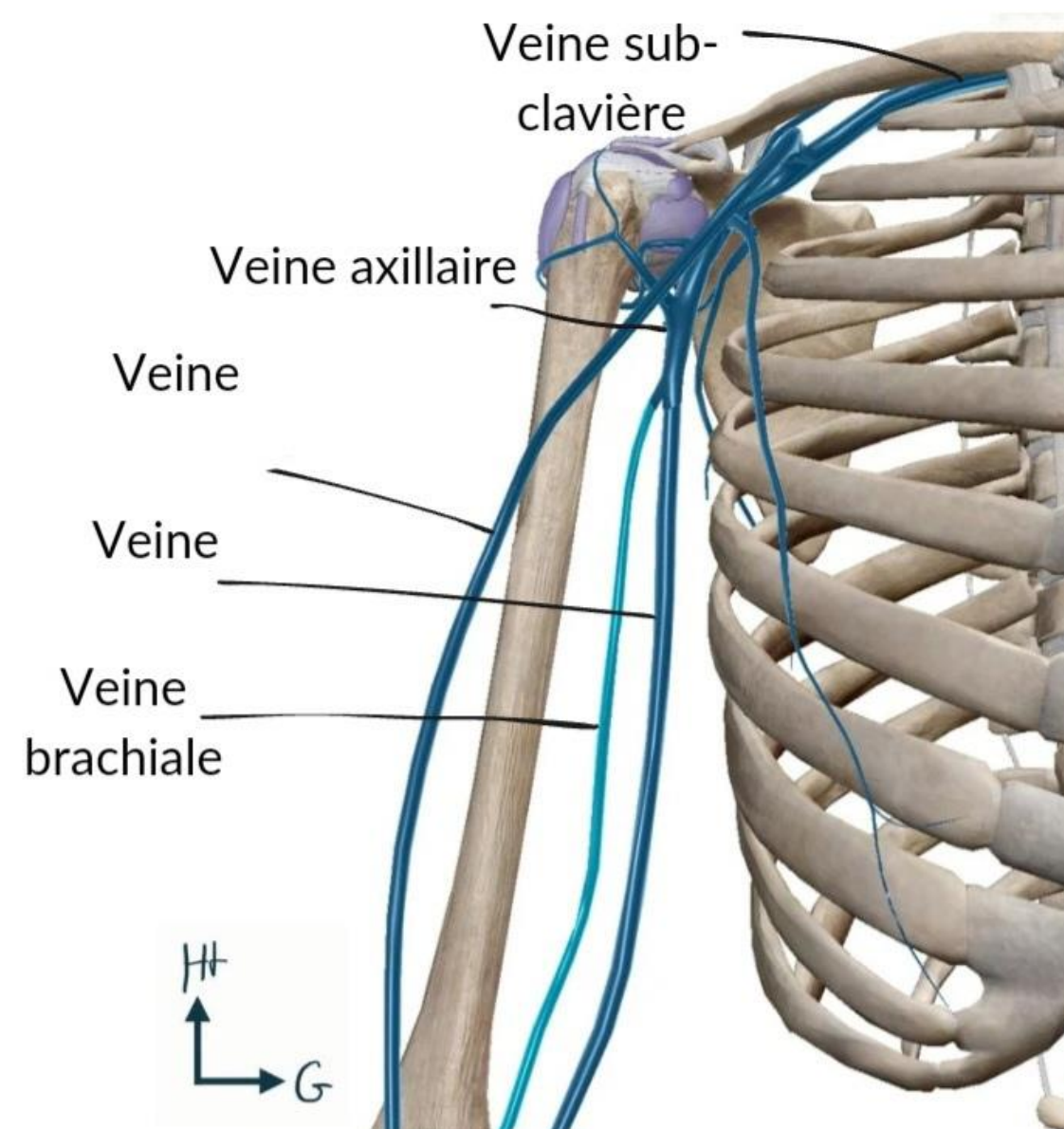


BIRC

Vue antérieure de l'avant-bras

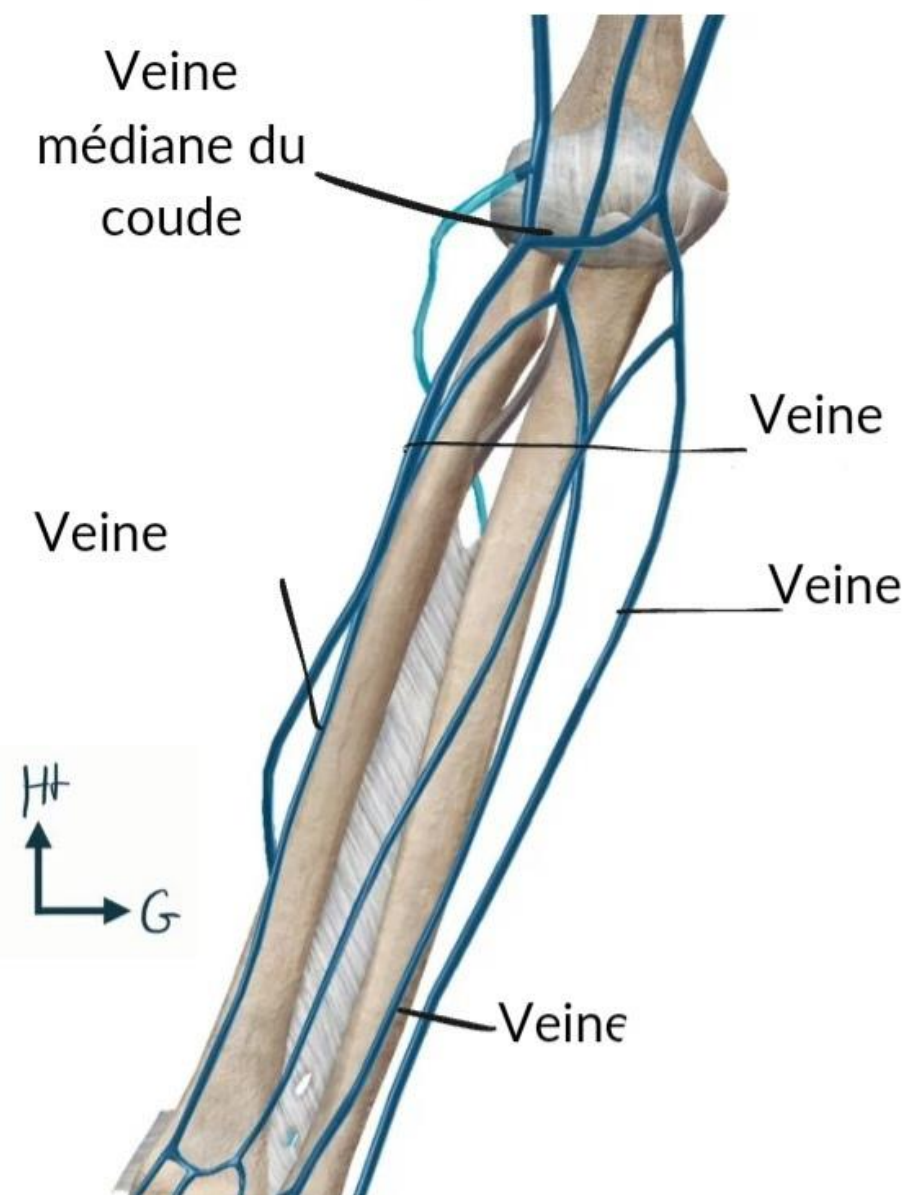


Vue antérieure du bras

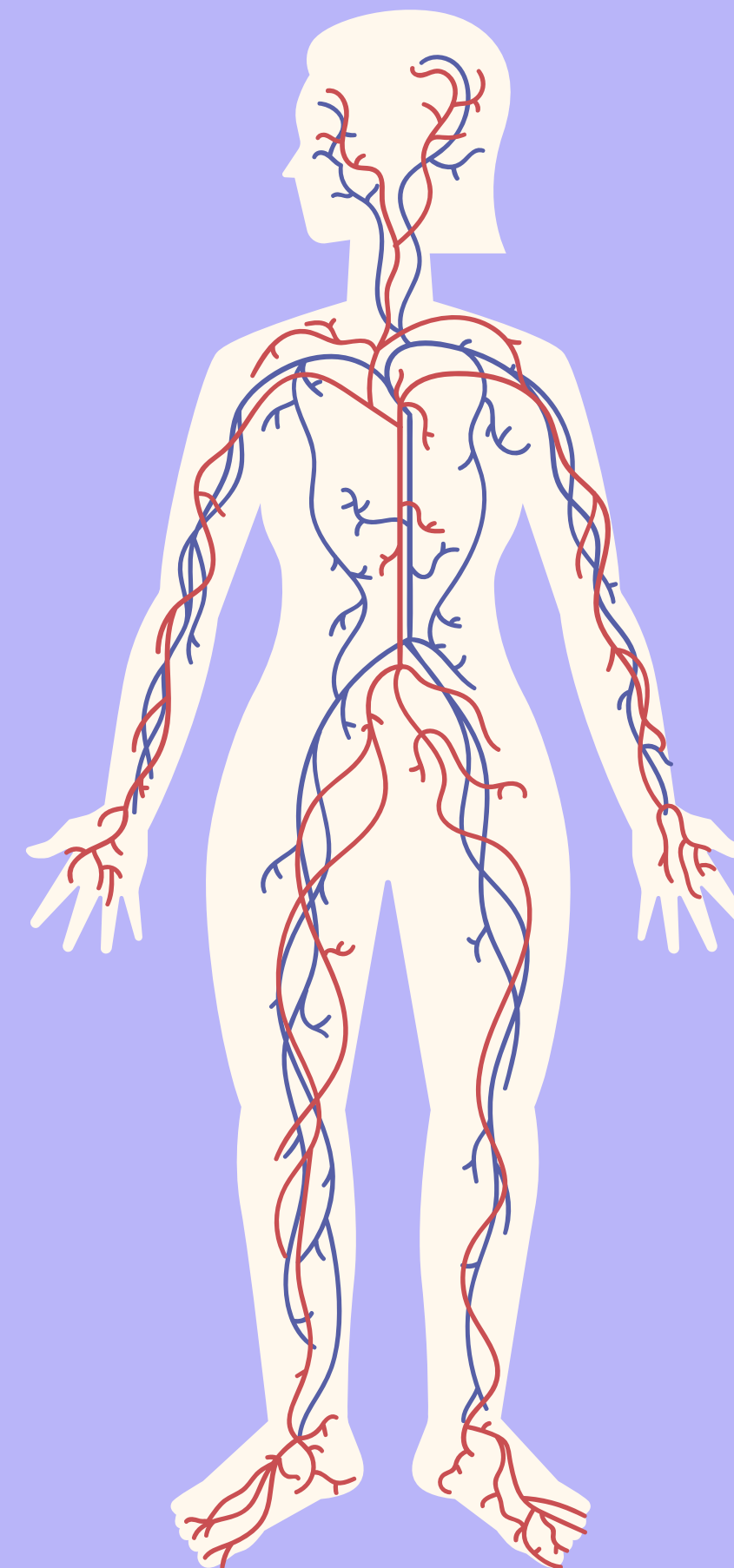
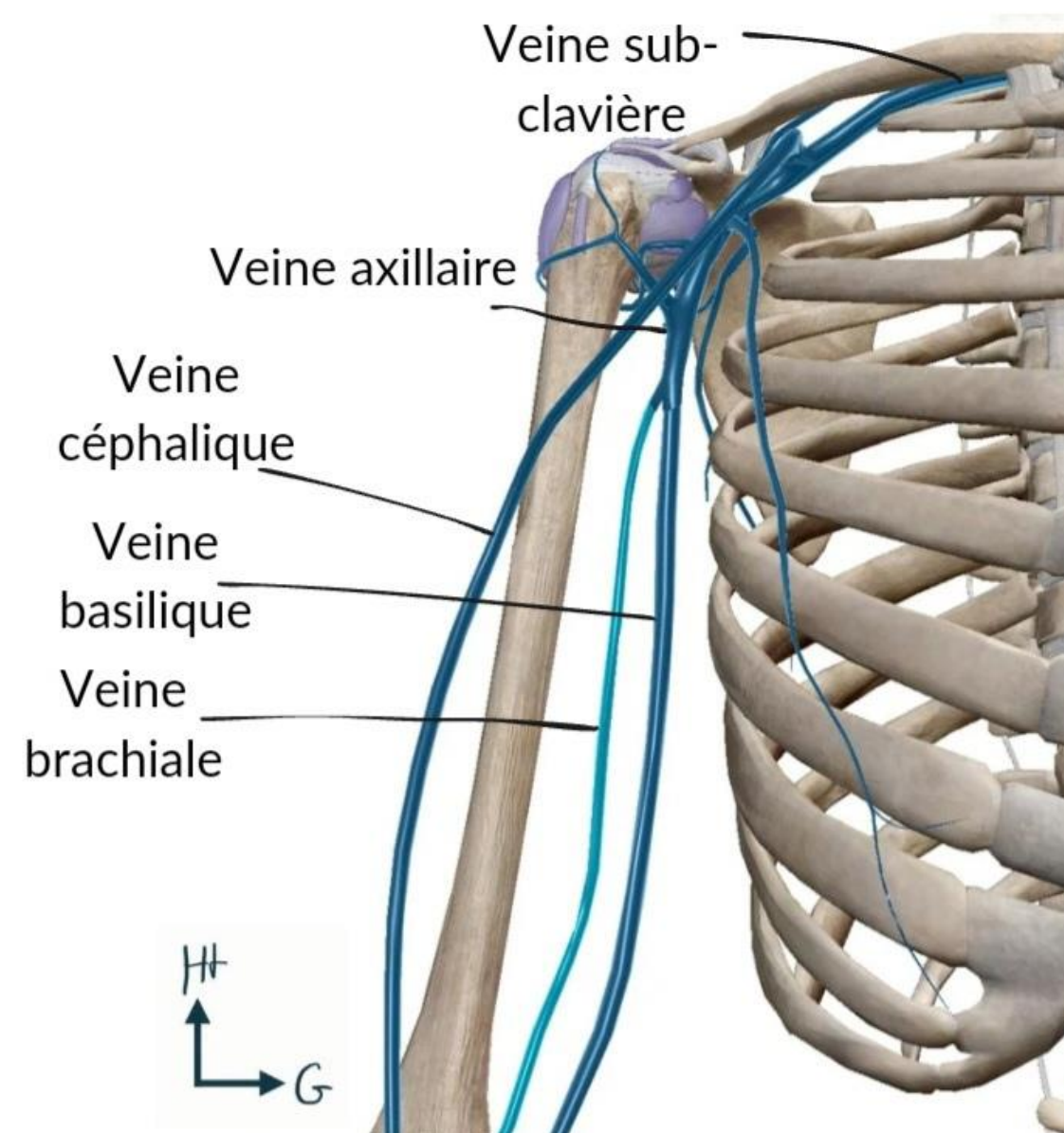


BIRC

Vue antérieure de l'avant-bras

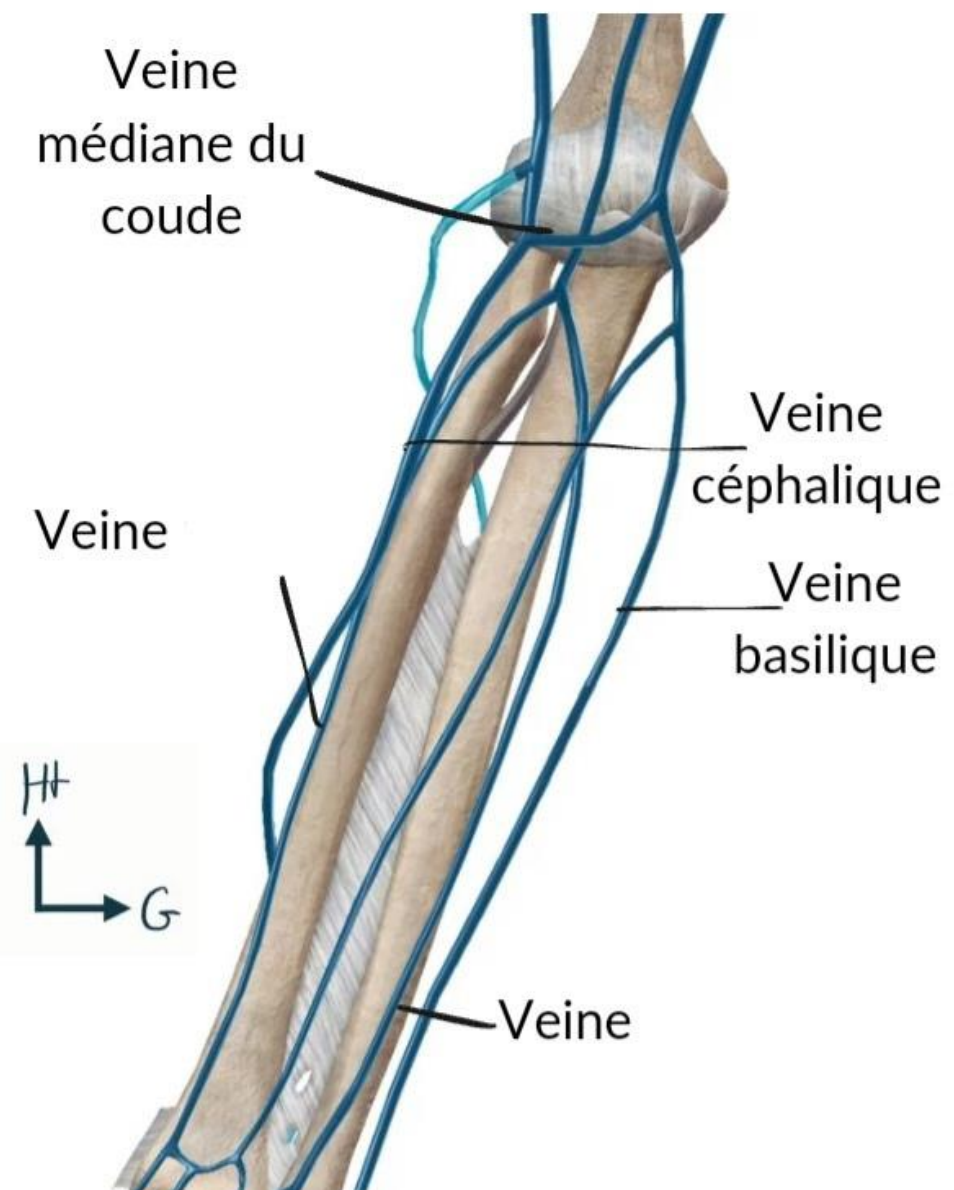


Vue antérieure du bras

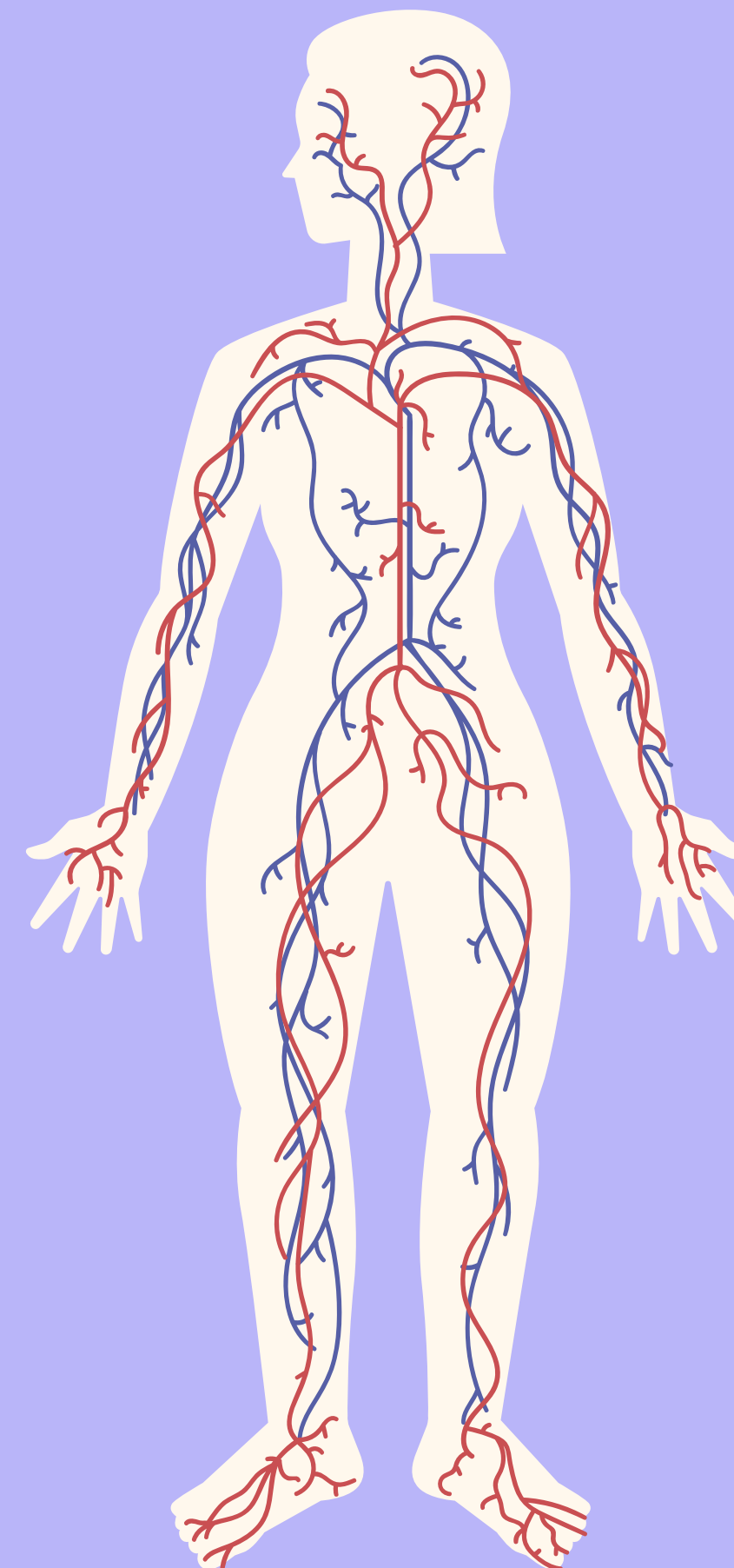
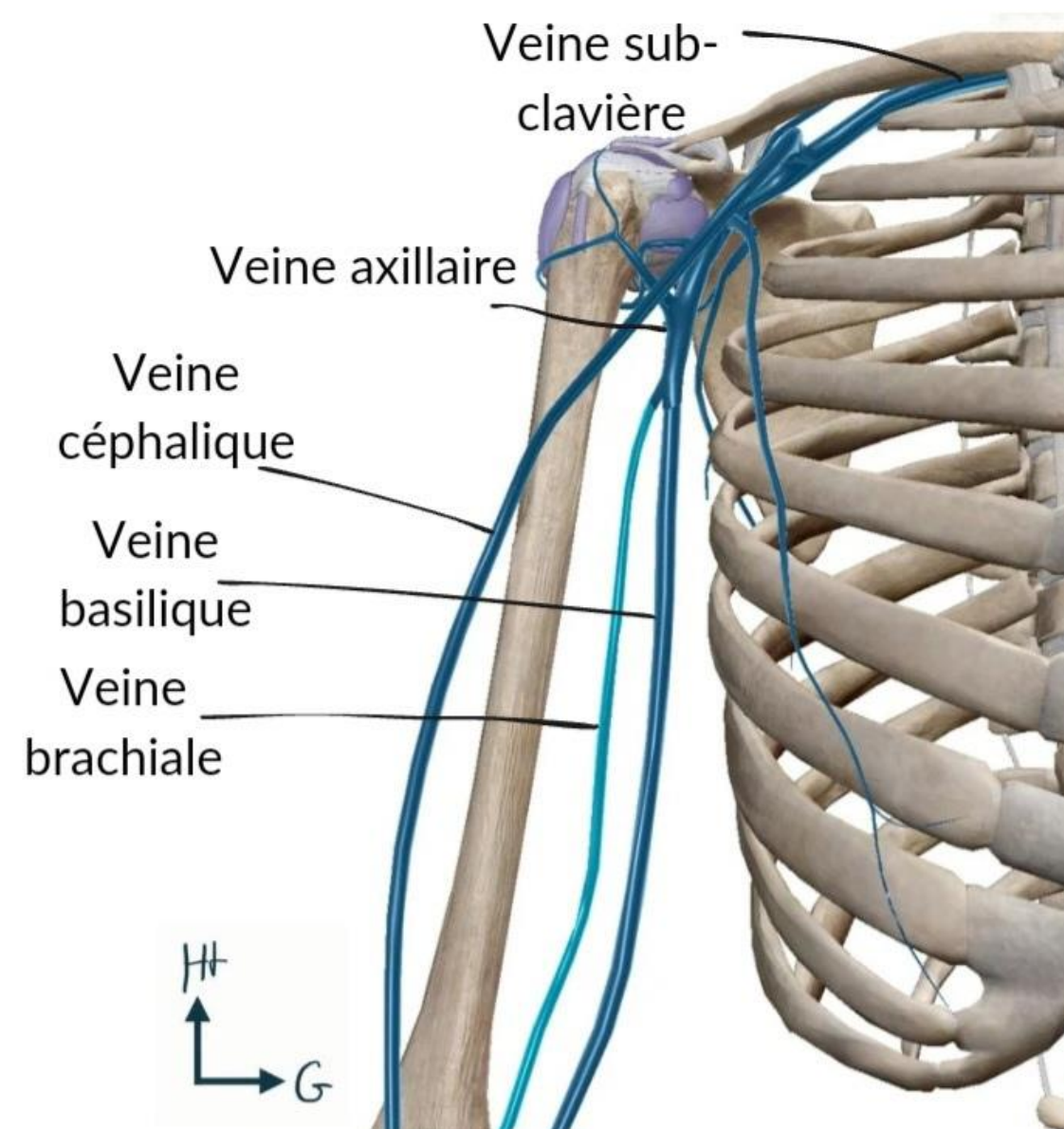


BIRC

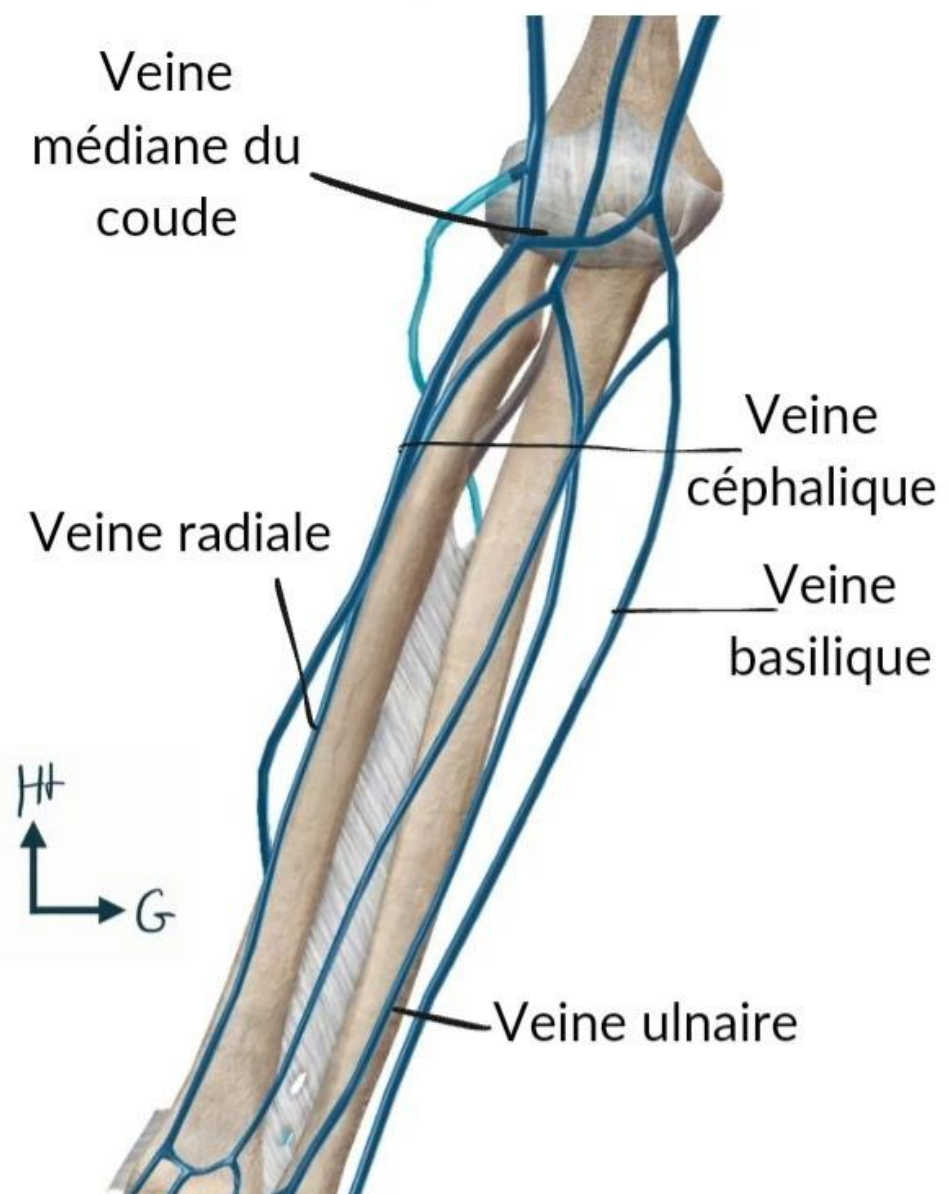
Vue antérieure de l'avant-bras



Vue antérieure du bras



Vue antérieure de l'avant-bras



Vue antérieure du bras

