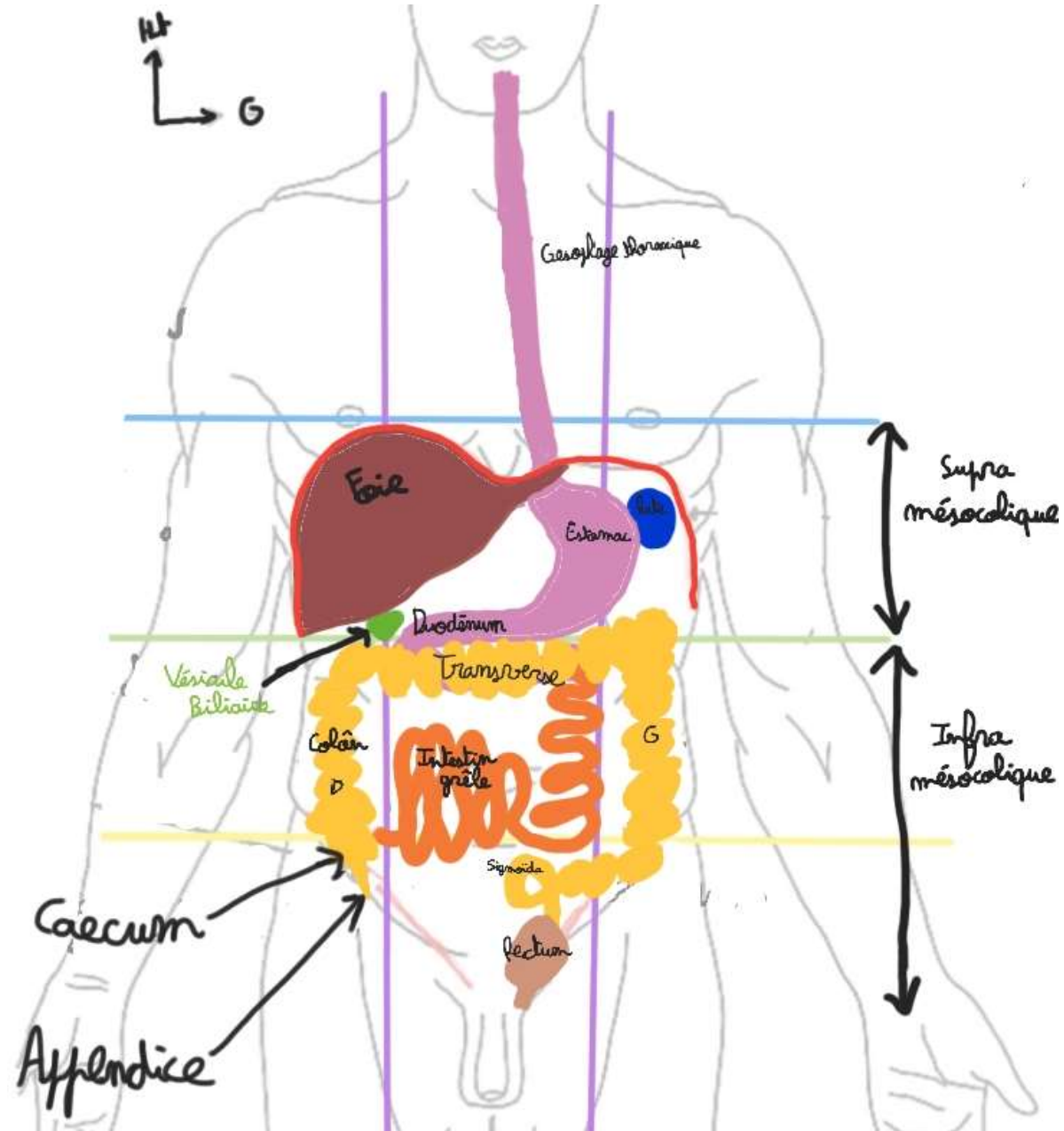


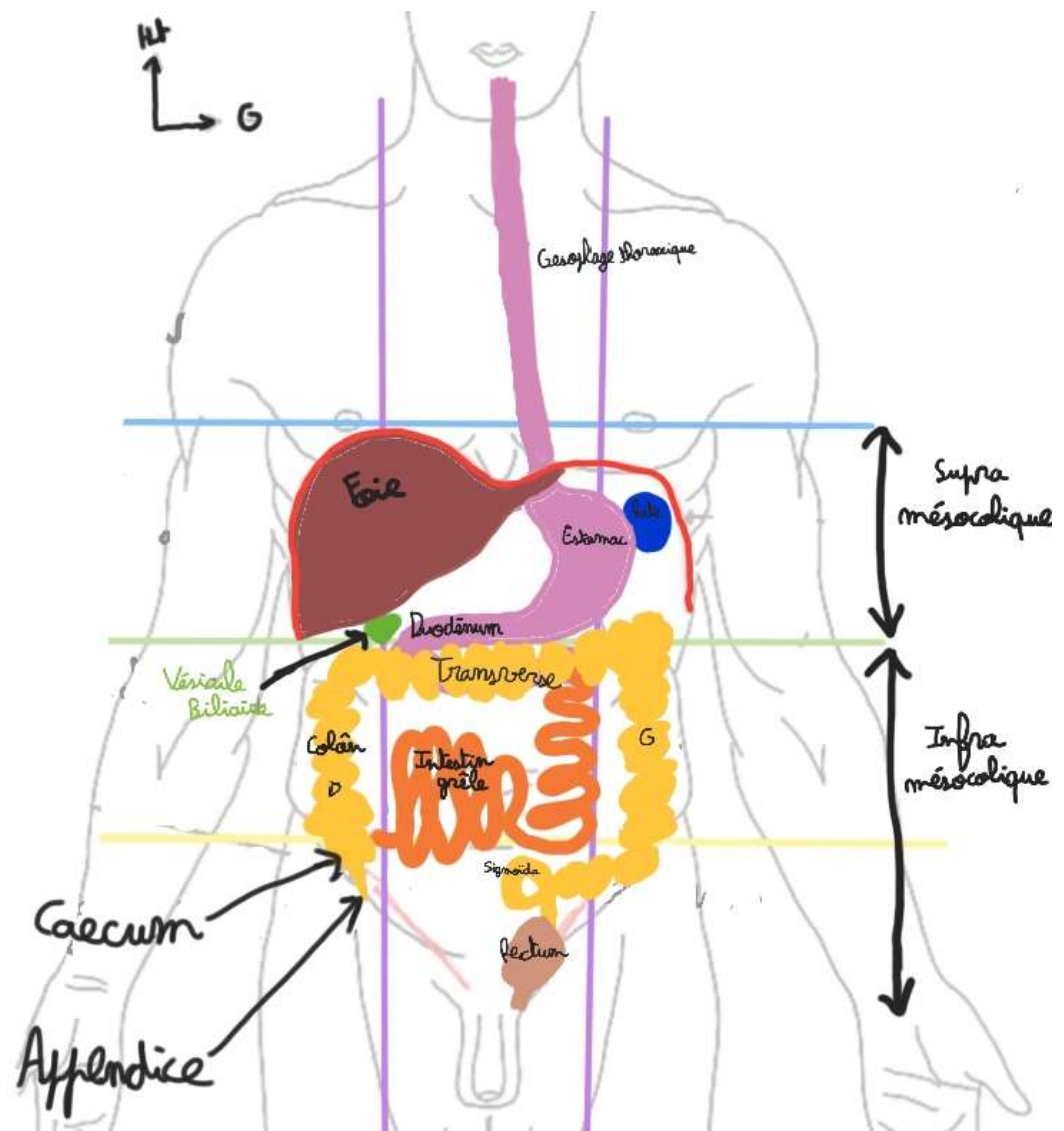
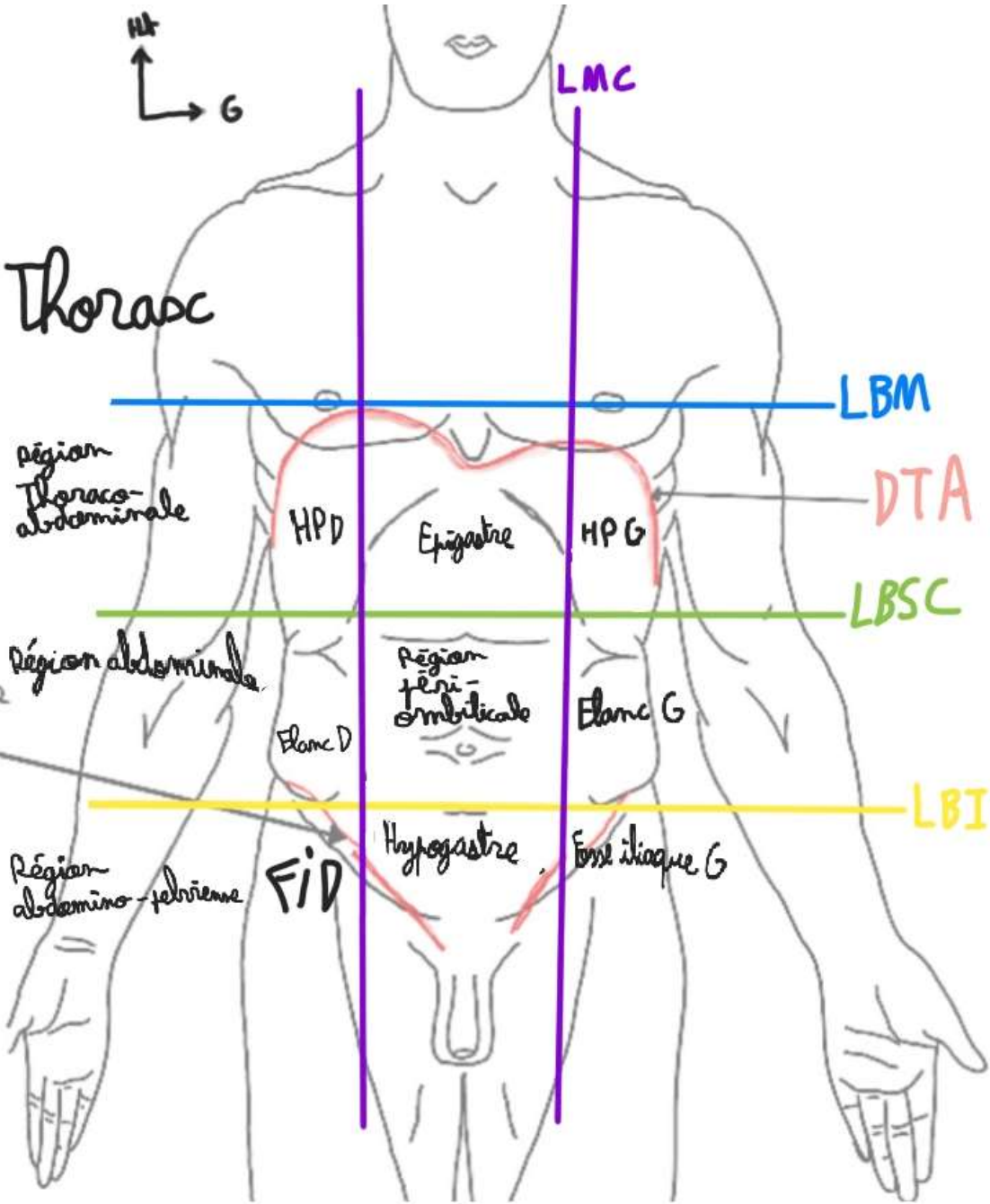


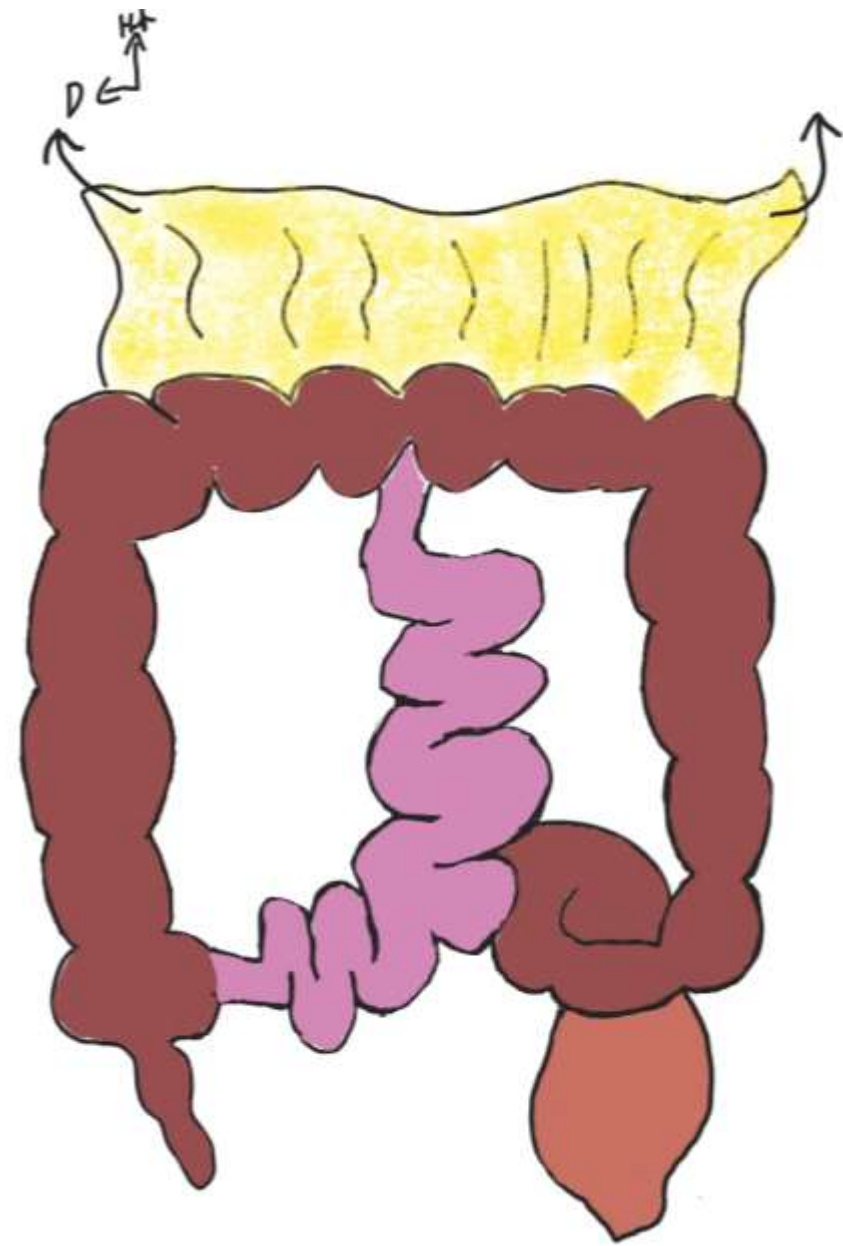
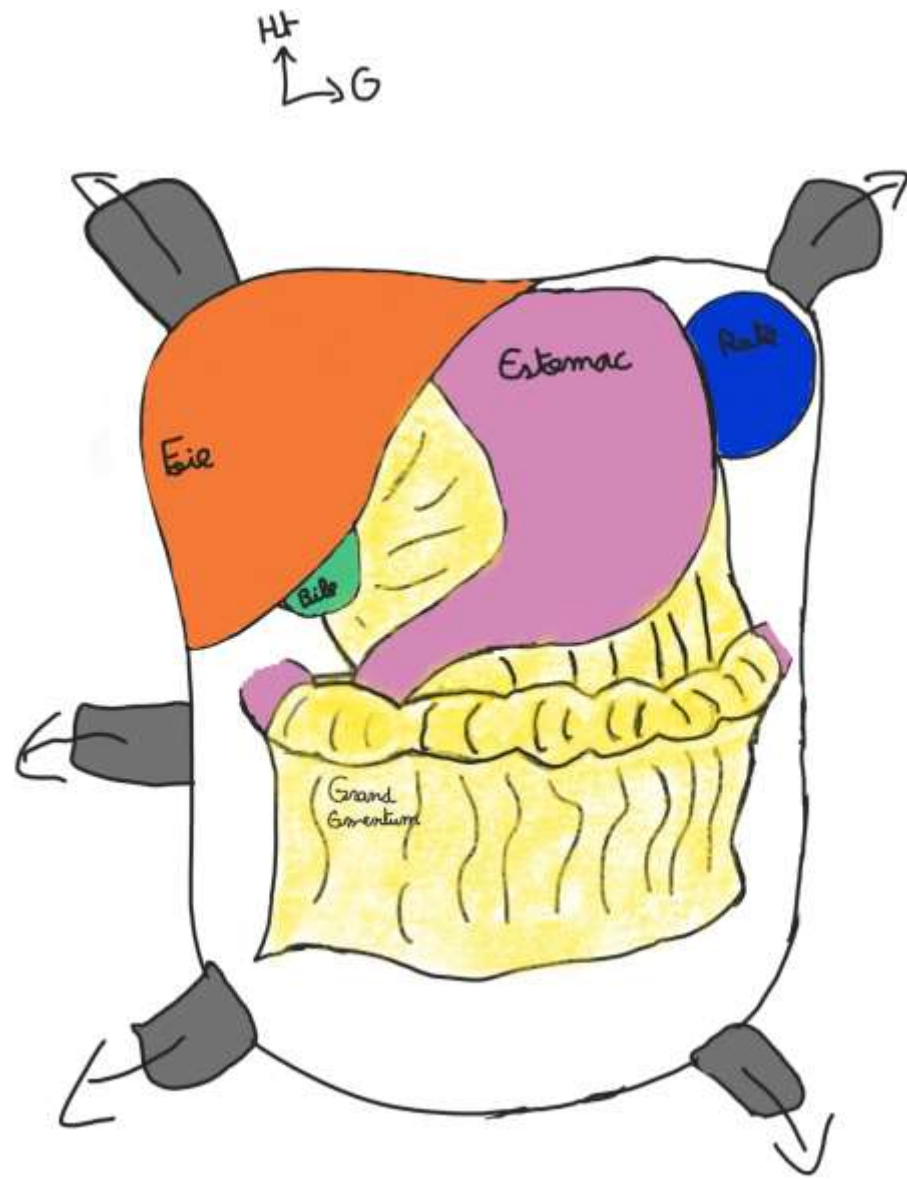
# Appareil Digestif

1<sup>ère</sup> Partie

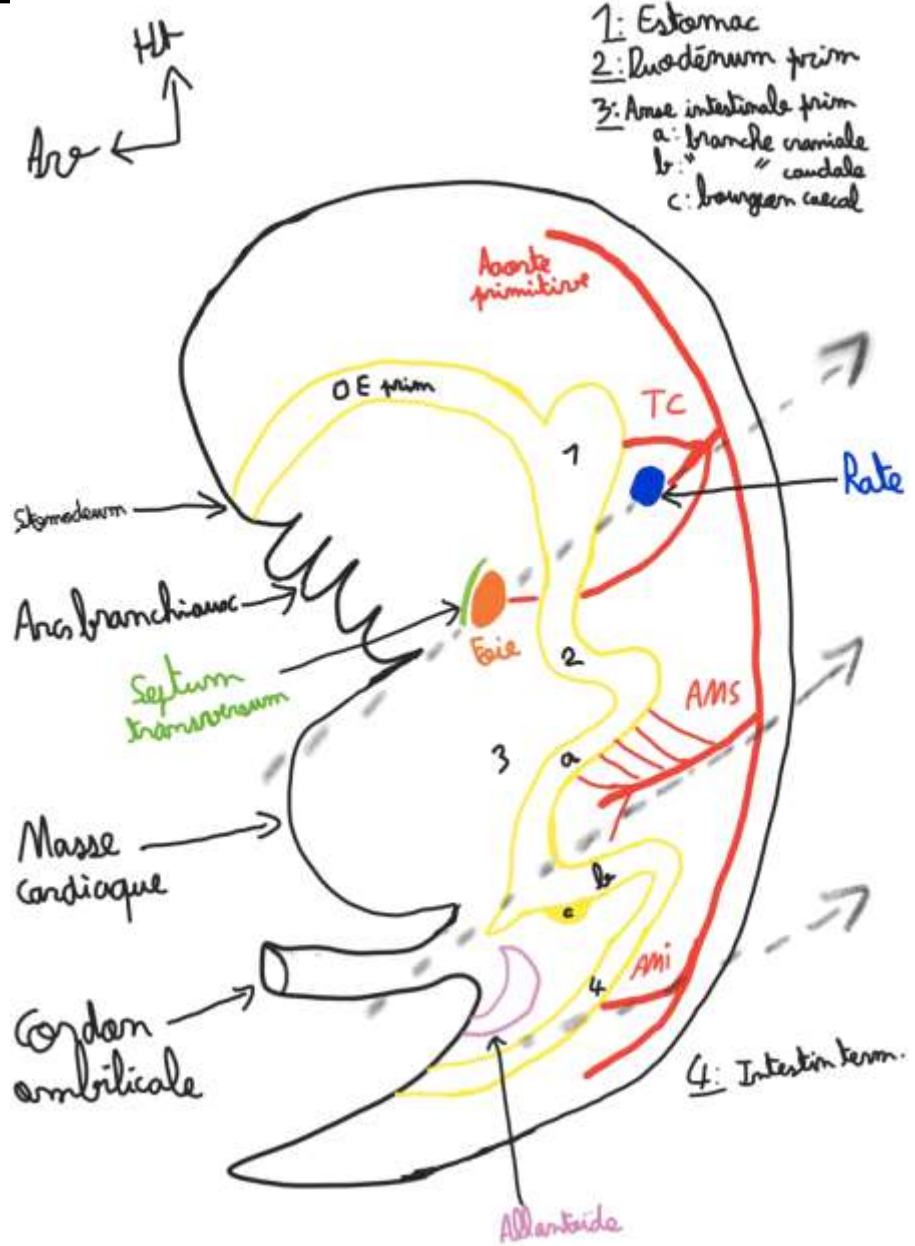
# 1. Topographie generale du Tronc

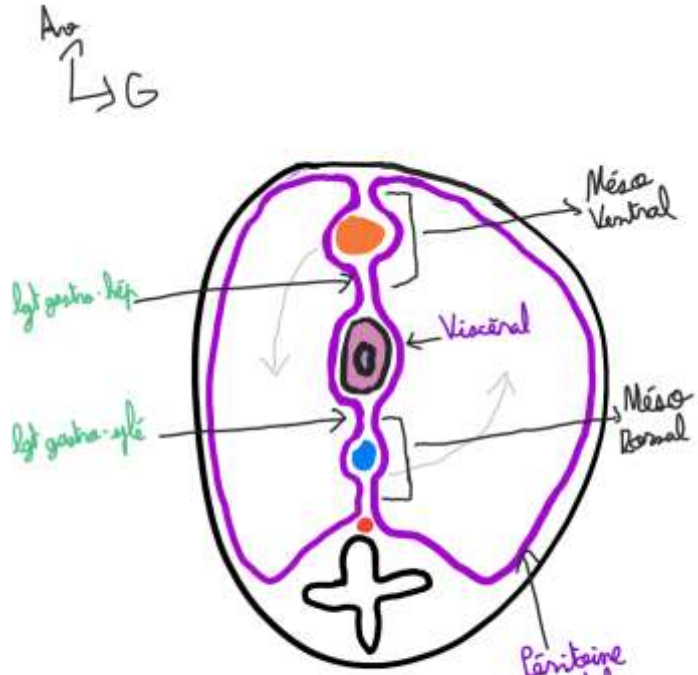






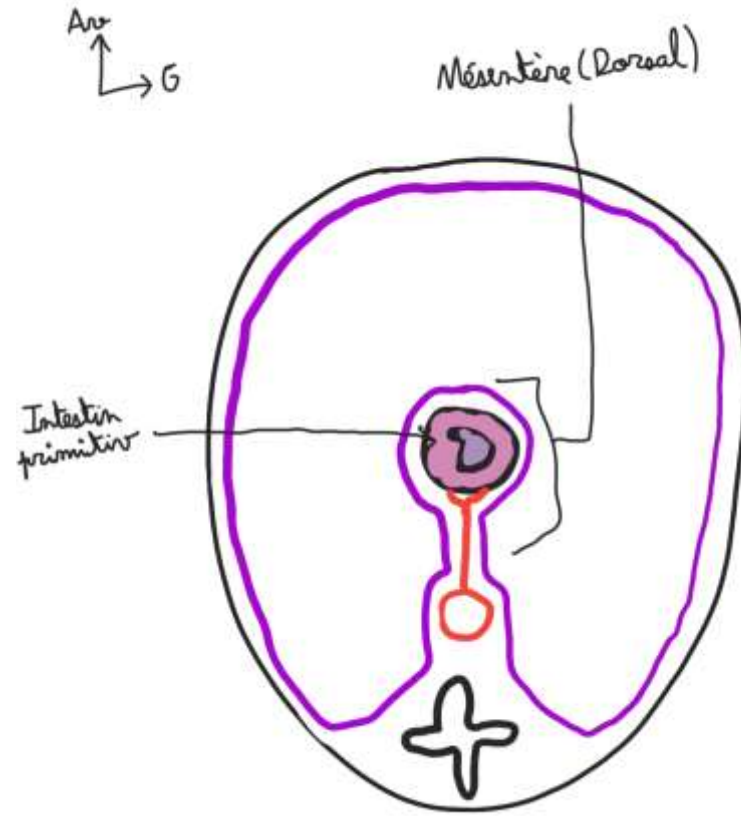
# II. Embryogénèse et Péritoine



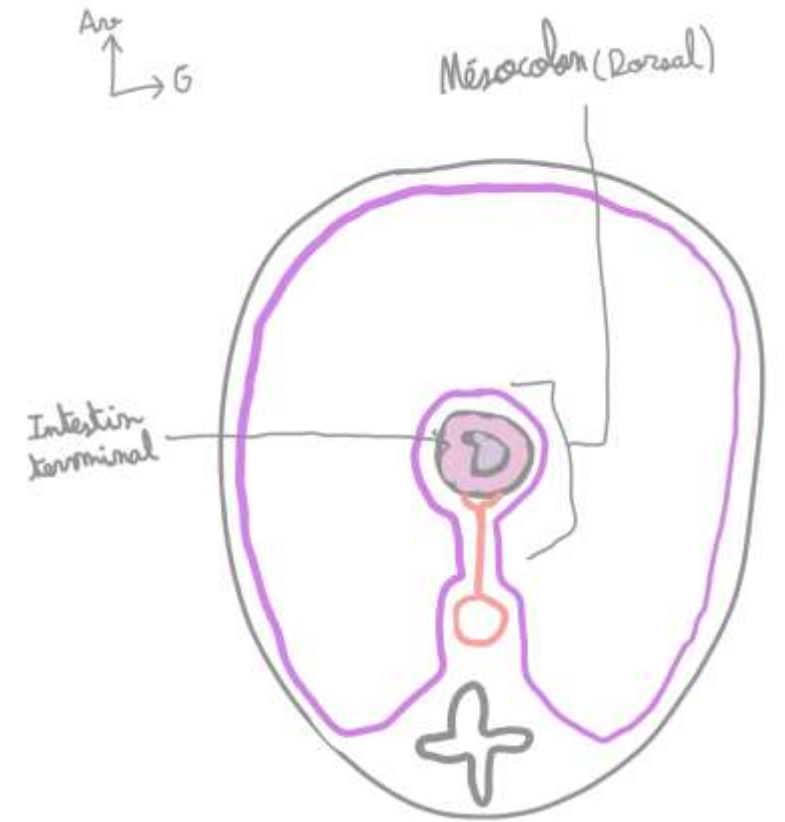


Foie  
Estomac  
Rate

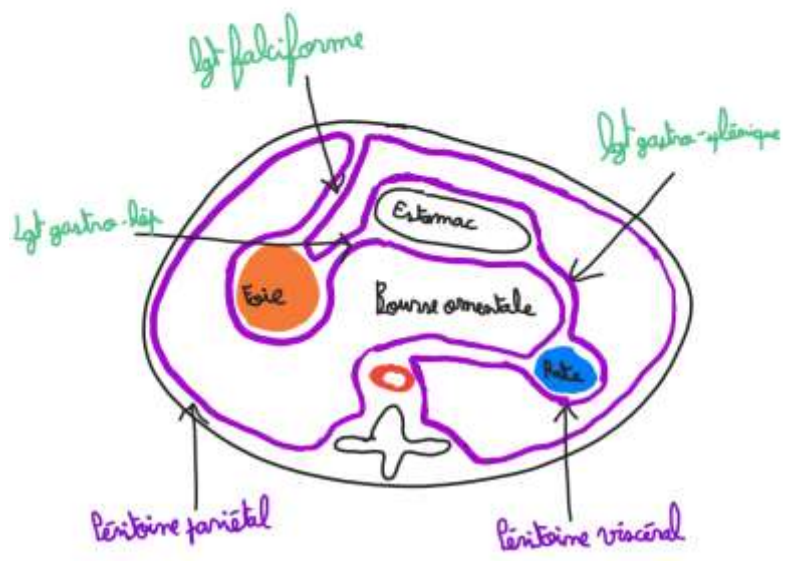
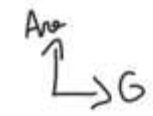
Coupe  
Transversale TC



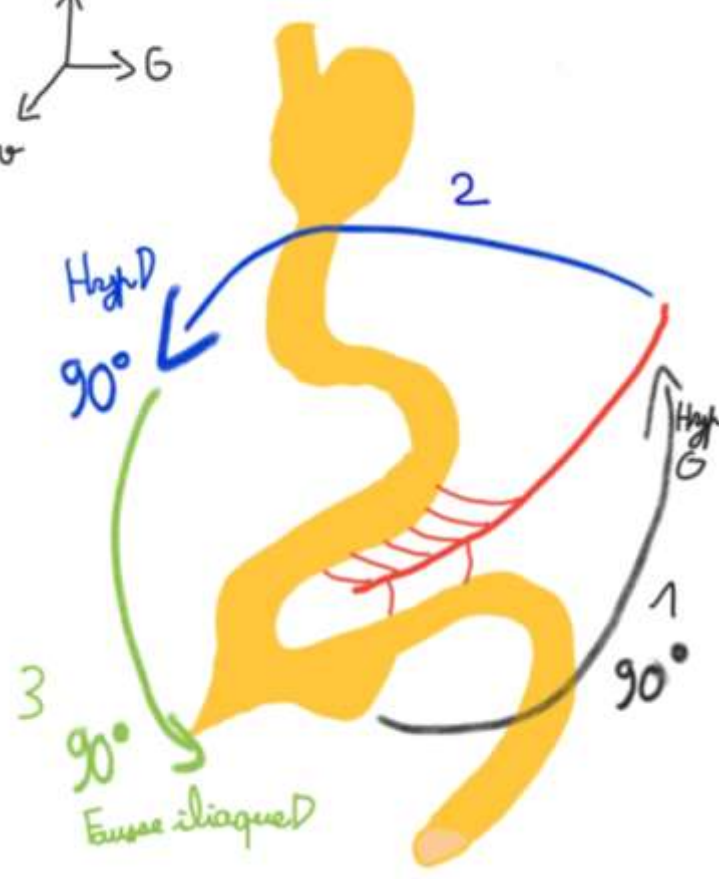
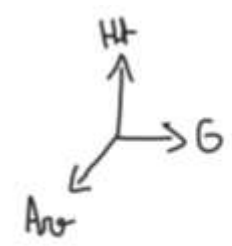
Coupe  
Transversale  
AIP



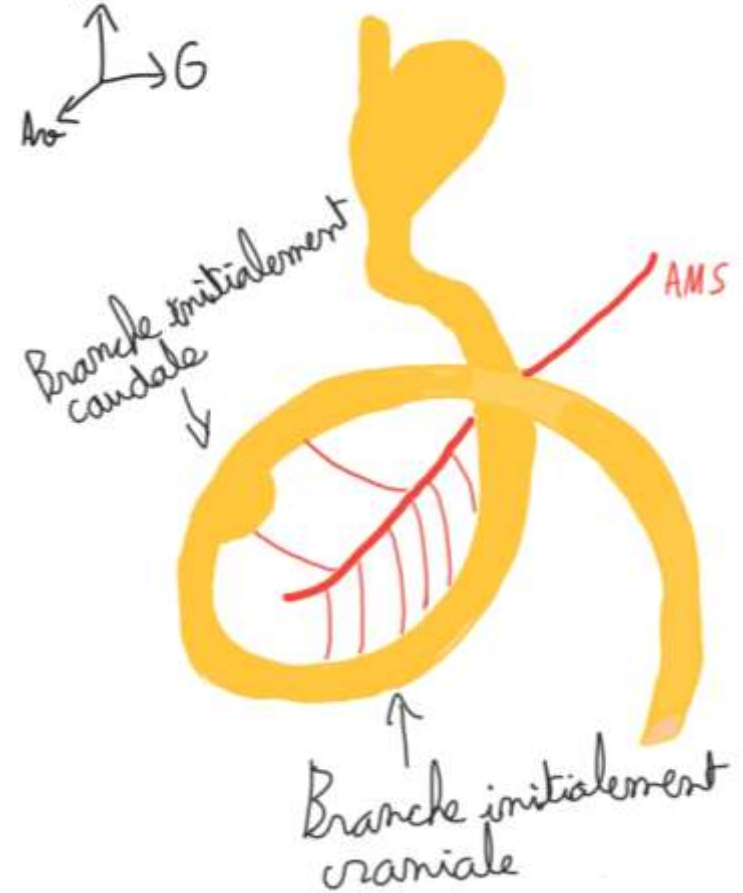
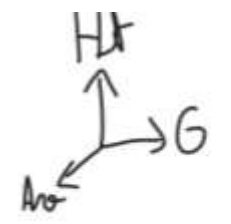
Coupe  
Transversale IT



Coupe Transversale  
du TC après  
rotations

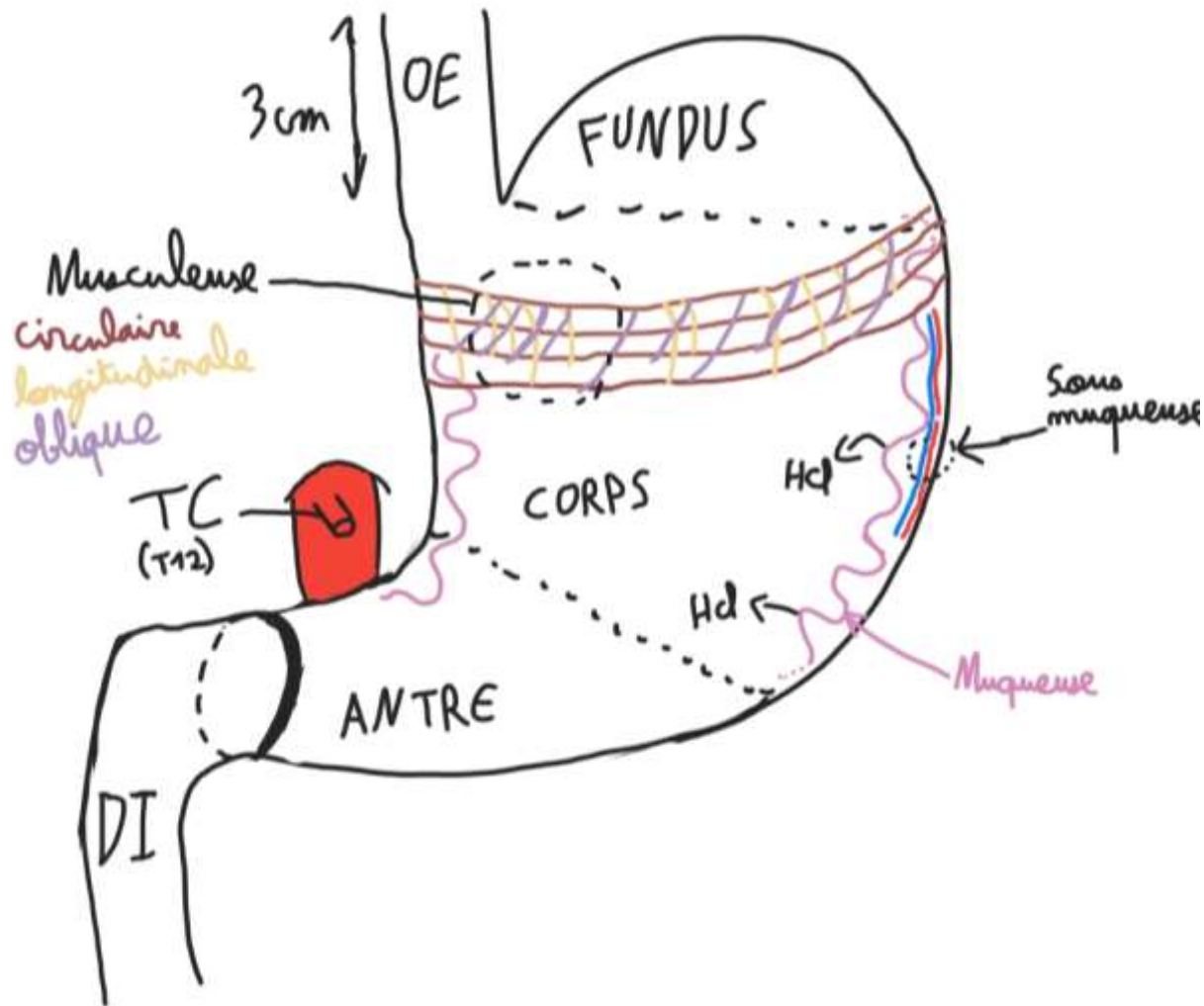
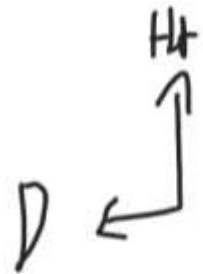

Vue de  $\frac{3}{4}$   
initiale de  
l'AIP



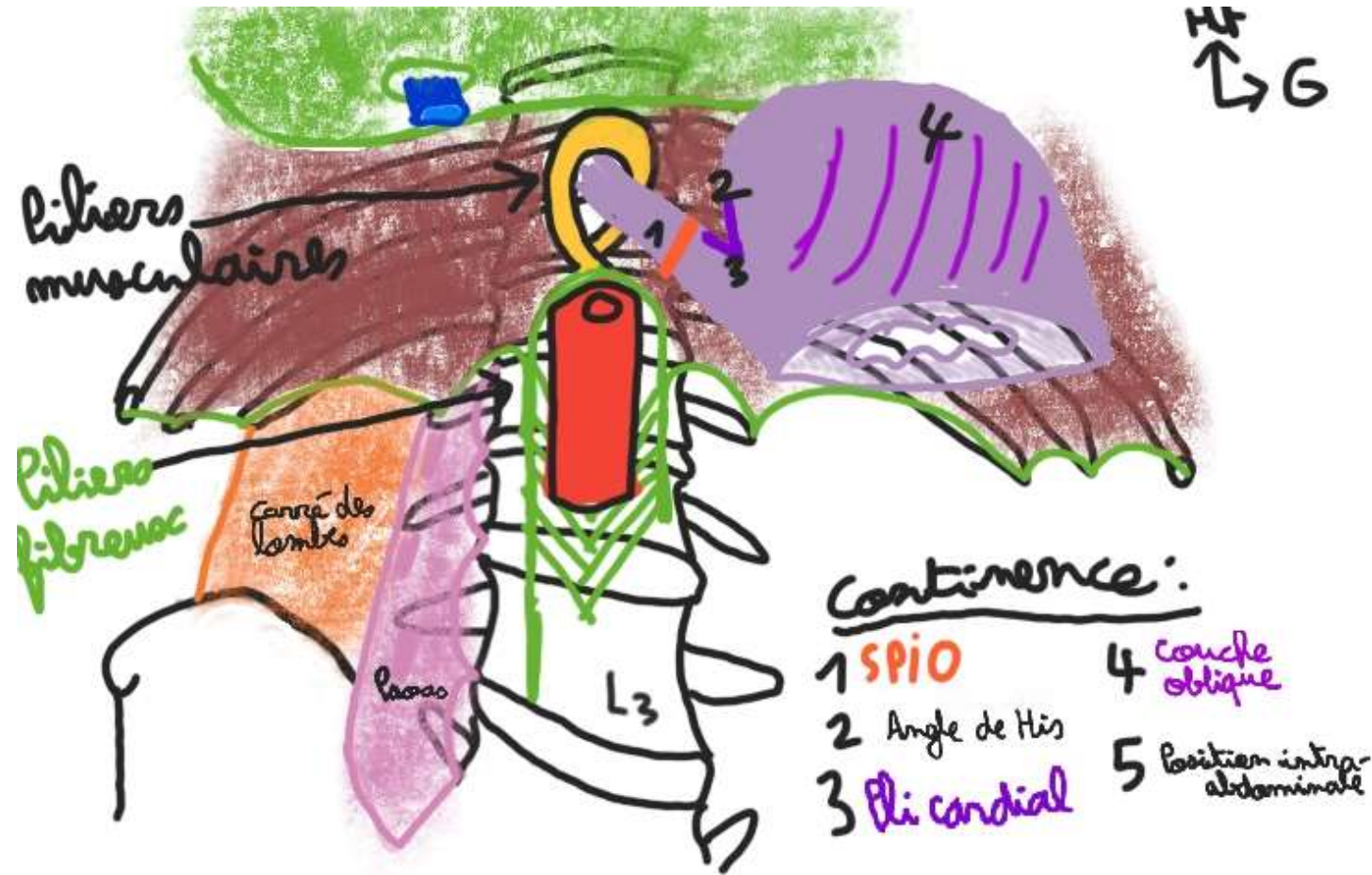
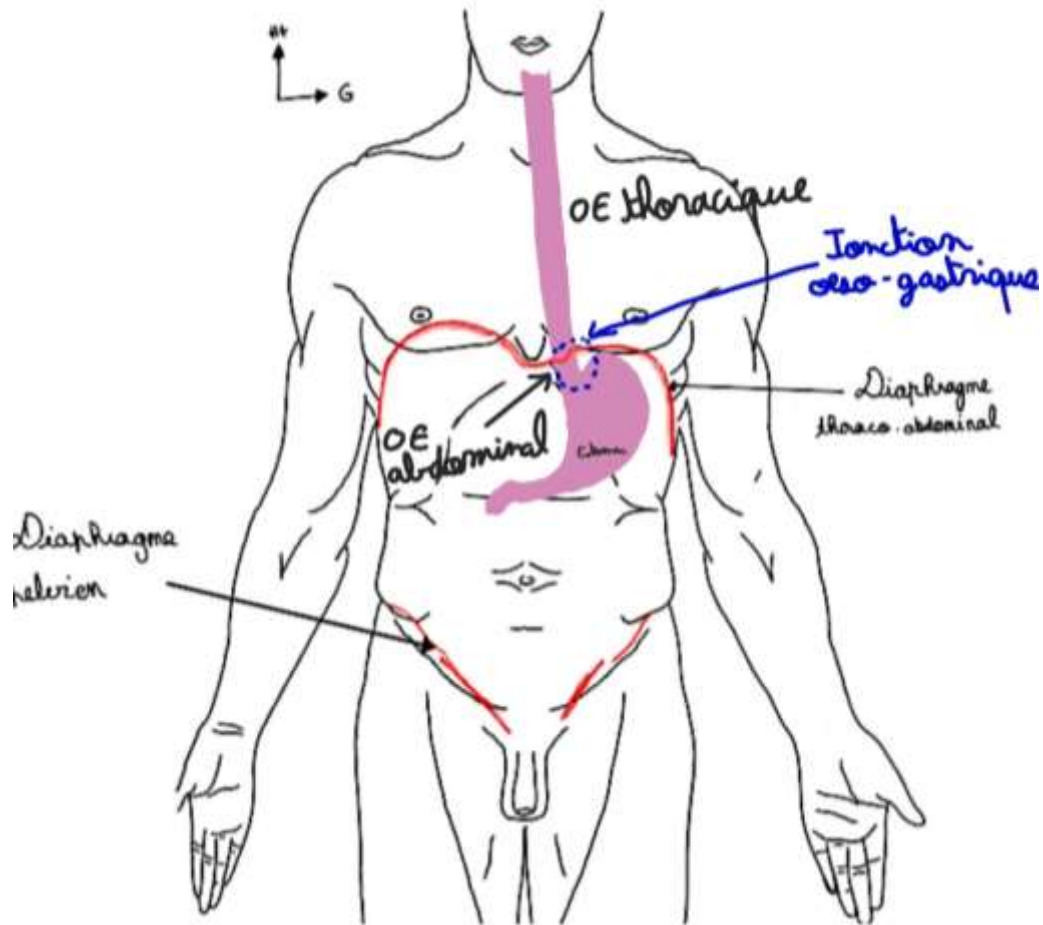
Vue de  $\frac{3}{4}$   
après 2  
rotations

# III. Estomac



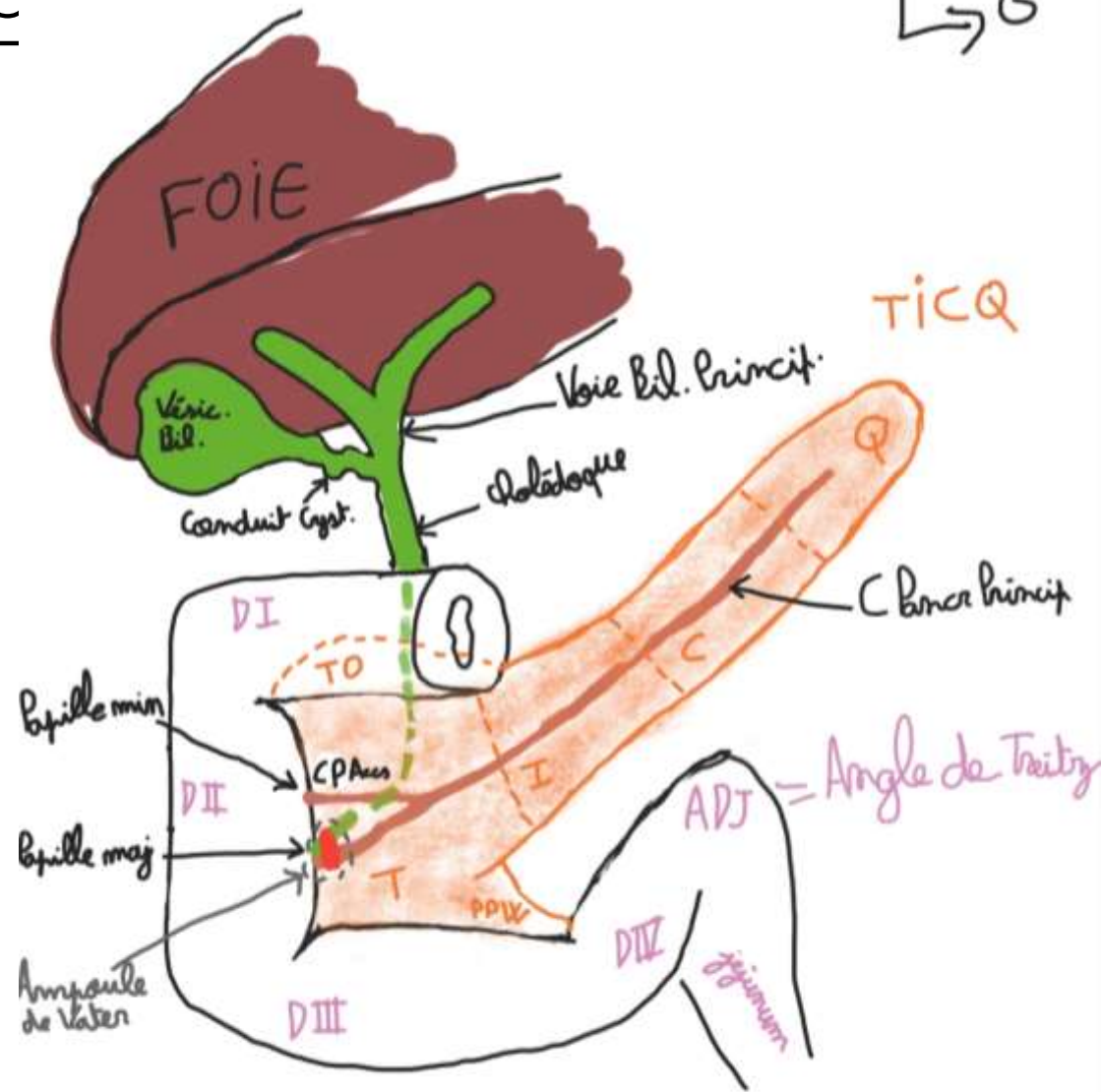


# IV. DTA et Jonction oesogastrique



# V. Bloc Duodéno-Pancréatique

HV  
↑  
↳ G



●: Sphincter d'Oddi

PPV = crochets pancr  
= processus uncinatus