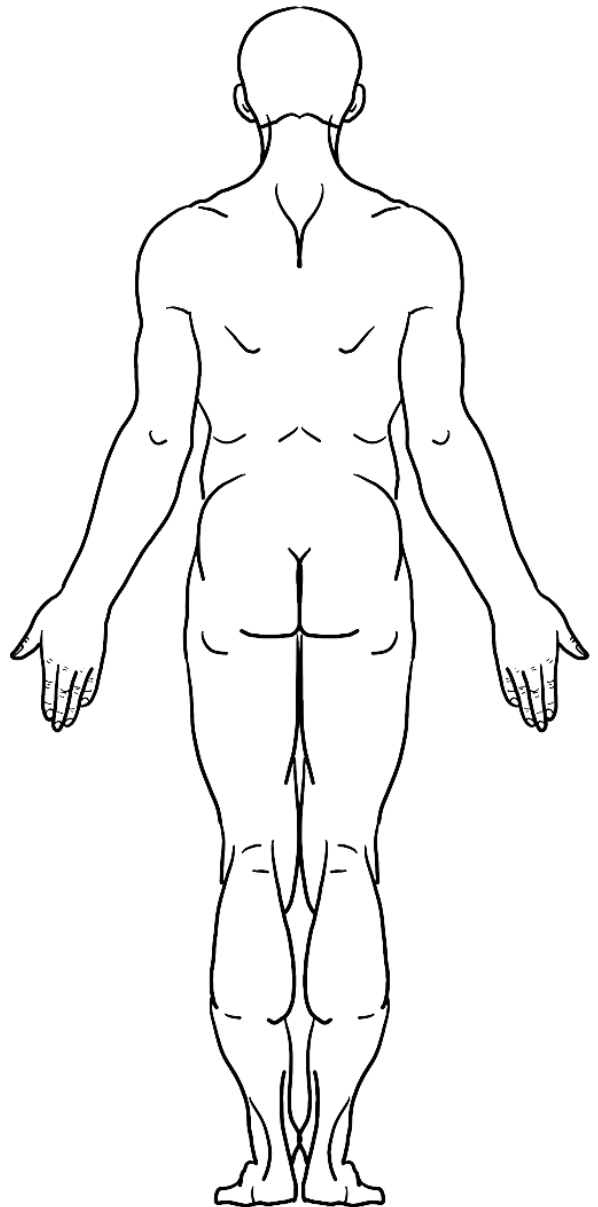
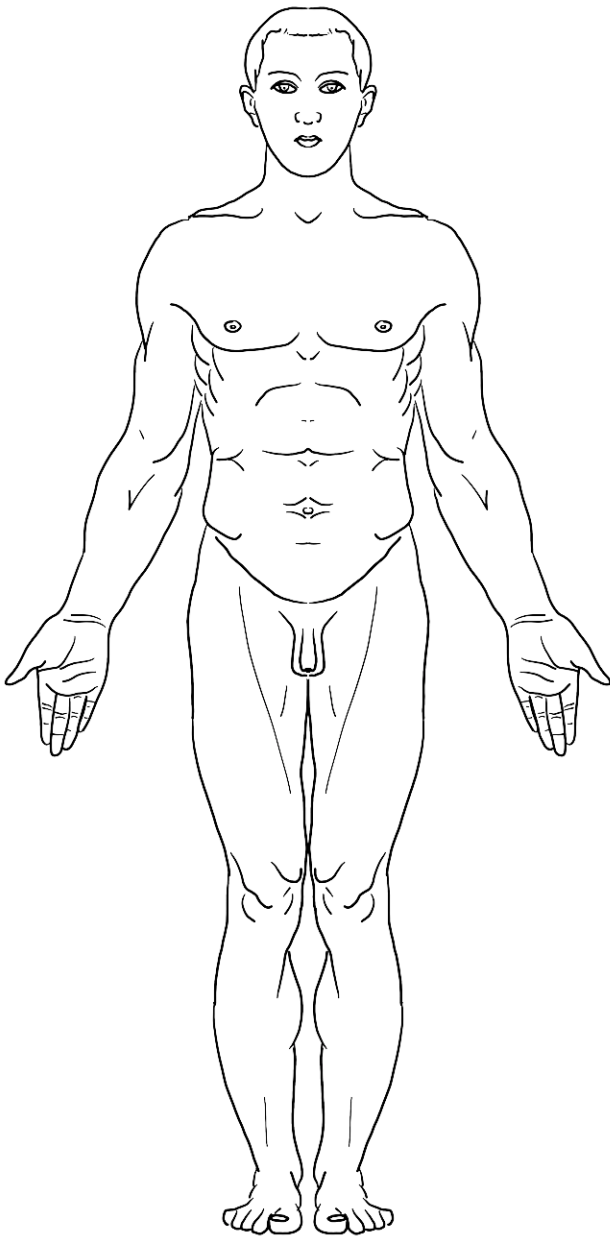


ECUE 7 – ANATOMIE GÉNÉRALE

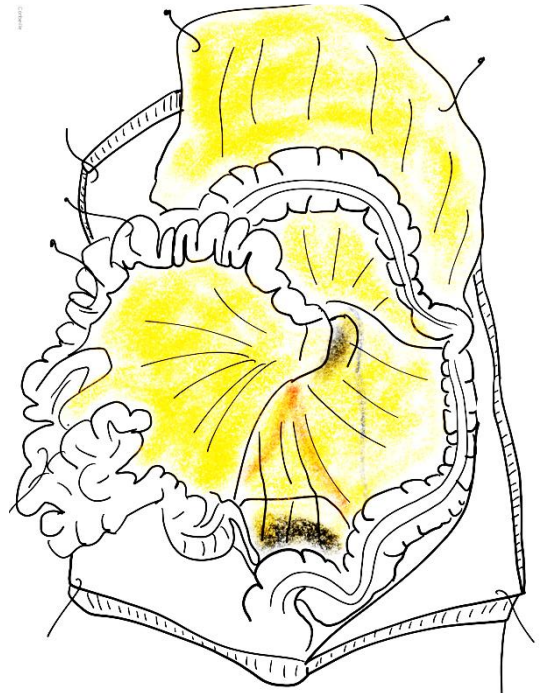
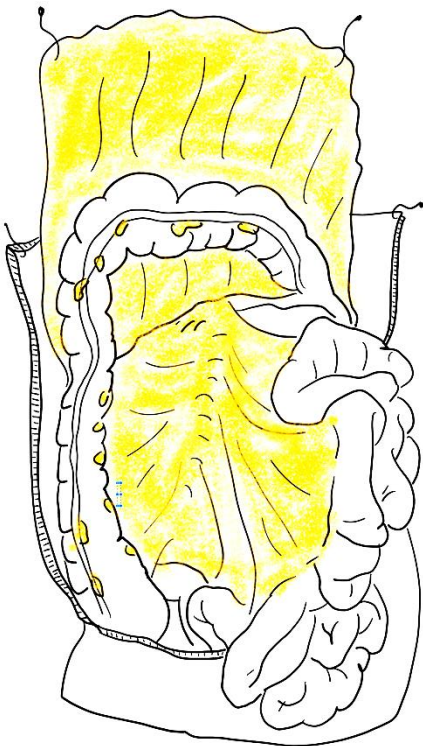
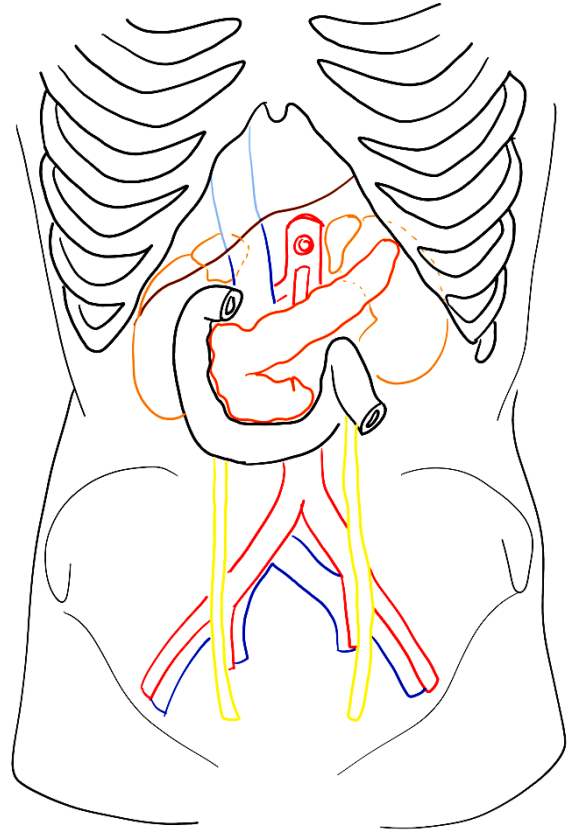
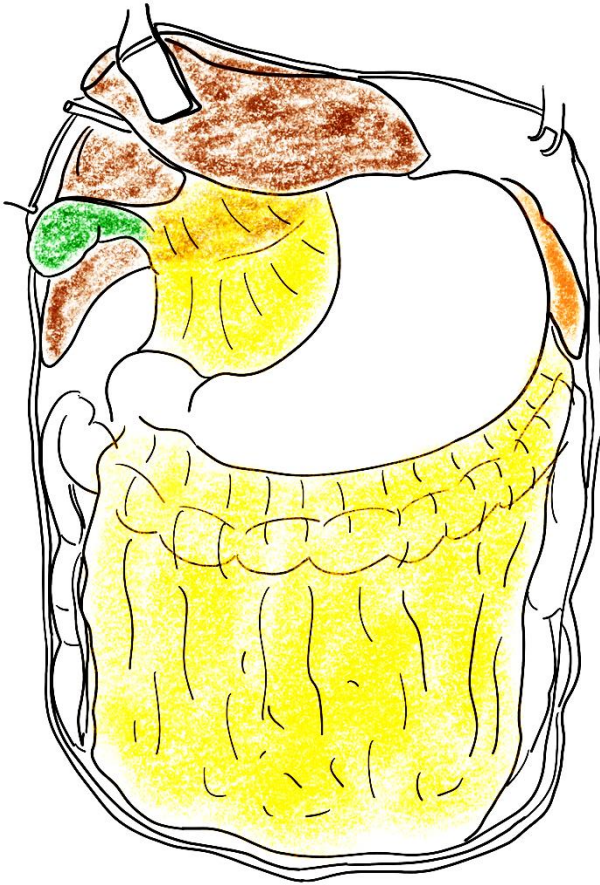
CONFÉRENCE N°3 : Appareil digestif

I/ ORGANISATION GÉNÉRALE DE L'ABDOMEN

a/ Anatomie de surface

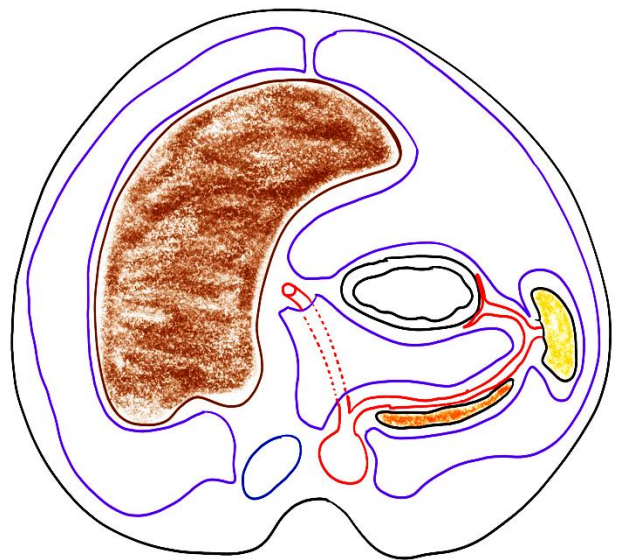
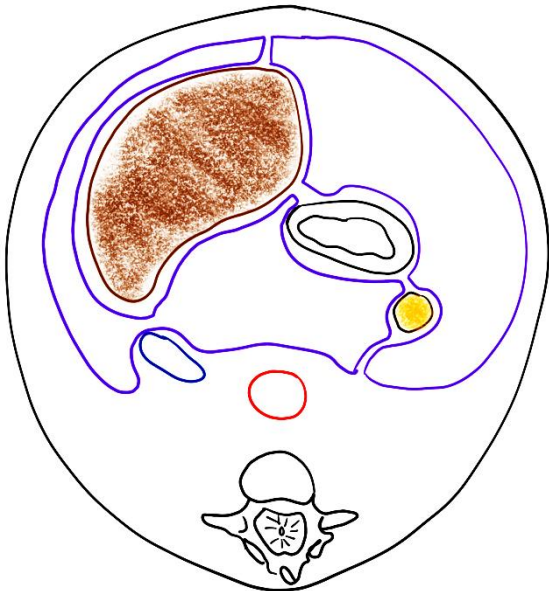
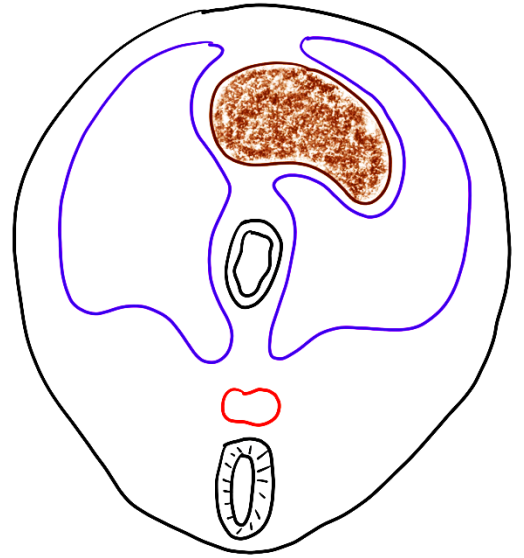
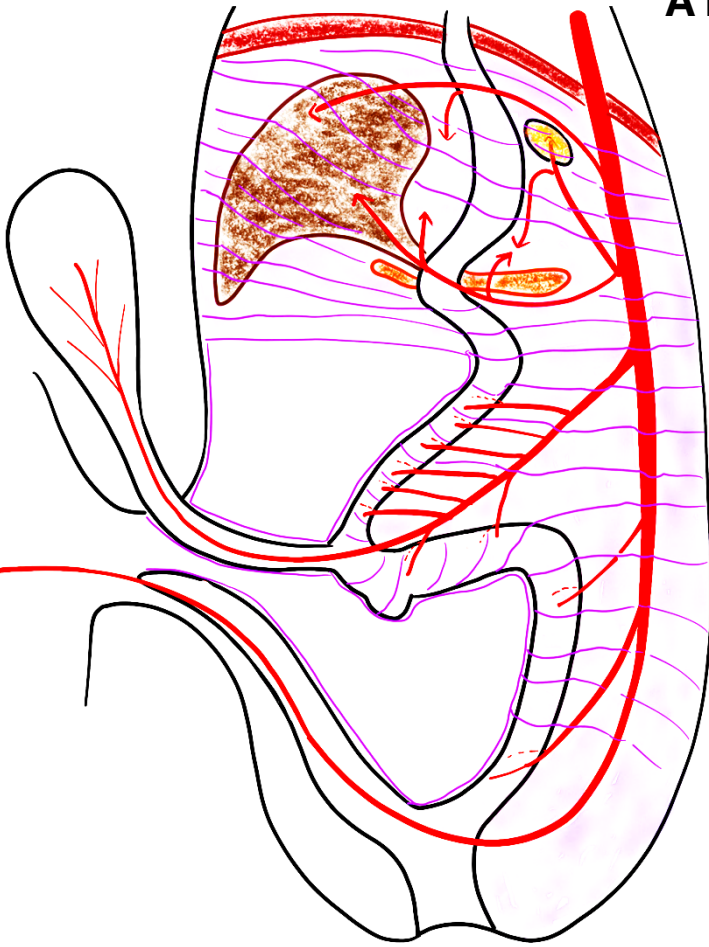


b/ Anatomie topographique générale de la cavité thoracique

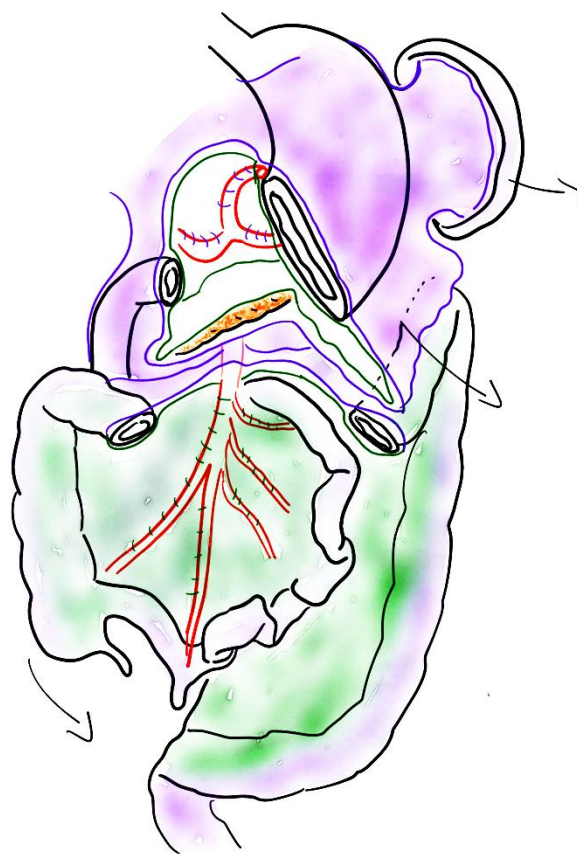
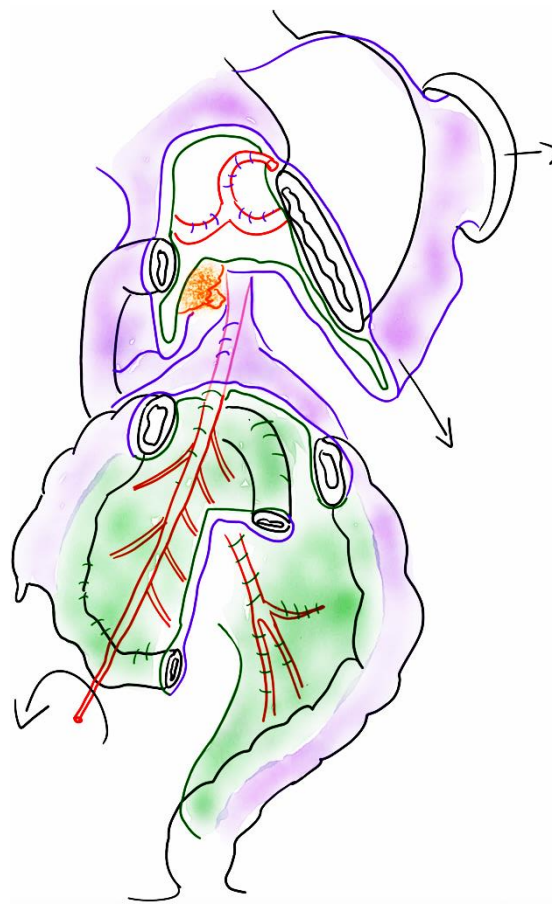
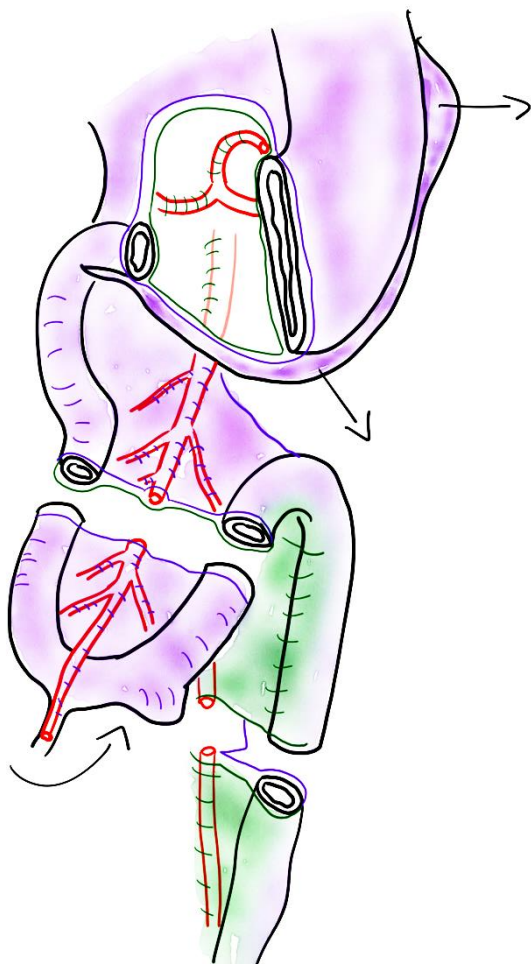


c/ explication de la topographie générale des viscères de l'abdomen par l'embryologie

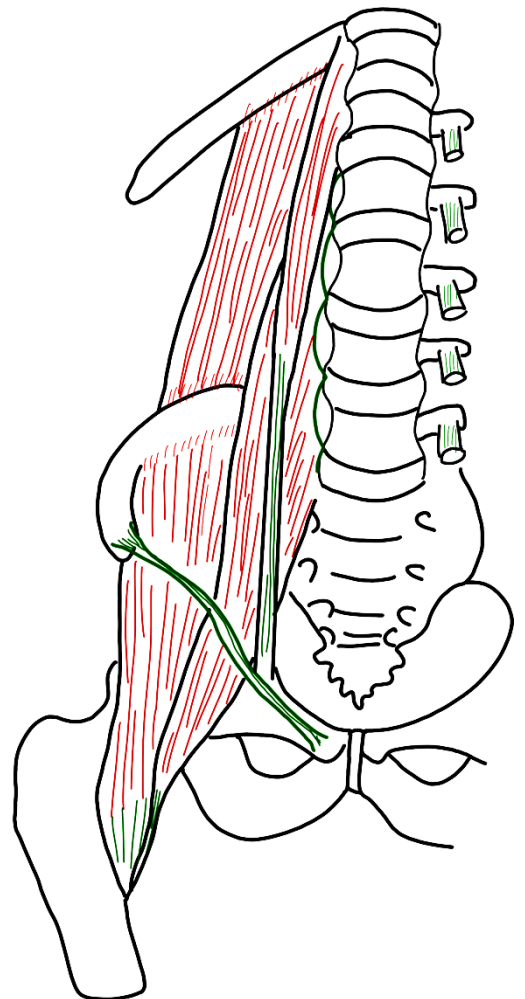
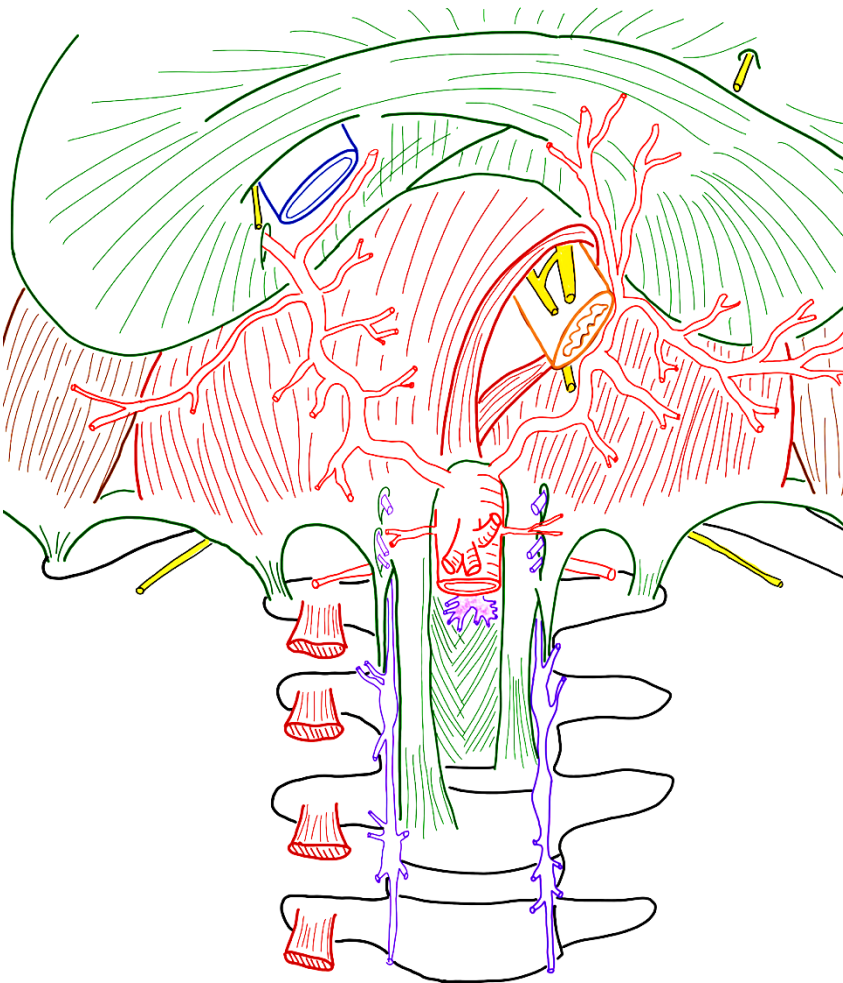
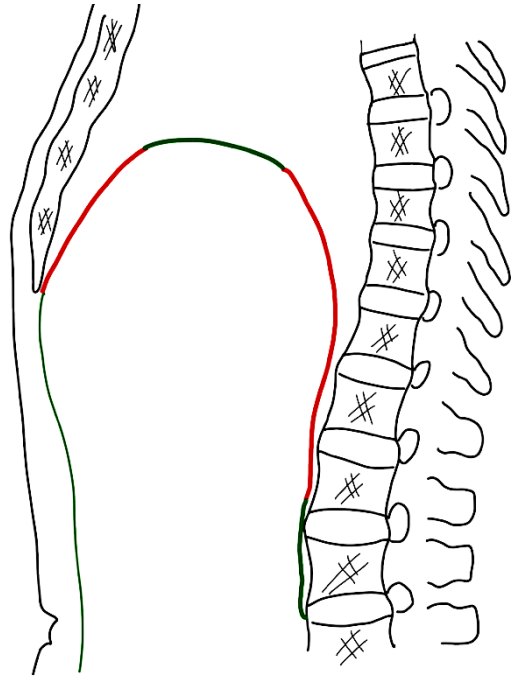
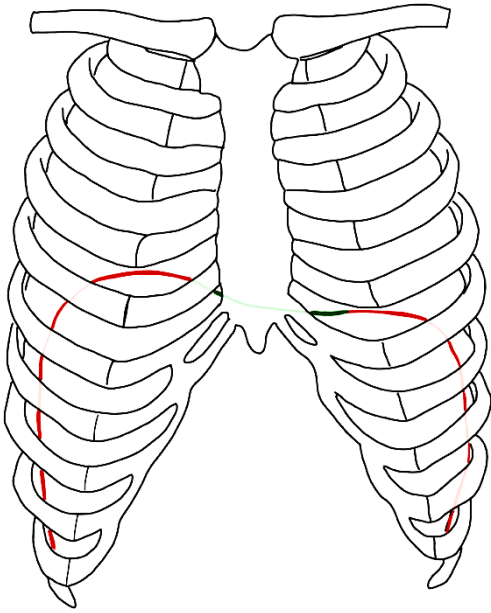
À L'ÉTAGE SUPRA-MÉSOCOLIQUE



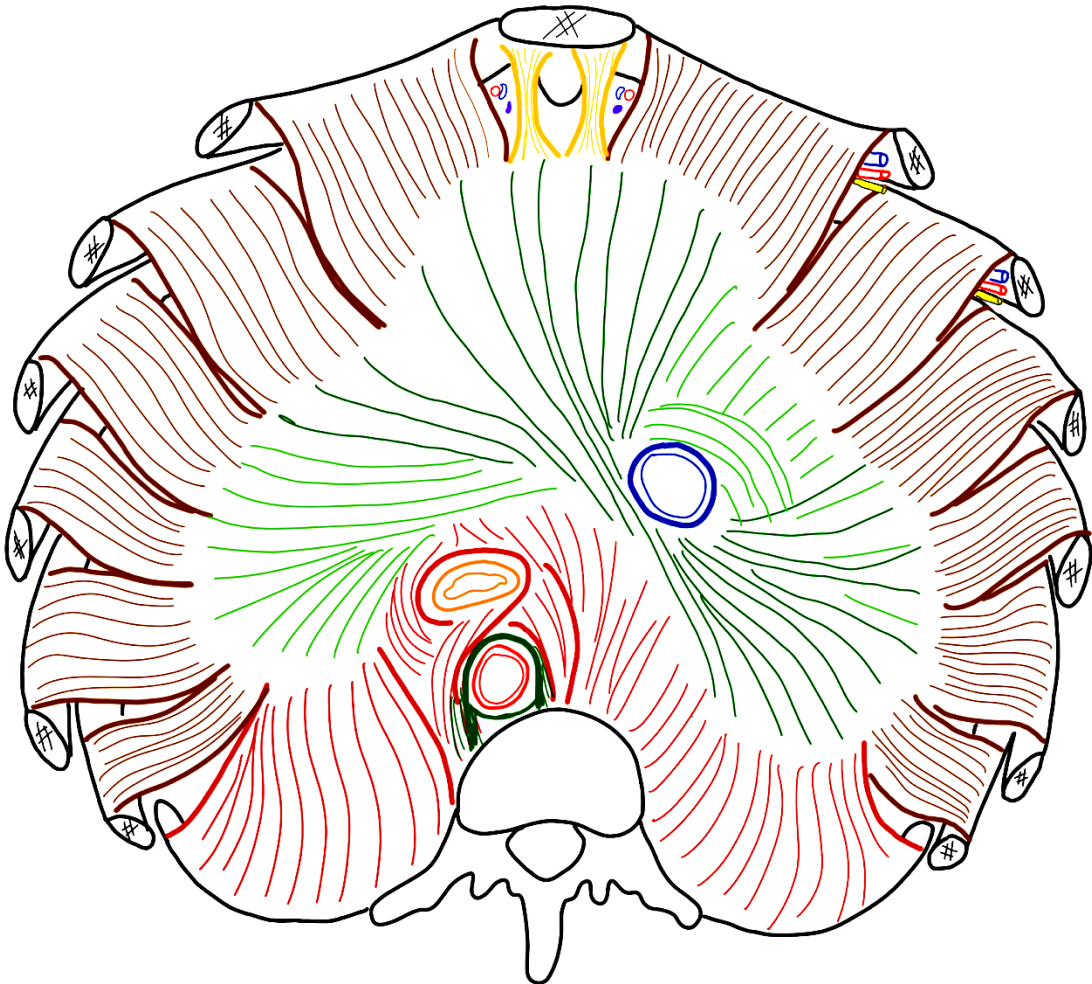
À L'ÉTAGE INFRA-MÉSOCOLIQUE



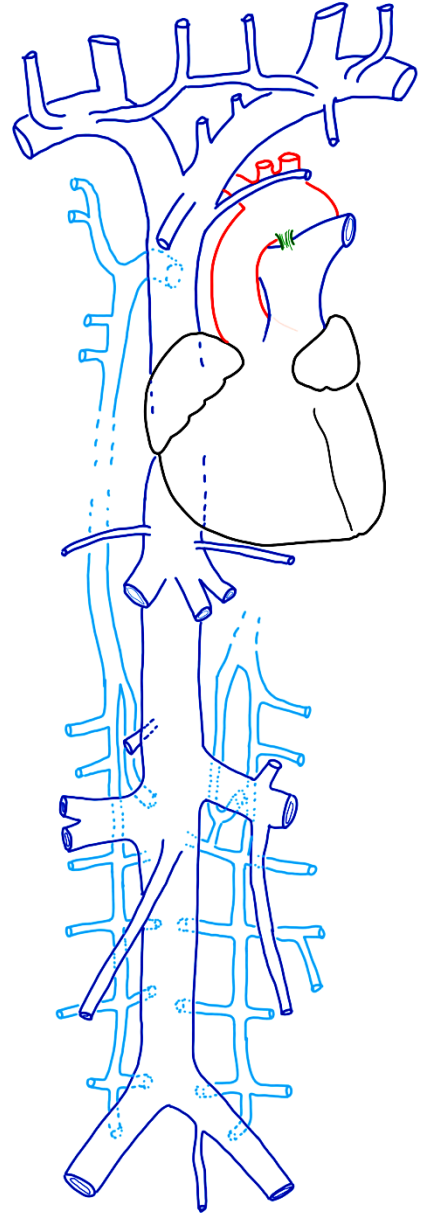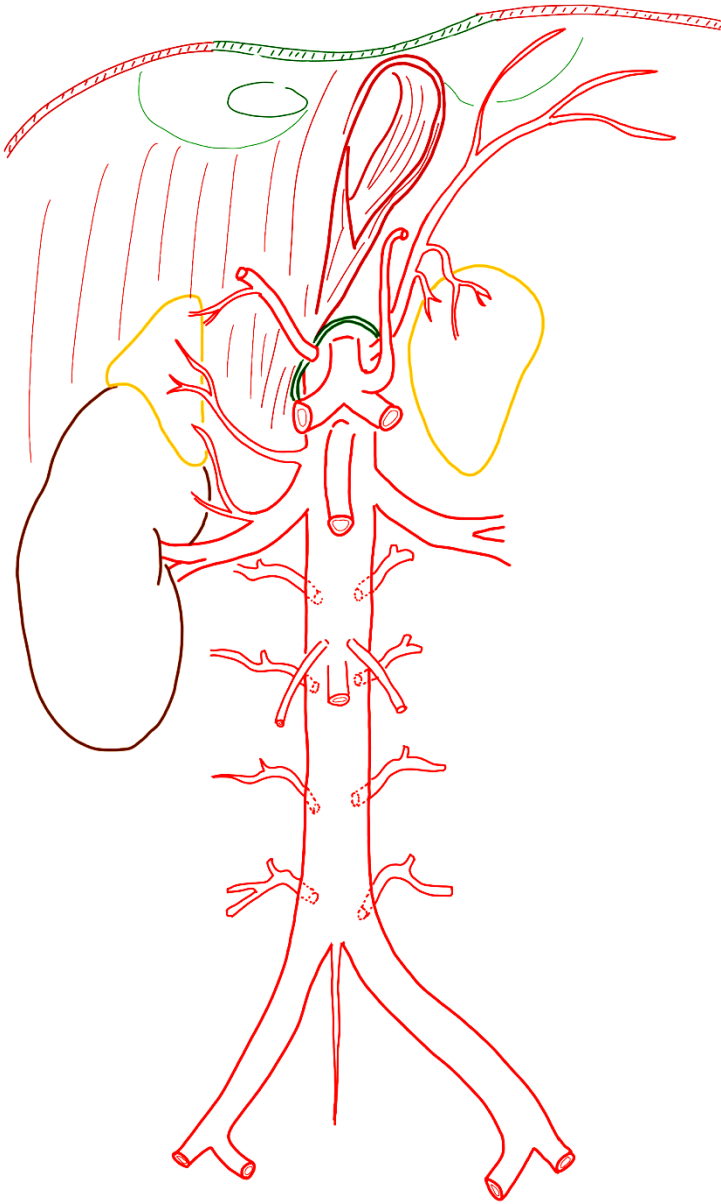
II/ LA PAROI POSTÉRIEURE DE L'ABDOMEN



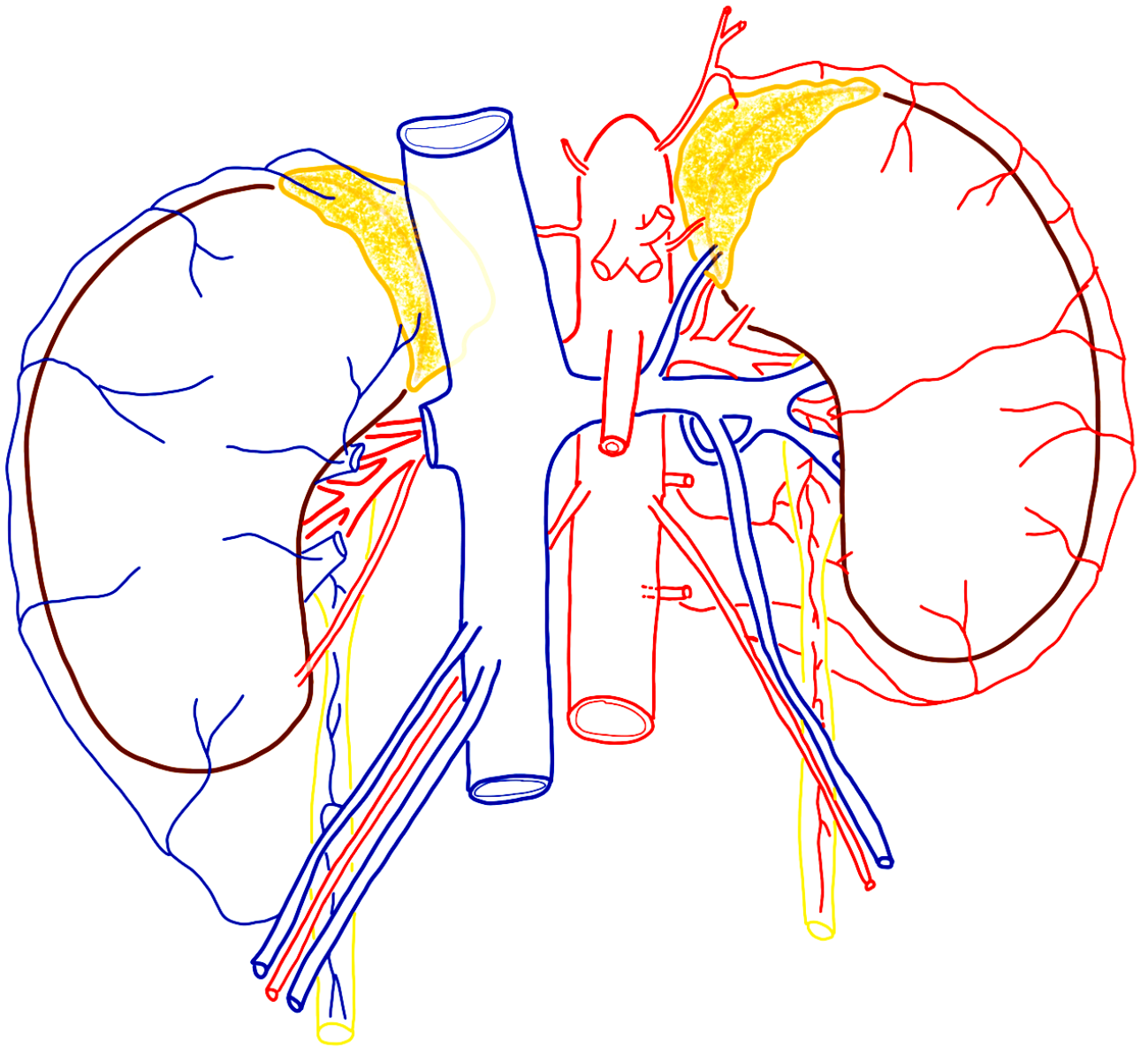
III/ LA PAROI SUPÉRIEURE DE L'ABDOMEN : LE DIAPHRAGME THORACO-ABDOMINAL



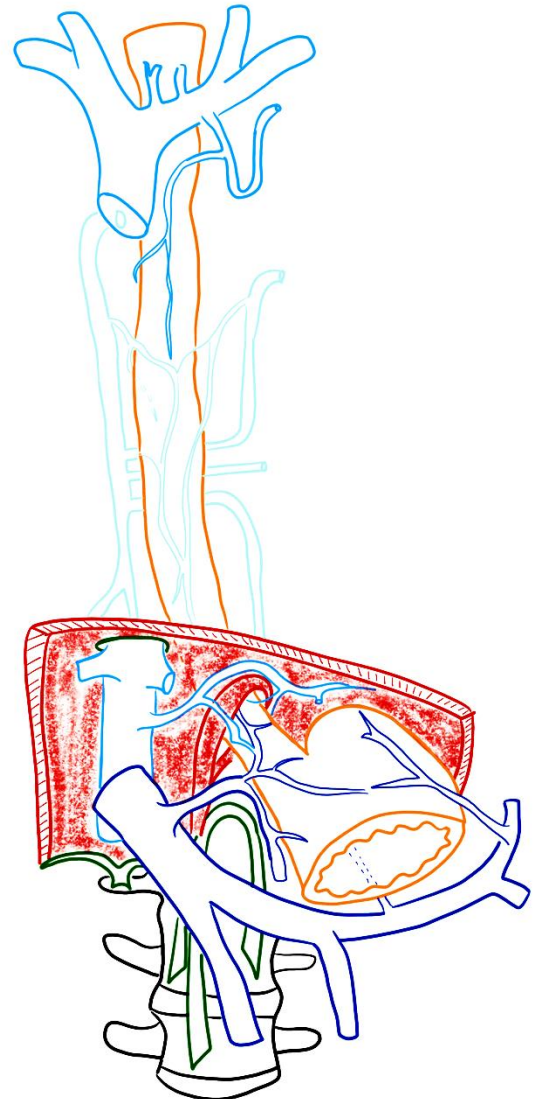
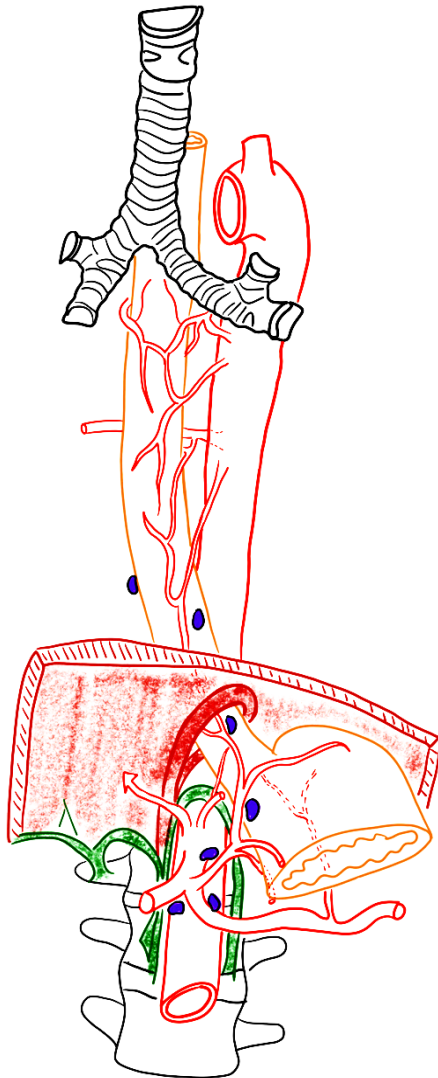
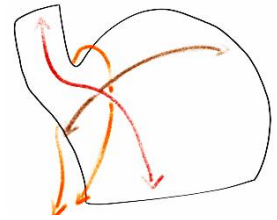
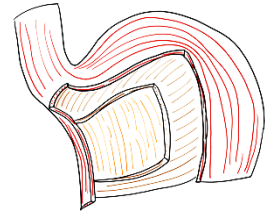
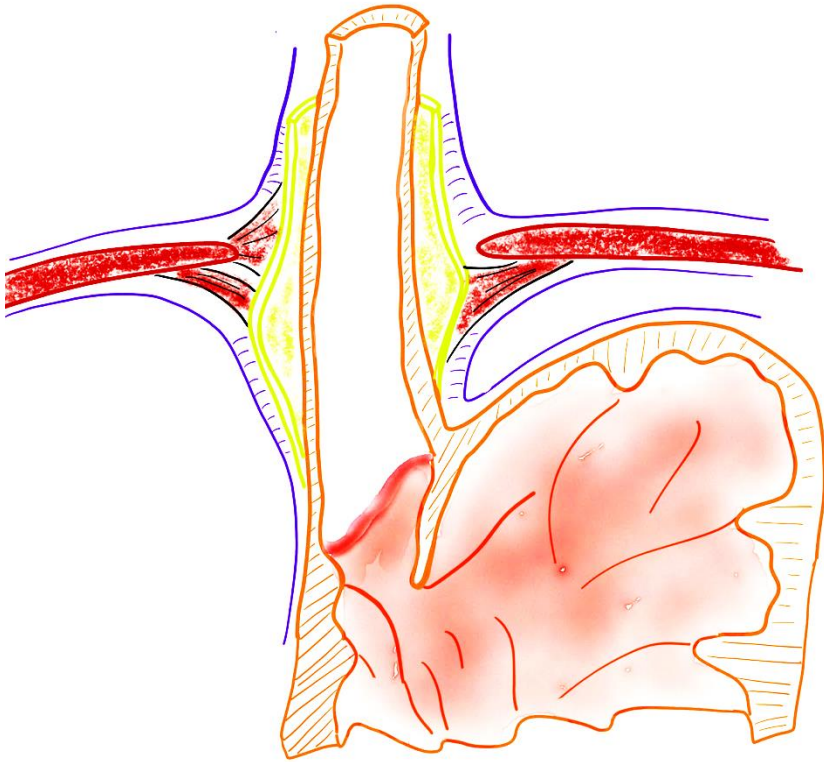
IV/ L'ESPACE RÉTROPÉRITONÉAL - AORTE ABDOMINALE - VEINE CAVE et SYSTÈME AZYGOS



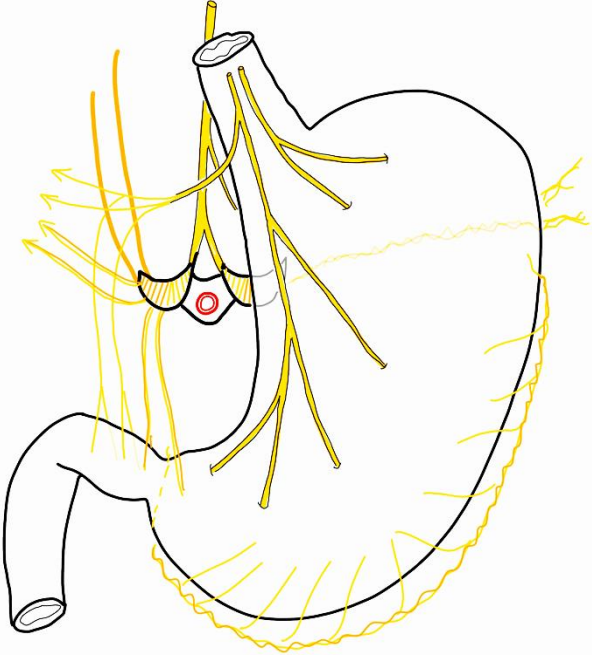
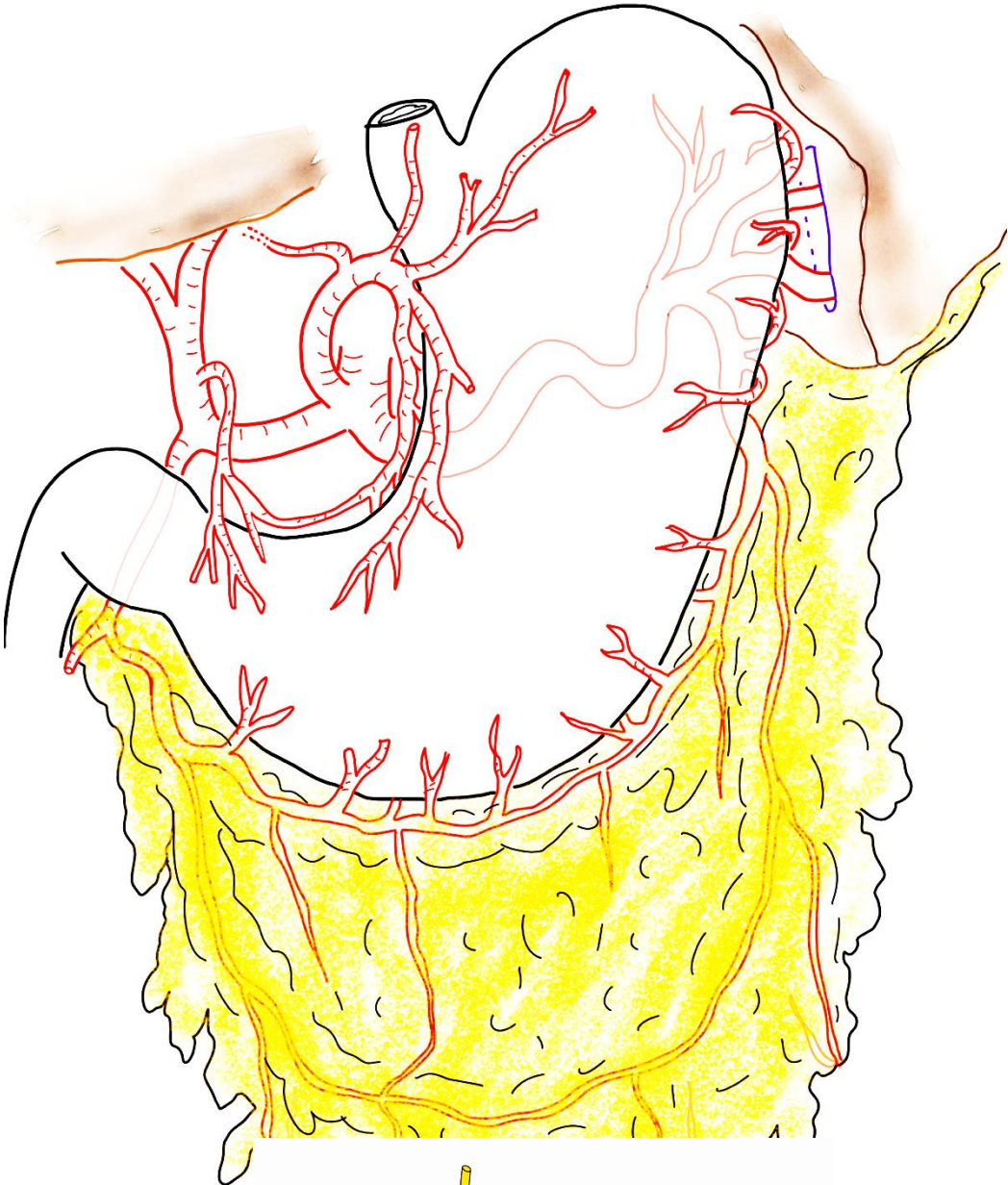
V/ APPAREIL URINAIRE HAUT et GLANDES SURRÉNALES



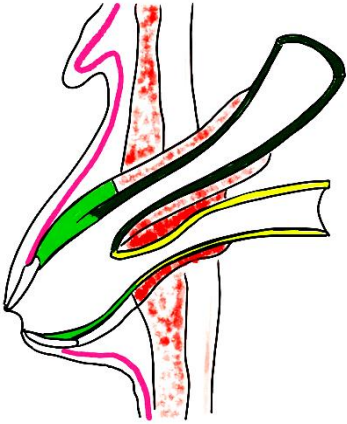
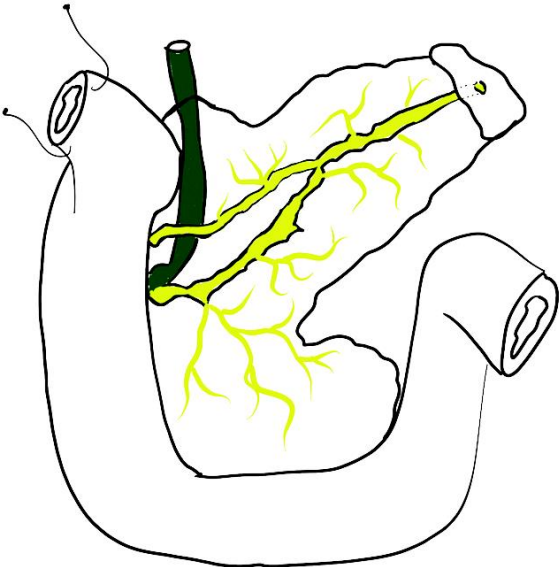
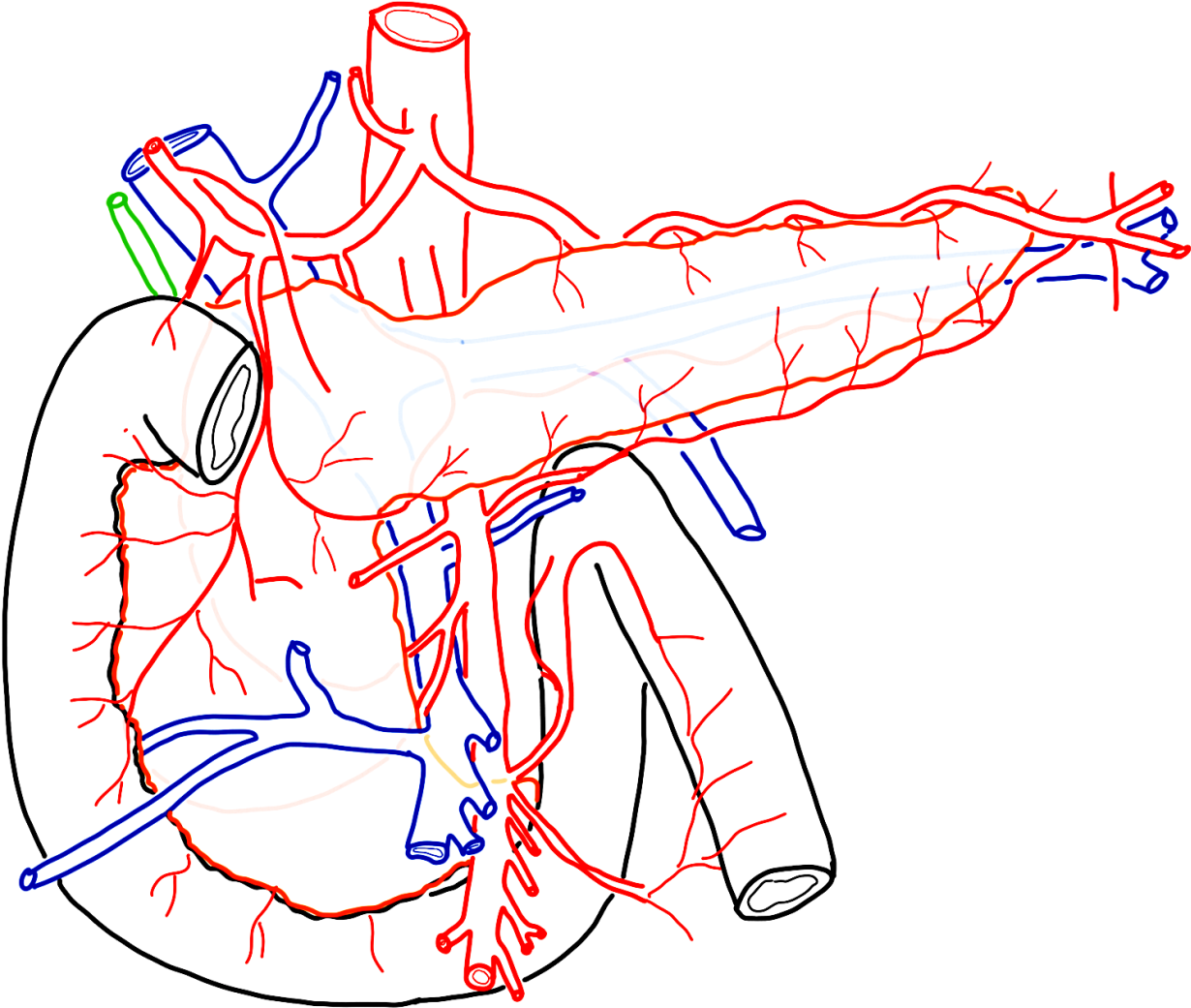
VI/ JONCTION OESO-GASTRIQUE



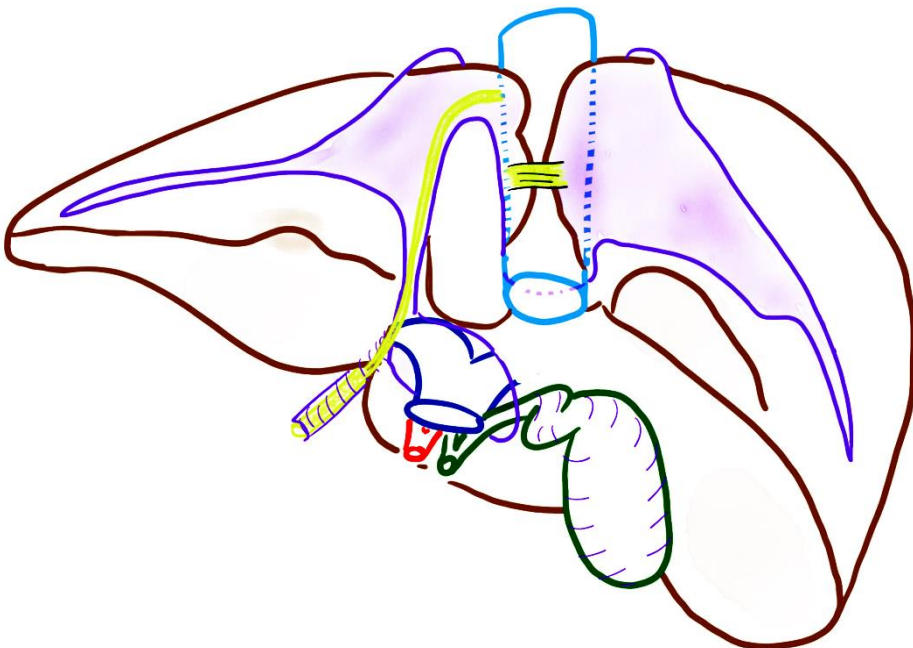
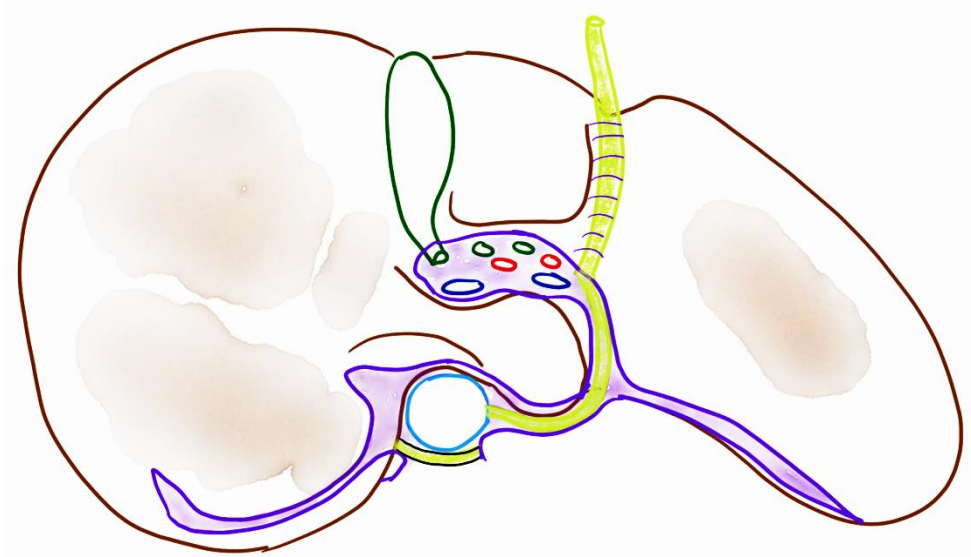
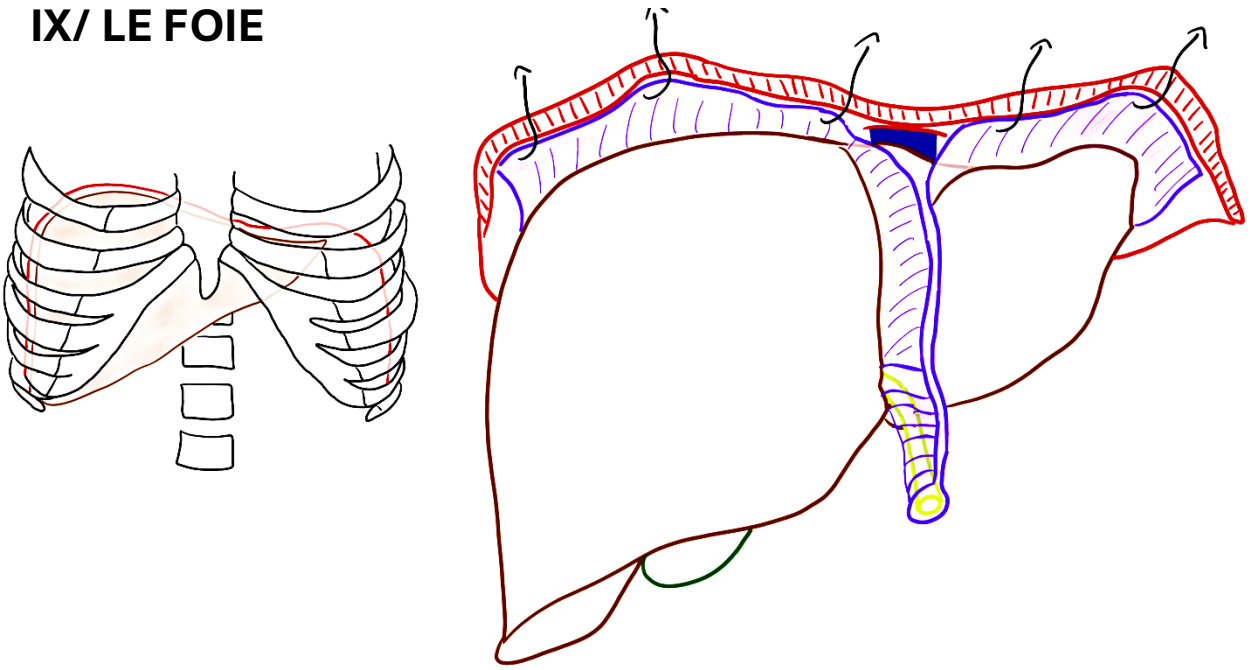
VII/ ESTOMAC



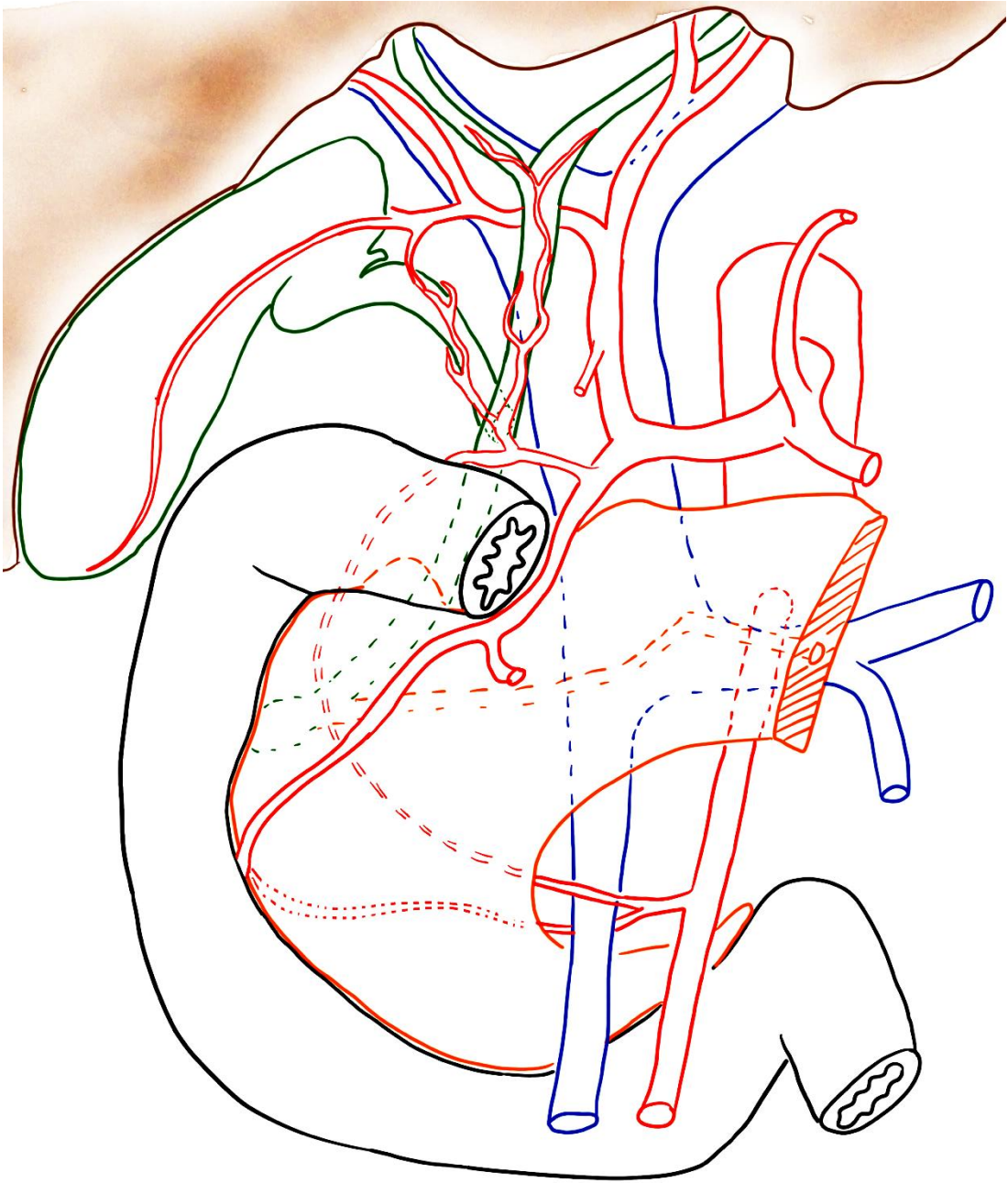
VIII/ BLOC DUODÉNO-PANCRÉATIQUE



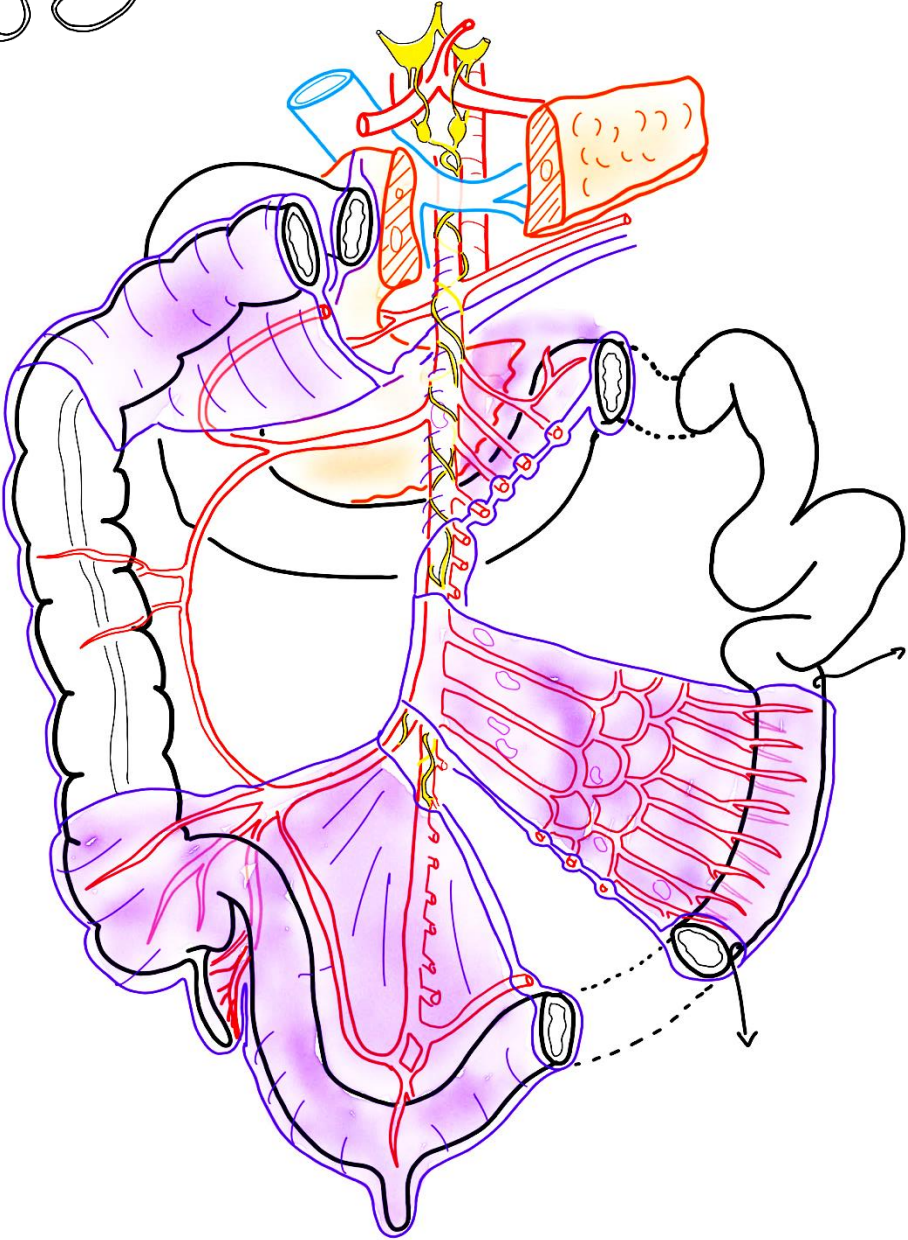
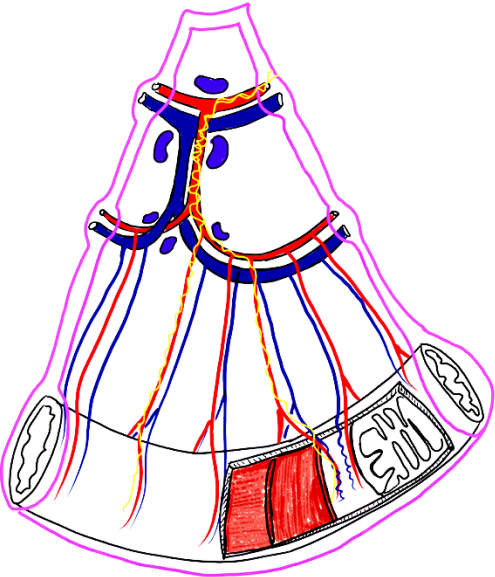
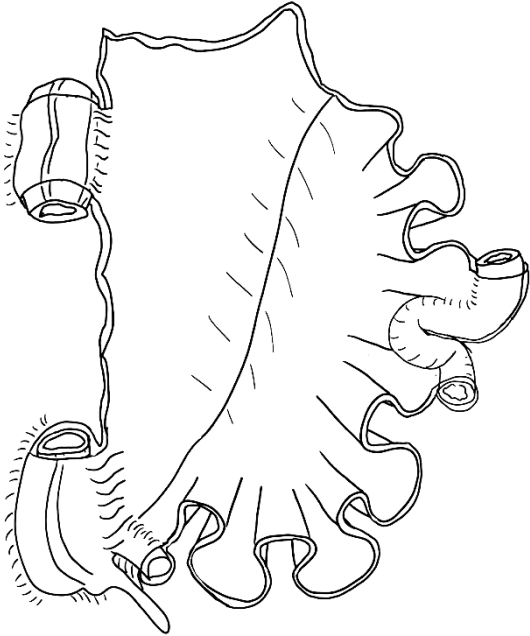
IX/ LE FOIE



X/ PÉDICULE HÉPATIQUE



XI/ L'INTESTIN GRÊLE et le MÉSENTÈRE



XII/ LA JONCTION ILÉO-CAECALE – LES COLONS

