

**CONFÉRENCES D'ANATOMIE  
LAS-1  
UFR MÉDECINE DE NICE  
ANNÉE UNIVERSITAIRE 2025-2026**

**Programme**

1° leçon - Lundi 9 février (8h-12h) **Pr BAQUÉ**  
**CARDIO VASC ET RESPIRATOIRE (anatomie générale)**

2° leçon - Lundi 16 février (8h-12h) **Dr D'ANDRÉA**  
**TÉTÉ et COU-1**

Lundi 23 février (8h-12h)  
***Pause pédagogique***

3° leçon - Lundi 2 mars (8h-12h) **Pr BAQUÉ**  
**ABDOMEN (anatomie générale)**

4° leçon - Lundi 9 mars (8h-12h) **Pr BRONSARD**  
**MEMBRE SUP (anatomie générale)**

5° leçon - Lundi 16 mars (8h-12h) **Pr BRONSARD**  
**MEMBRE INF (anatomie générale)**

6° leçon – Lundi 23 mars (8h-12h) **Pr BAQUÉ**  
**APPAREIL GENITAL-1**

7° leçon - Lundi 30 mars (8h-12h) - **Pr BAQUÉ – Dr D'ANDRÉA**  
**2H APPAREIL GENITAL-2 (PB) et 2H TETE ET COU-2 (GDA)**

8<sup>ème</sup> leçon - Lundi 13 avril (8h-12h) - **Pr BAQUÉ – Dr D'ANDRÉA**  
**SYSTEME NERVEUX CENTRAL ET PERIPHERIQUE (anatomie générale, tête et cou et appareil génital)**

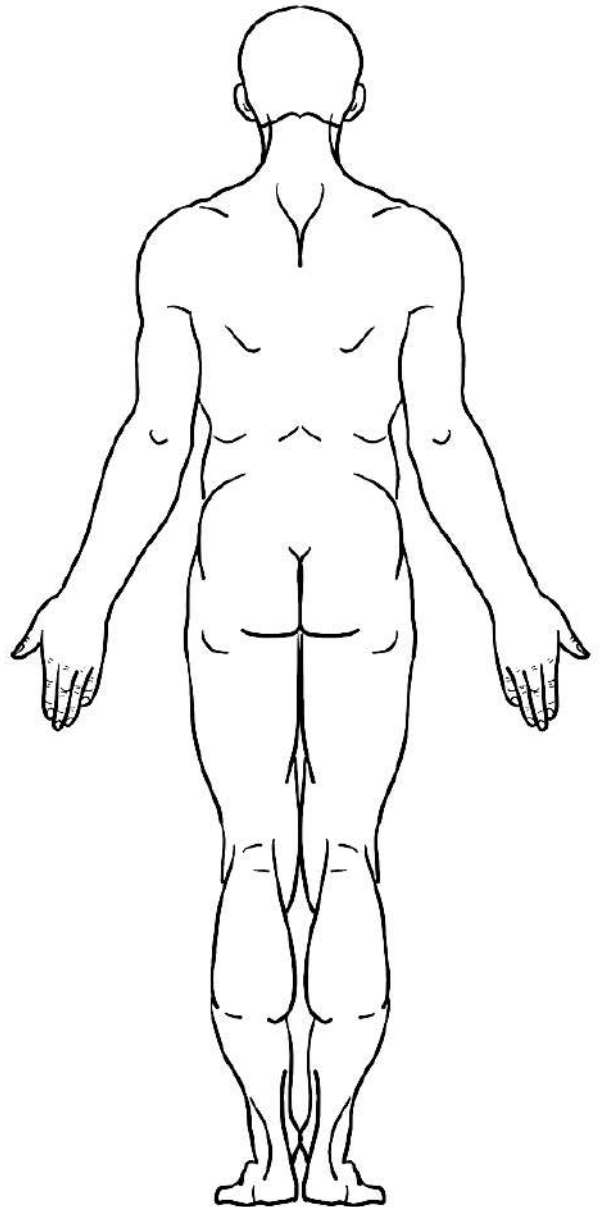
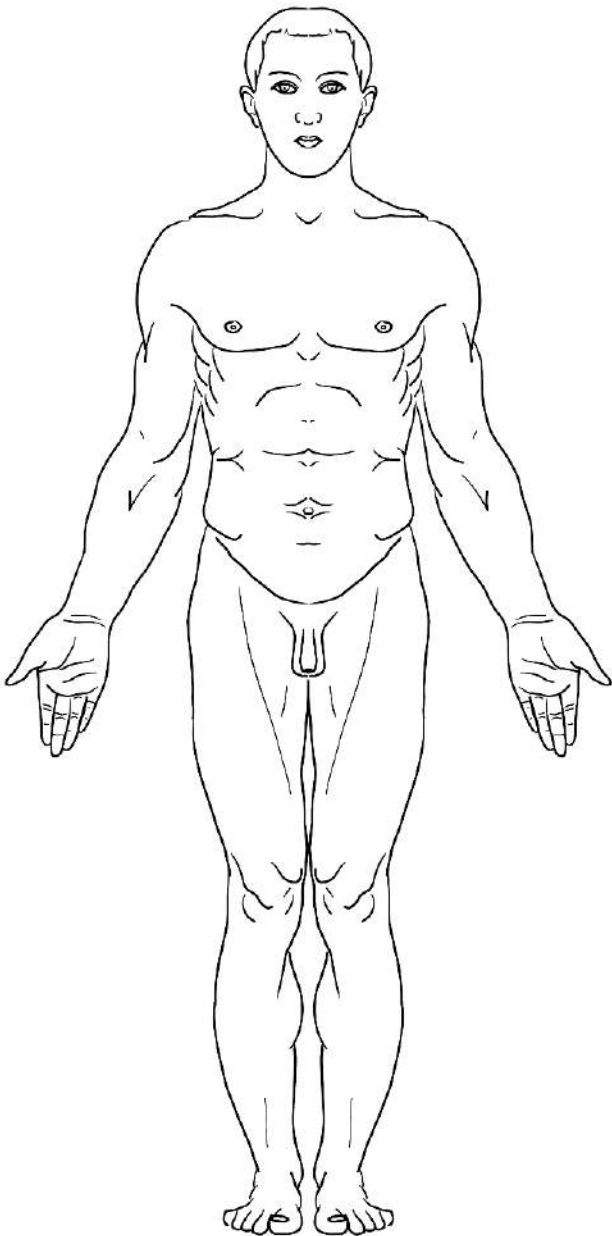
**Laboratoire d'Anatomie  
Pr Patrick BAQUÉ – Pr Nicolas BRONSARD – Dr Grégoire d'ANDRÉA**

# ECUE 7 – ANATOMIE GÉNÉRALE

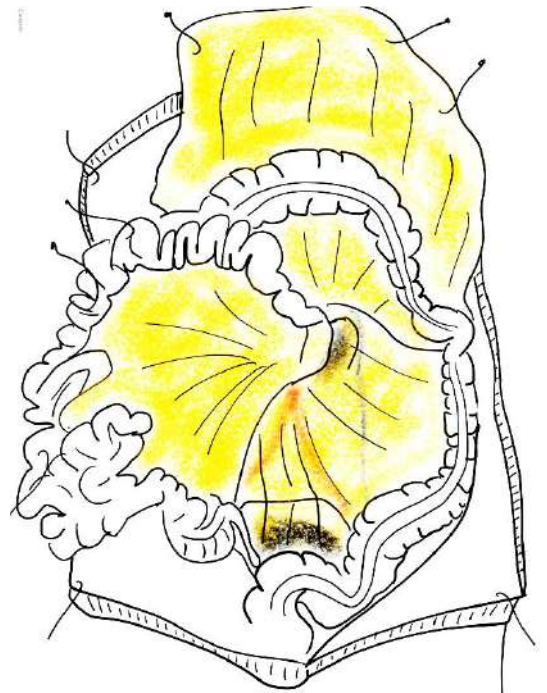
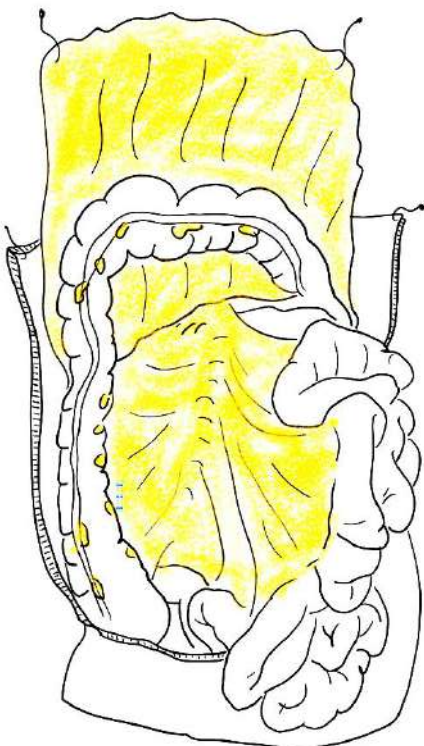
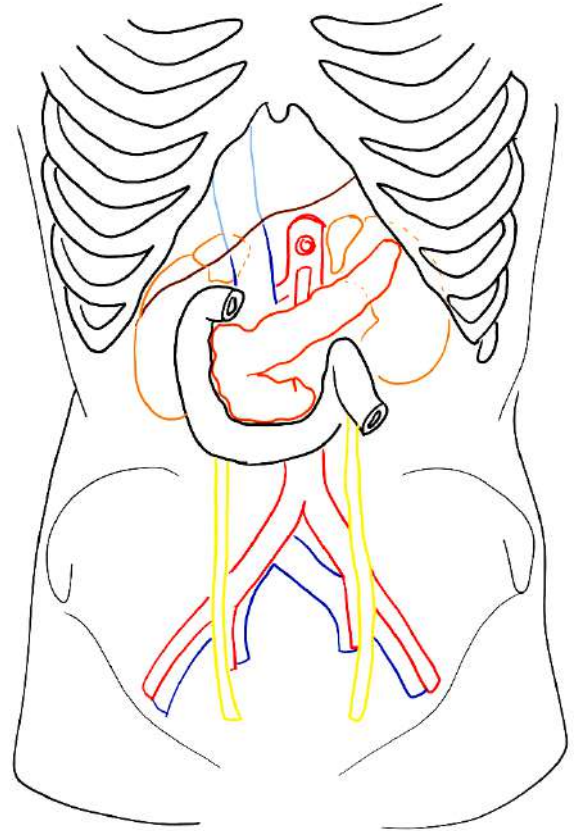
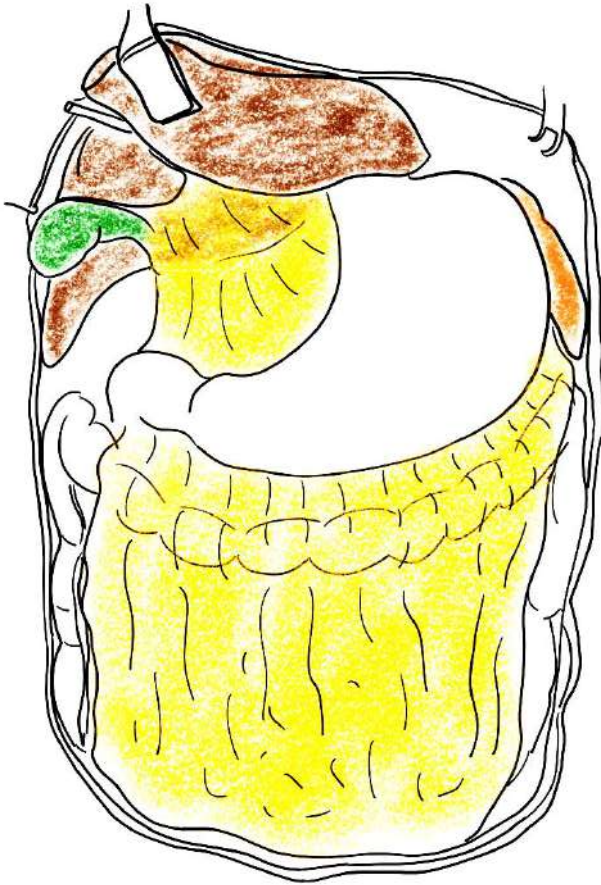
## CONFÉRENCE N°3 : Appareil digestif

### I/ ORGANISATION GÉNÉRALE DE L'ABDOMEN

#### a/ Anatomie de surface

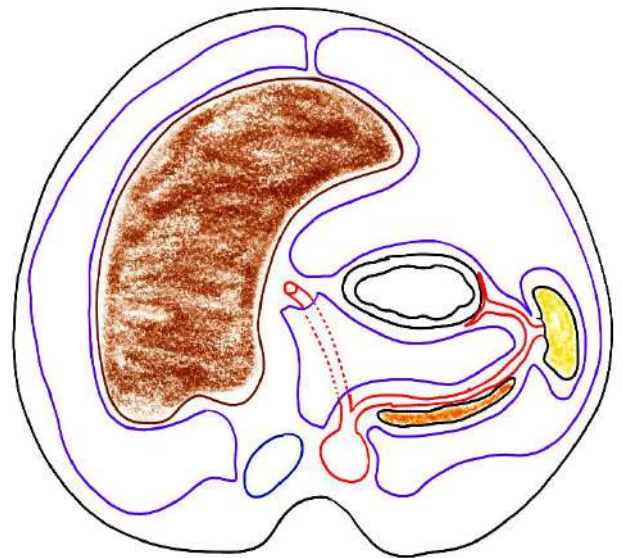
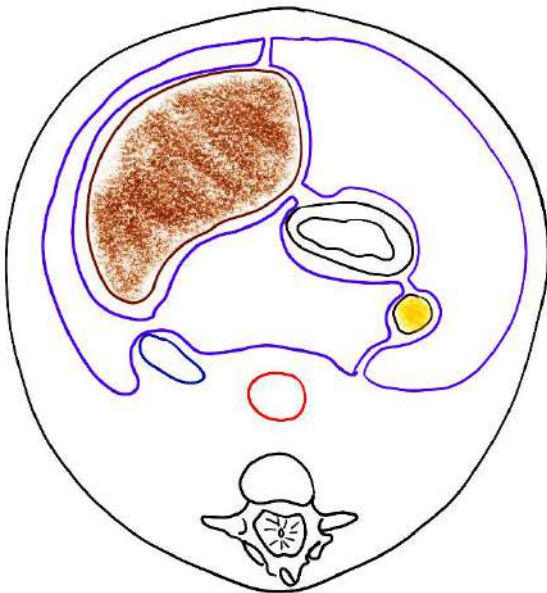
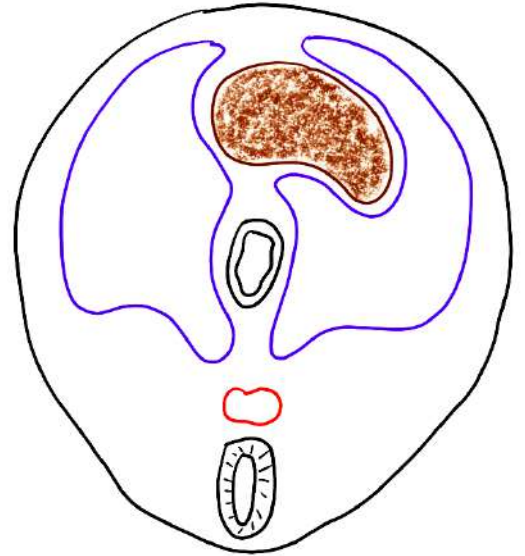
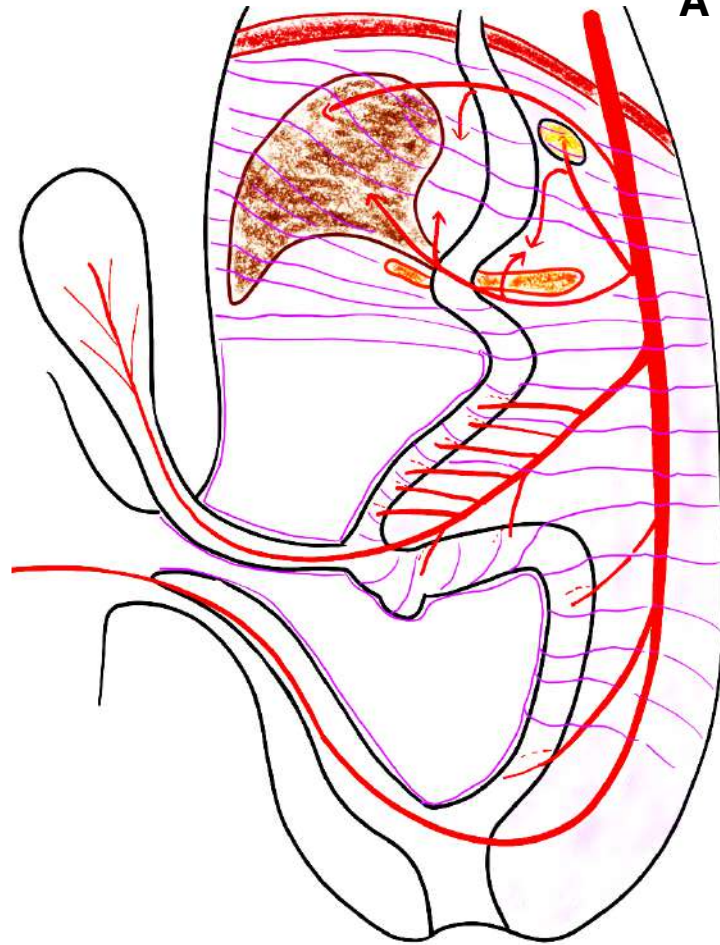


## b/ Anatomie topographique générale de la cavité thoracique

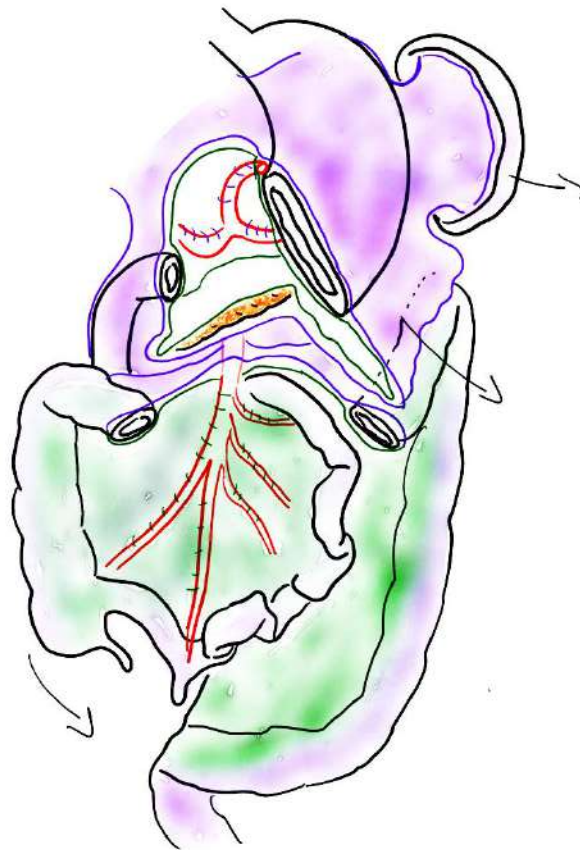
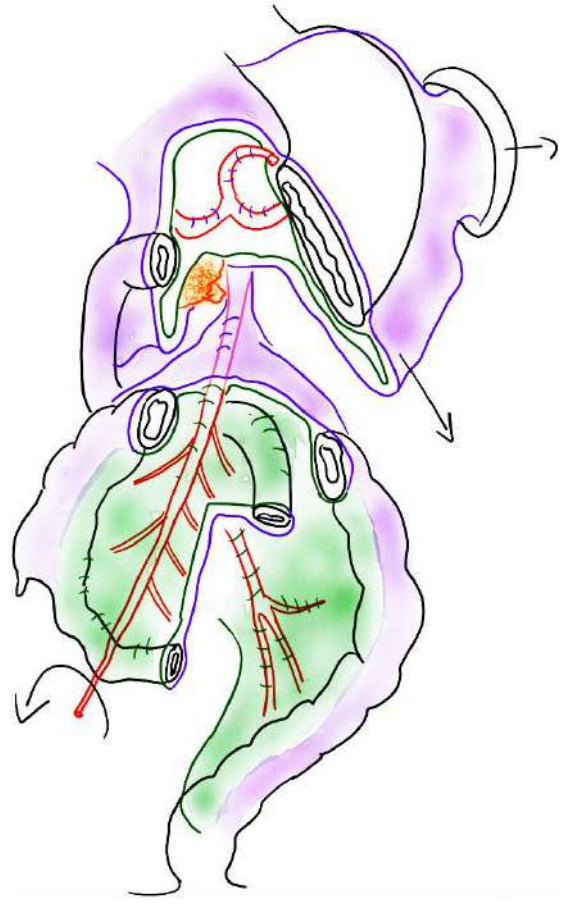
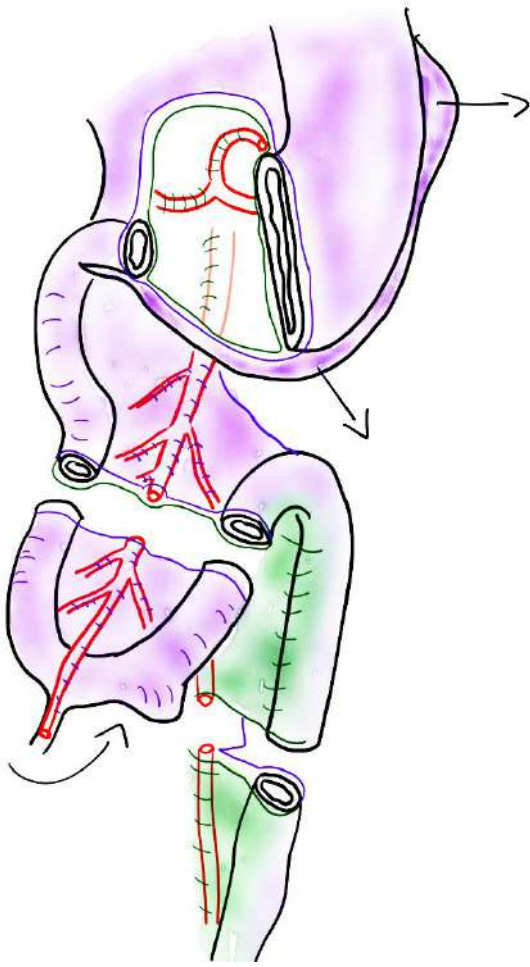


**c/ explication de la topographie générale des viscères de l'abdomen par l'embryologie**

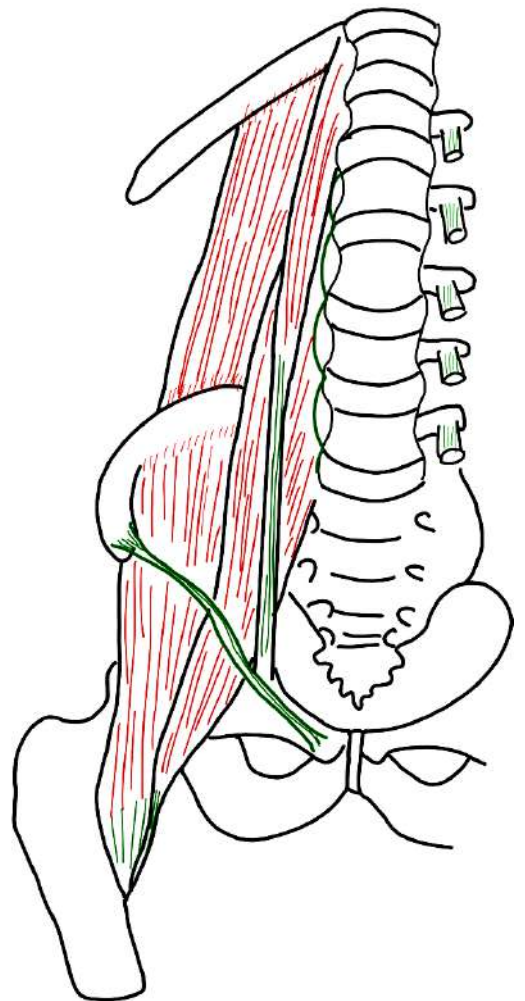
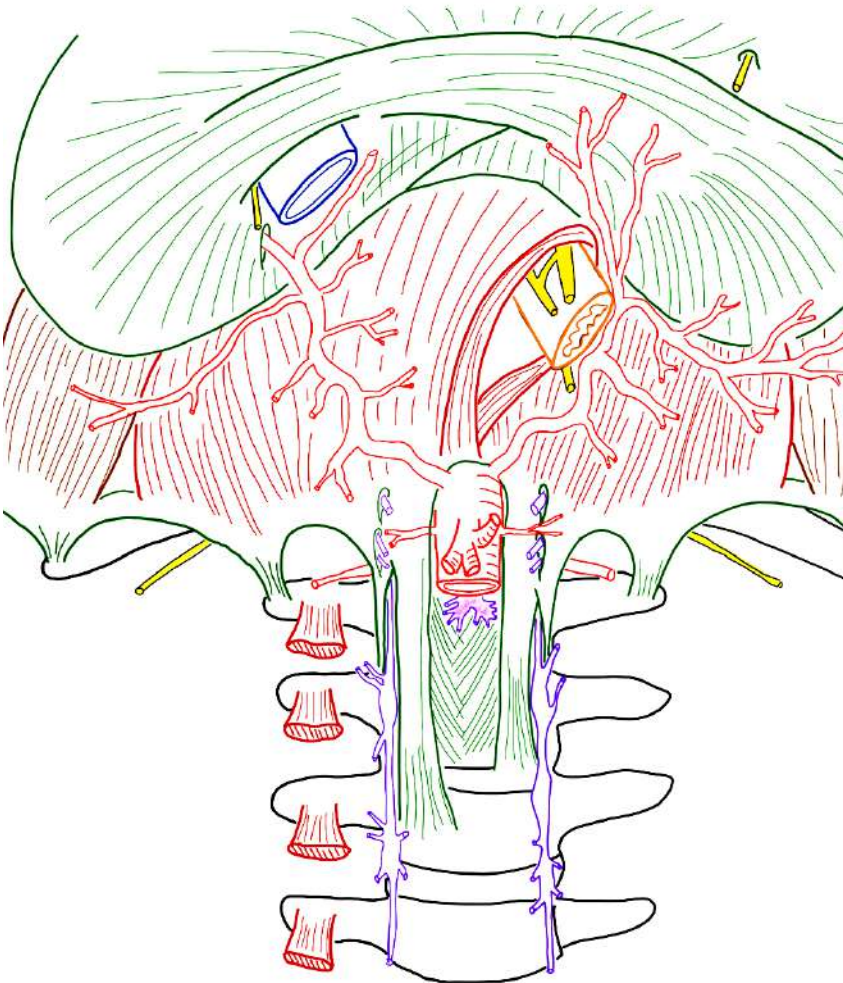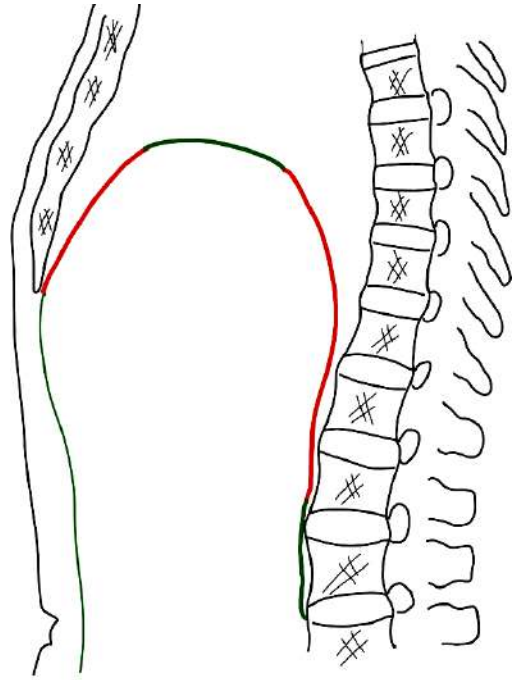
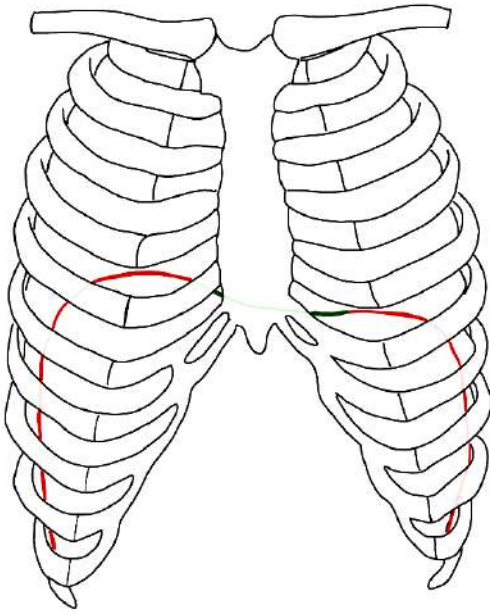
**À L'ÉTAGE SUPRA-MÉSocolIQUE**



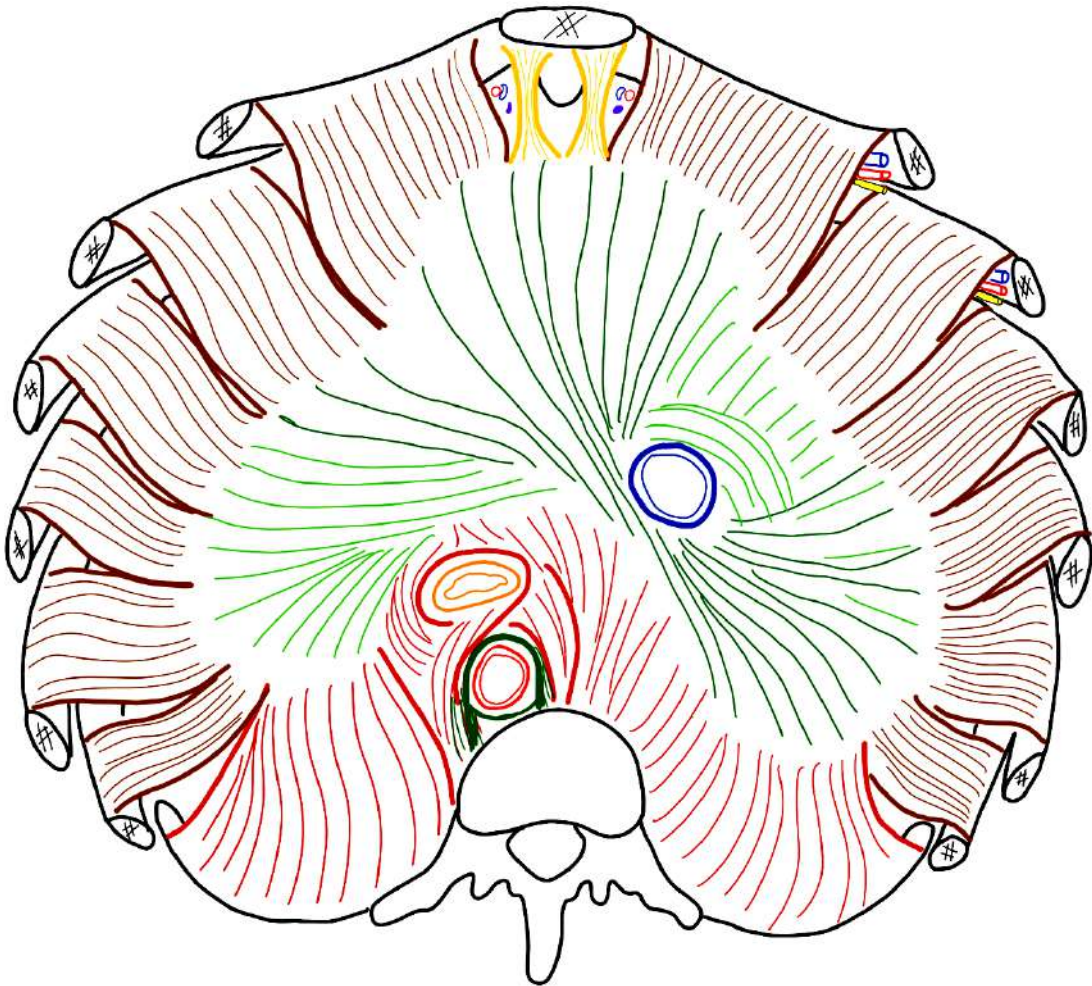
# À L'ÉTAGE INFRA-MÉSocolIQUE



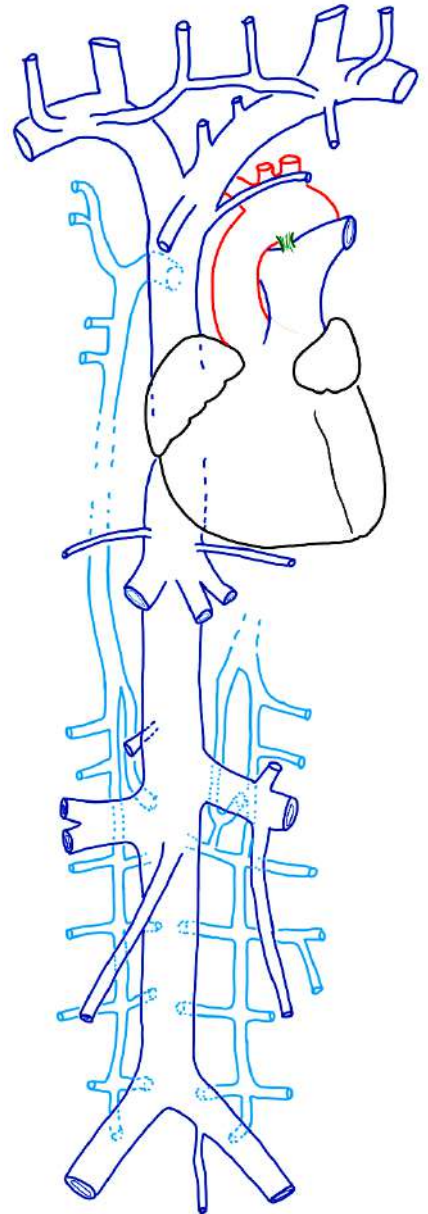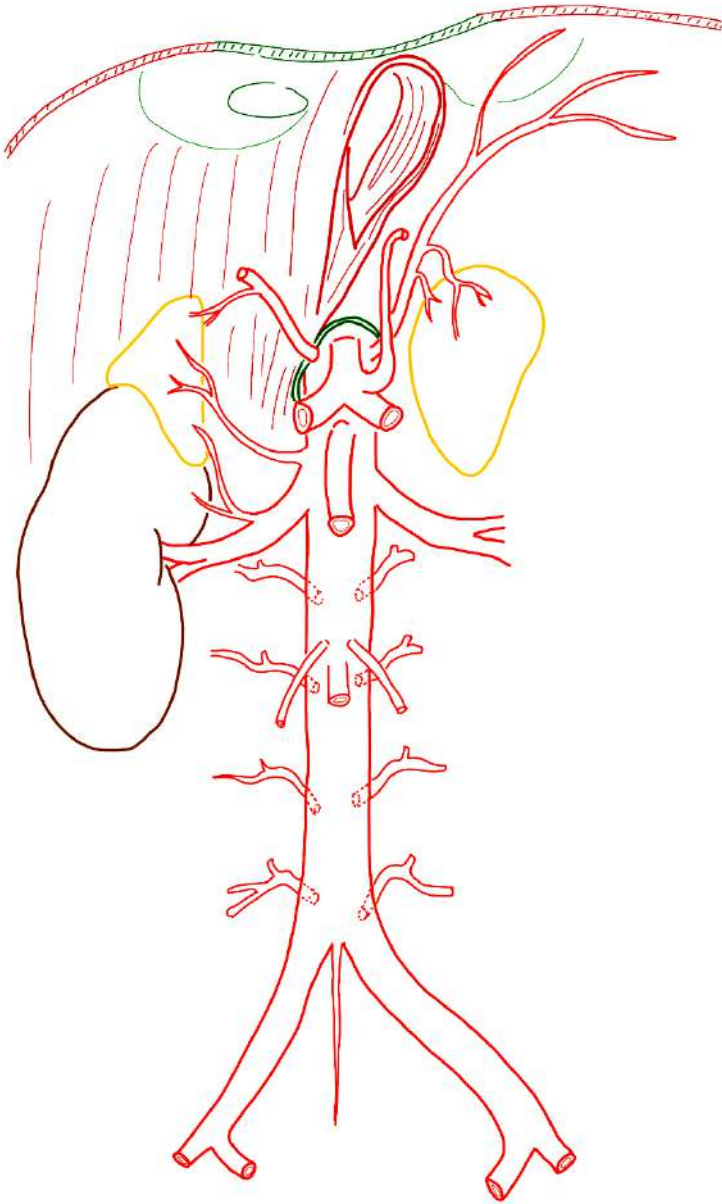
## II/ LA PAROI POSTÉRIEURE DE L'ABDOMEN



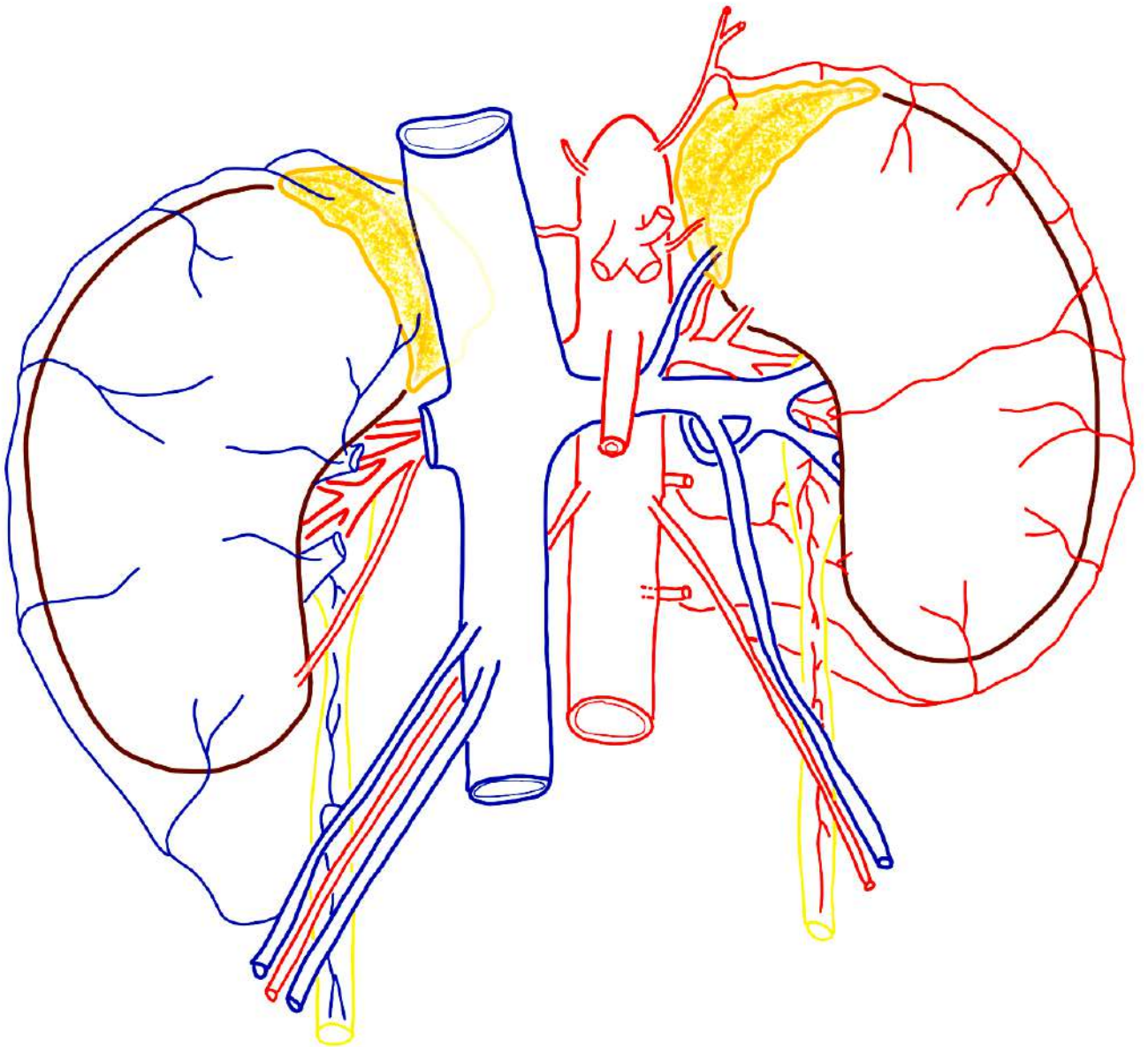
### III/ LA PAROI SUPÉRIEURE DE L'ABDOMEN : LE DIAPHRAGME THORACO-ABDOMINAL



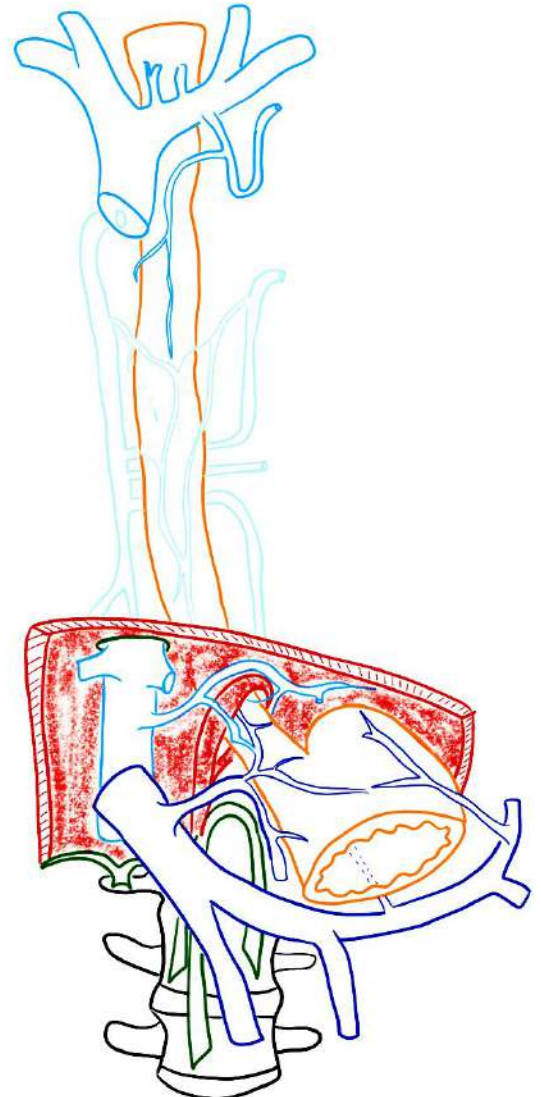
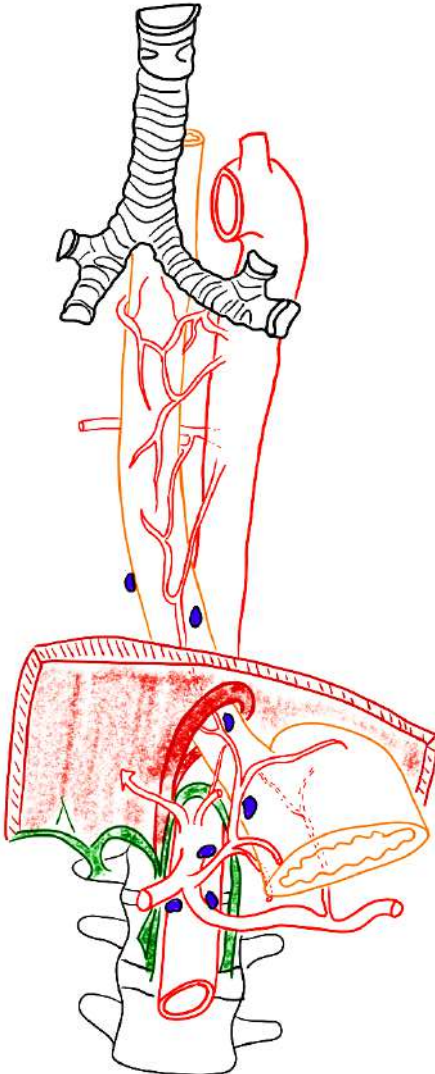
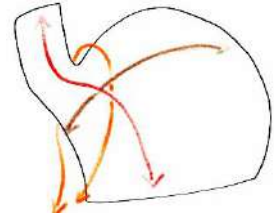
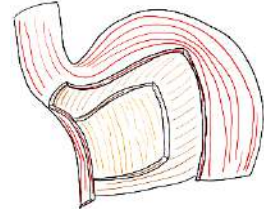
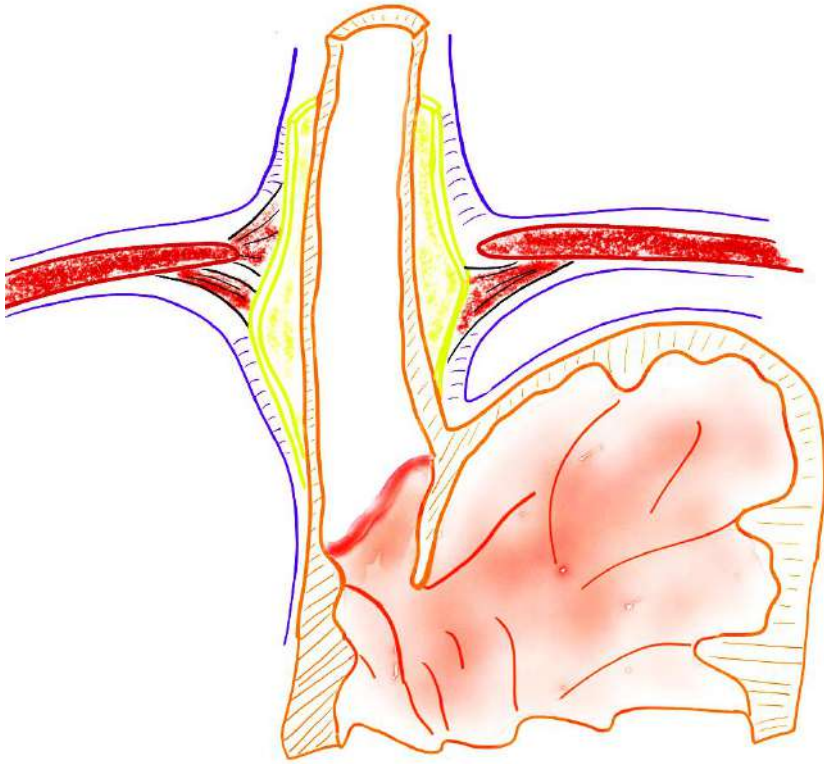
# IV/ L'ESPACE RÉTROPÉRITONÉAL - AORTE ABDOMINALE - VEINE CAVE et SYSTÈME AZYGOS



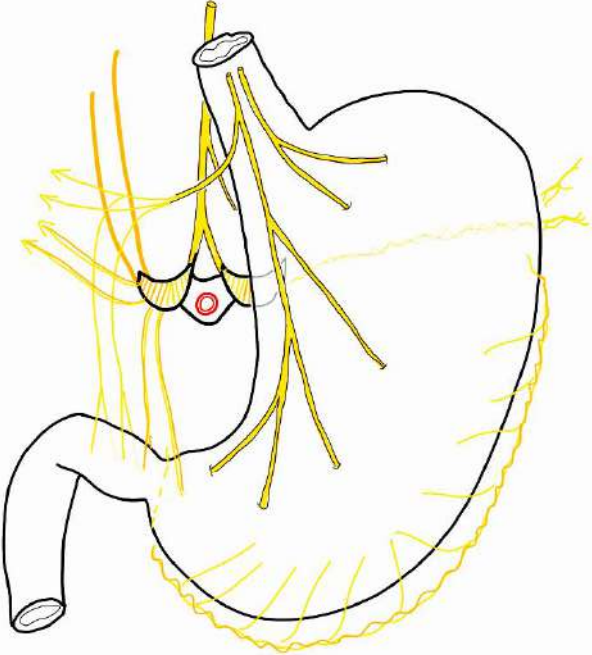
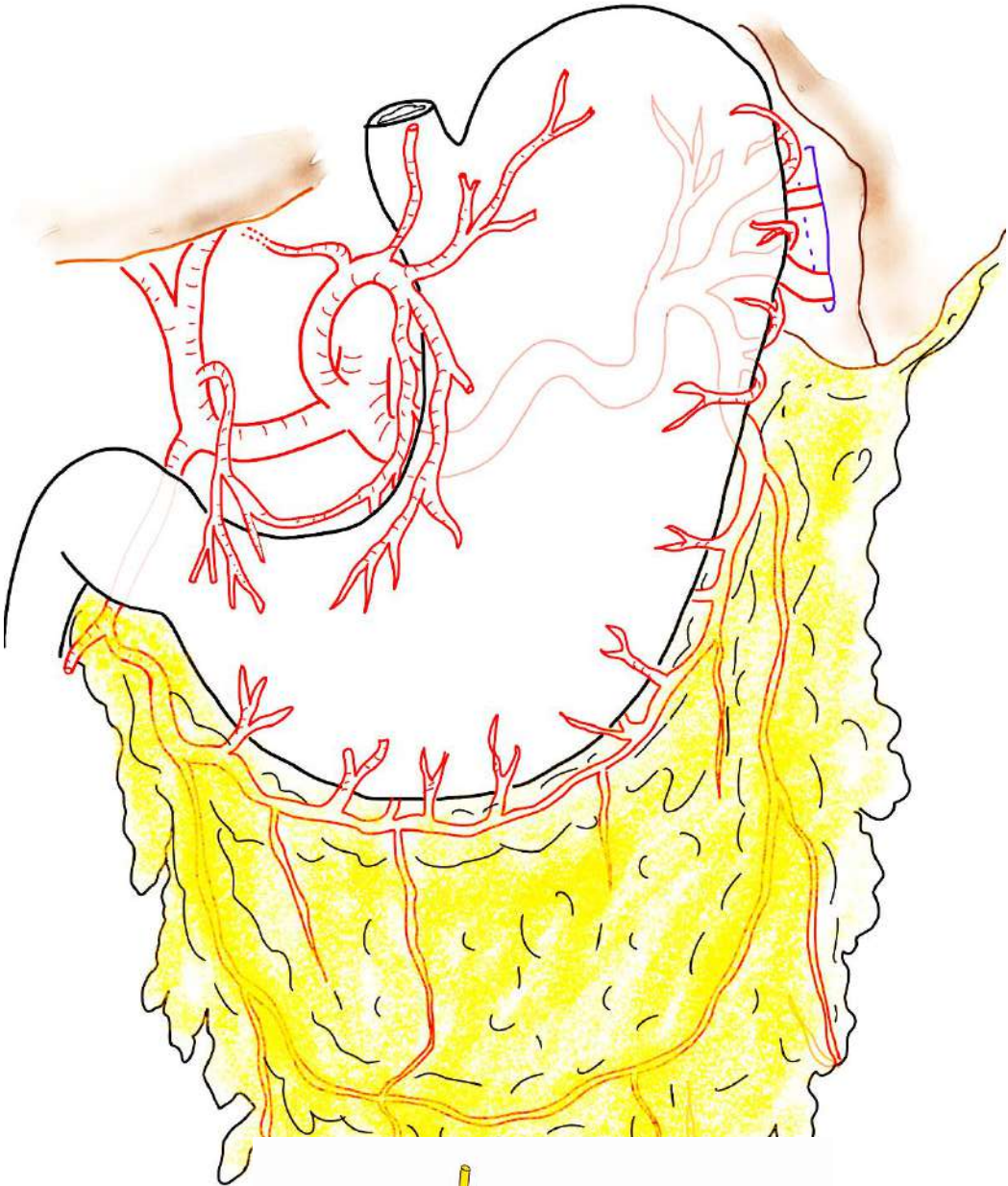
# V/ APPAREIL URINAIRE HAUT et GLANDES SURRÉNALES



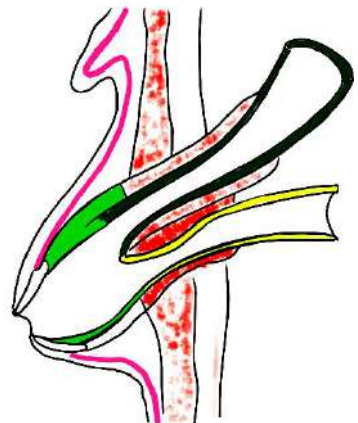
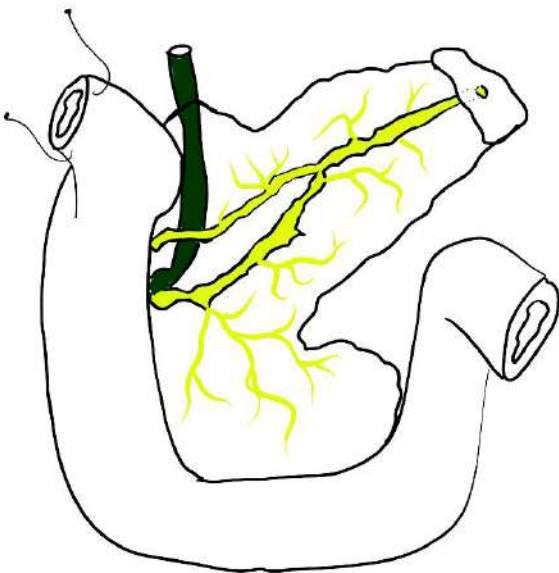
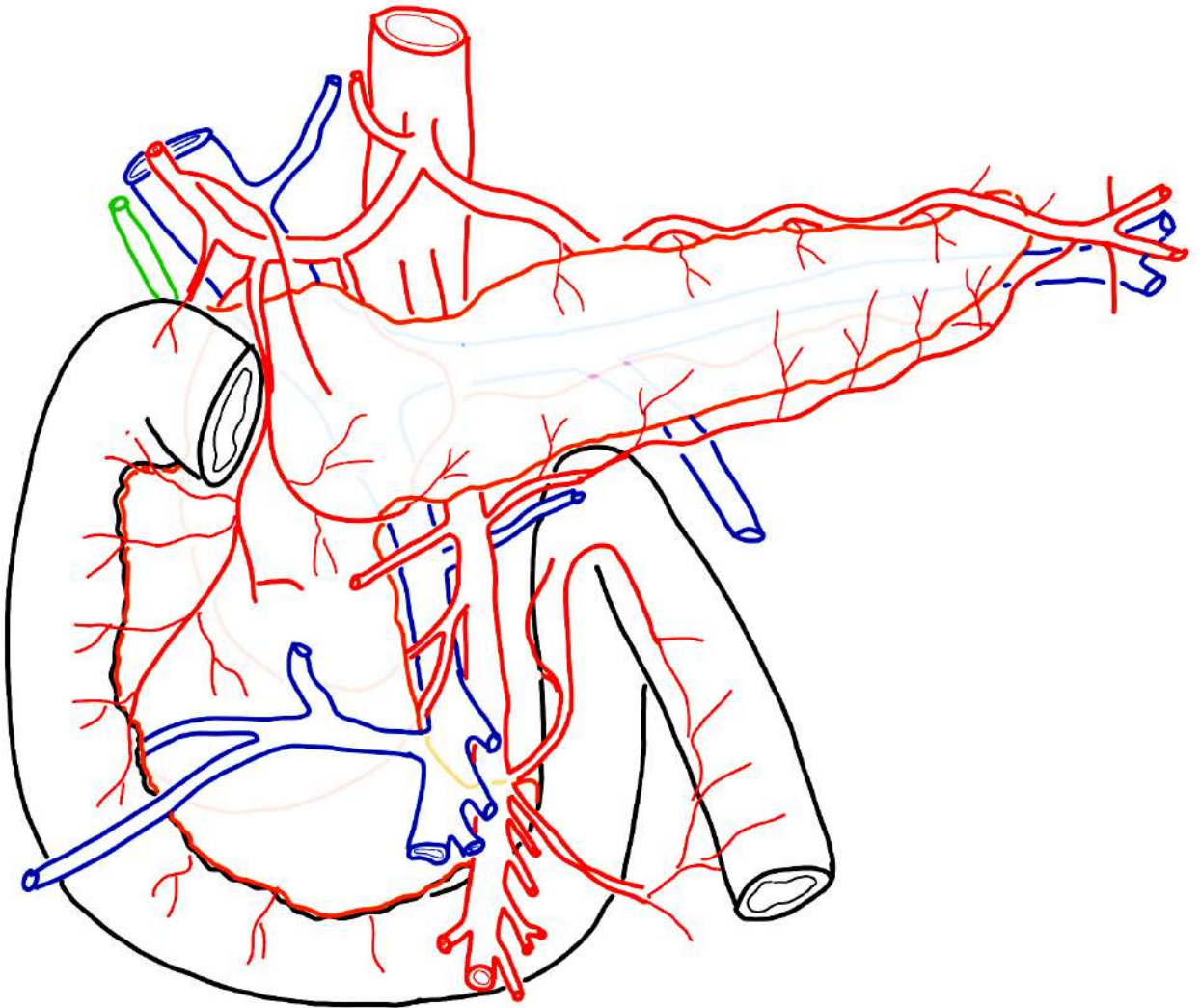
# VI/ JONCTION OESO-GASTRIQUE



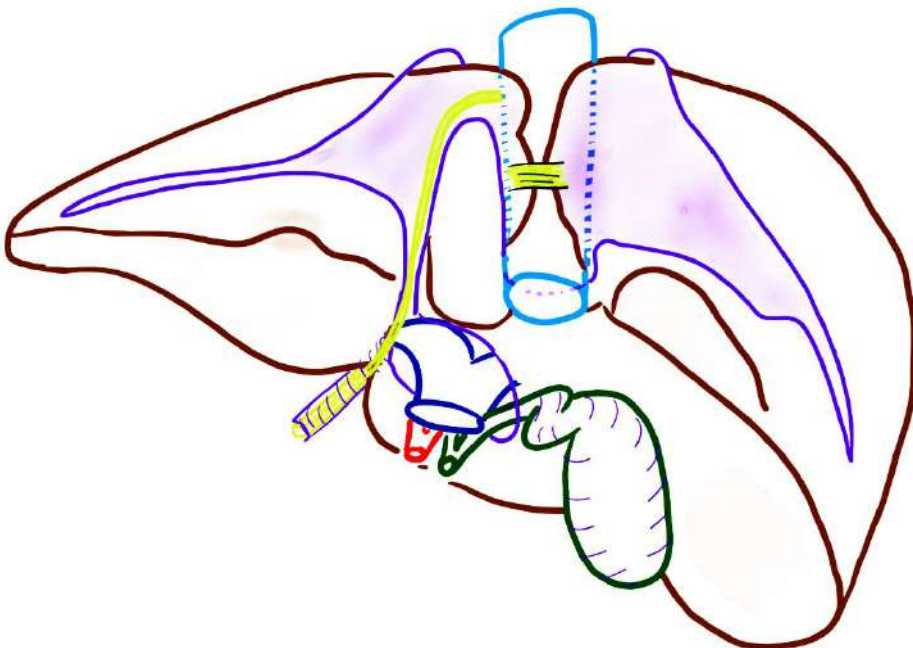
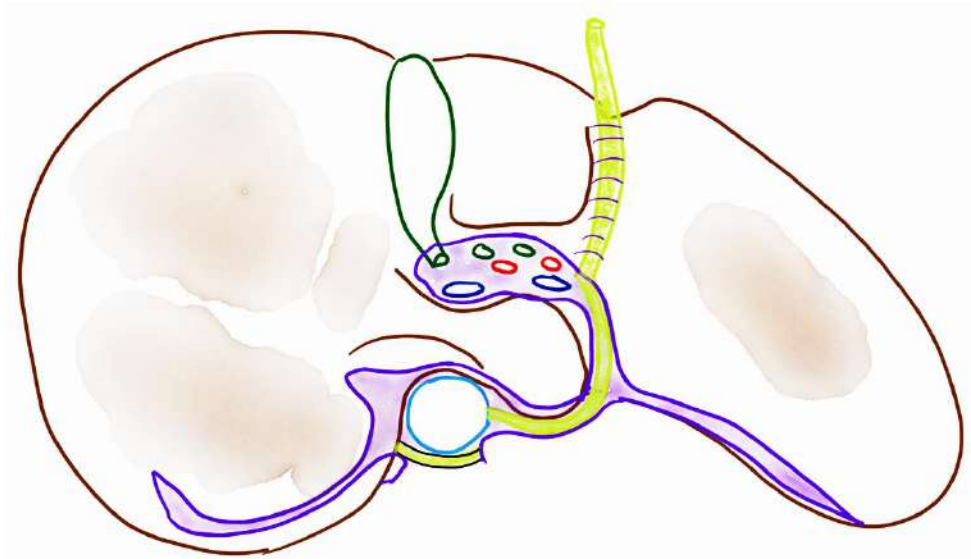
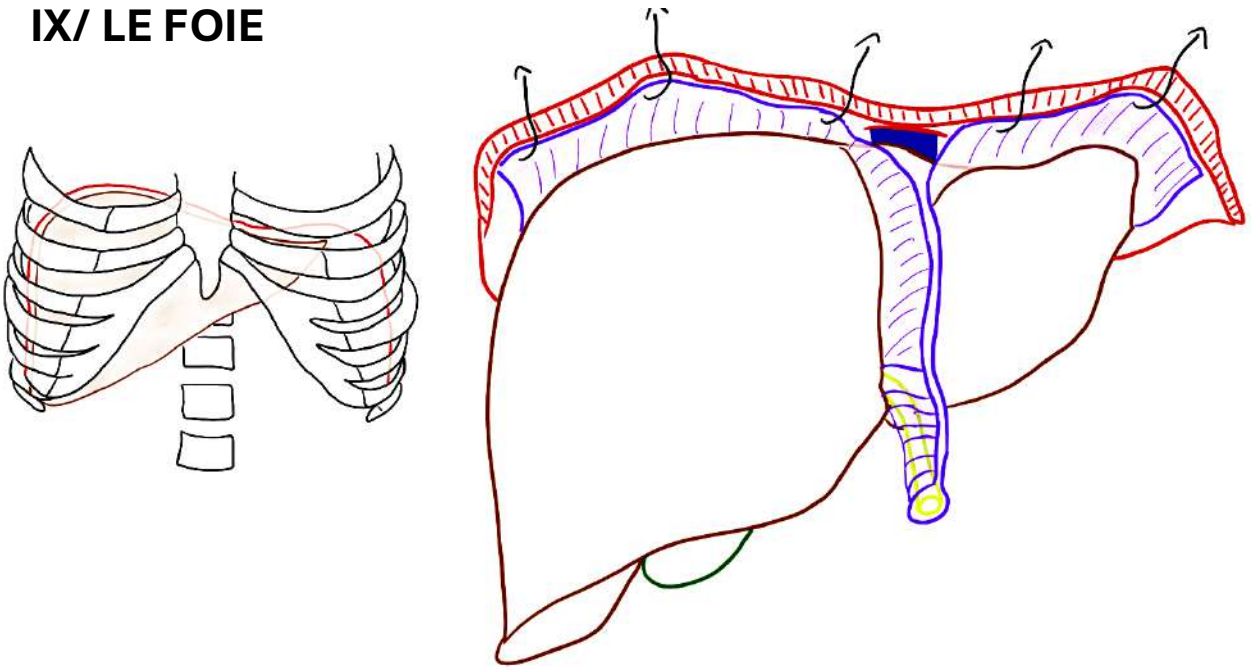
VII/ ESTOMAC



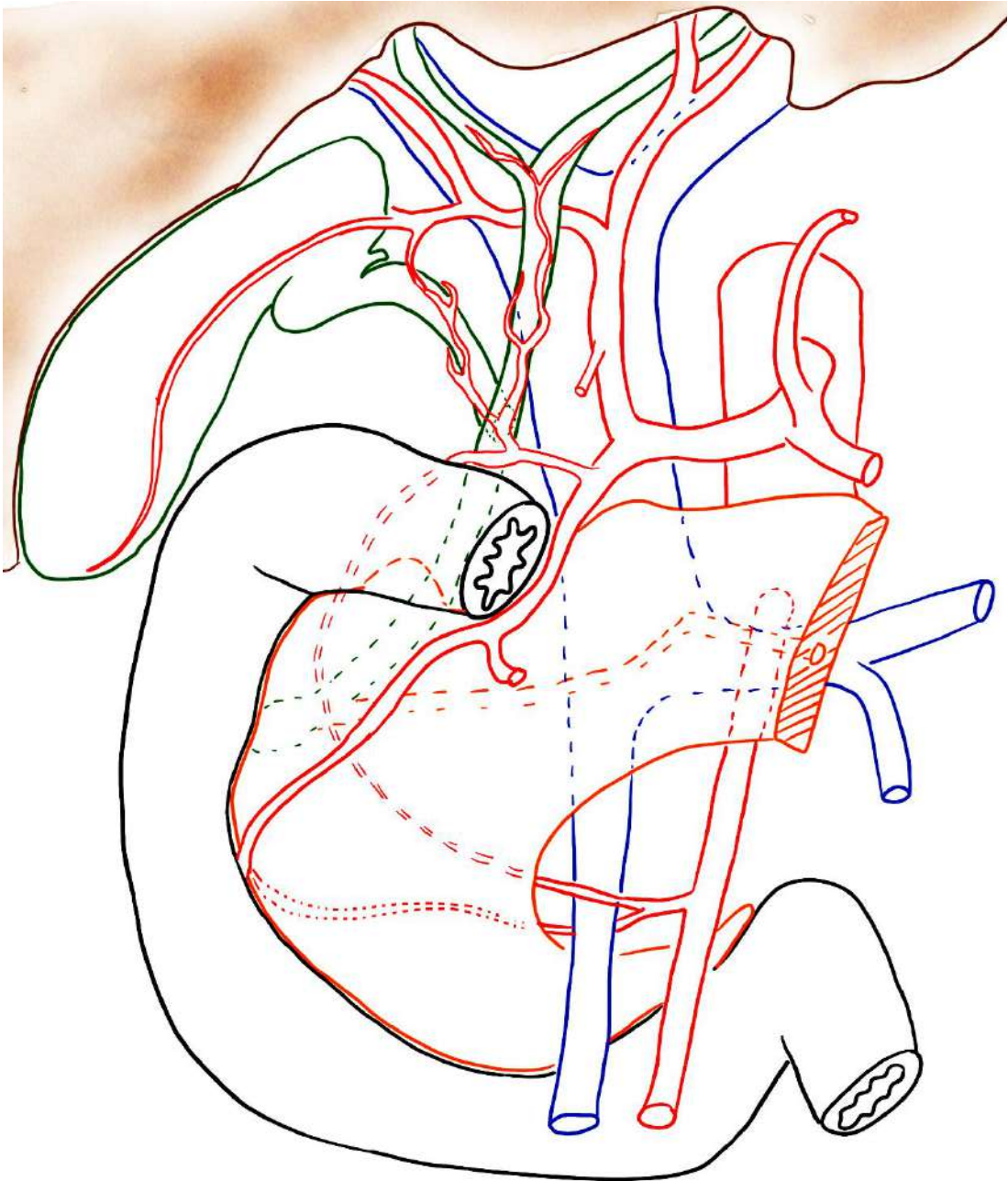
# VIII/ BLOC DUODÉNO-PANCRÉATIQUE



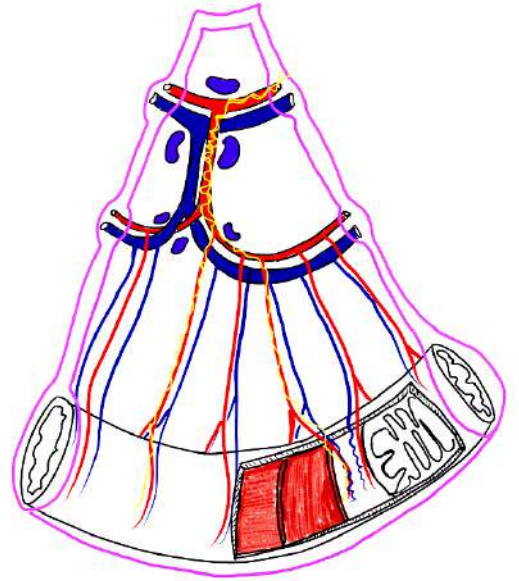
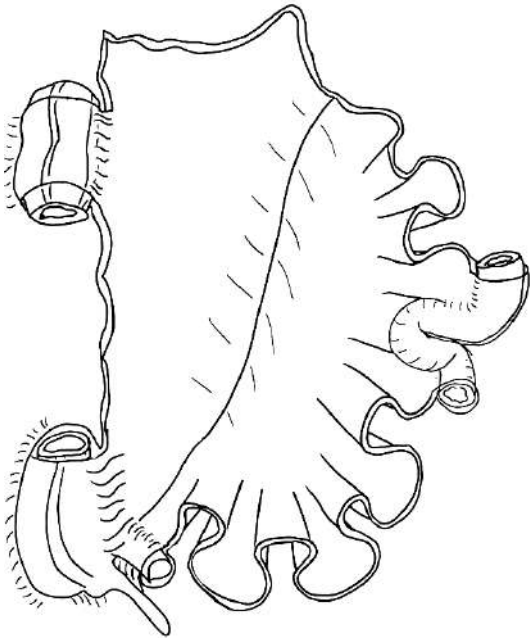
# IX/ LE FOIE



# X/ PÉDICULE HÉPATIQUE



# XI/ L'INTESTIN GRÊLE et le MÉSENTÈRE



# XII/ LA JONCTION ILÉO-CAECALE – LES COLONS

