

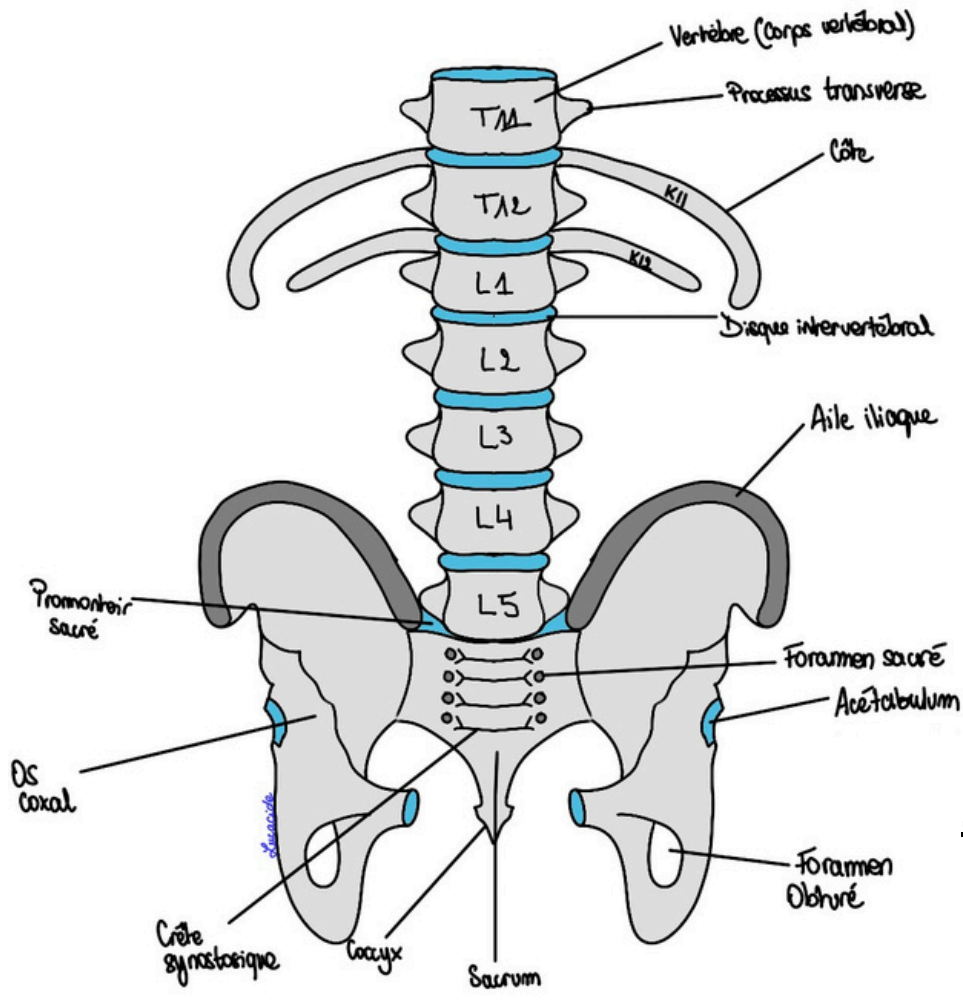Schéma 1 : Base osseuse

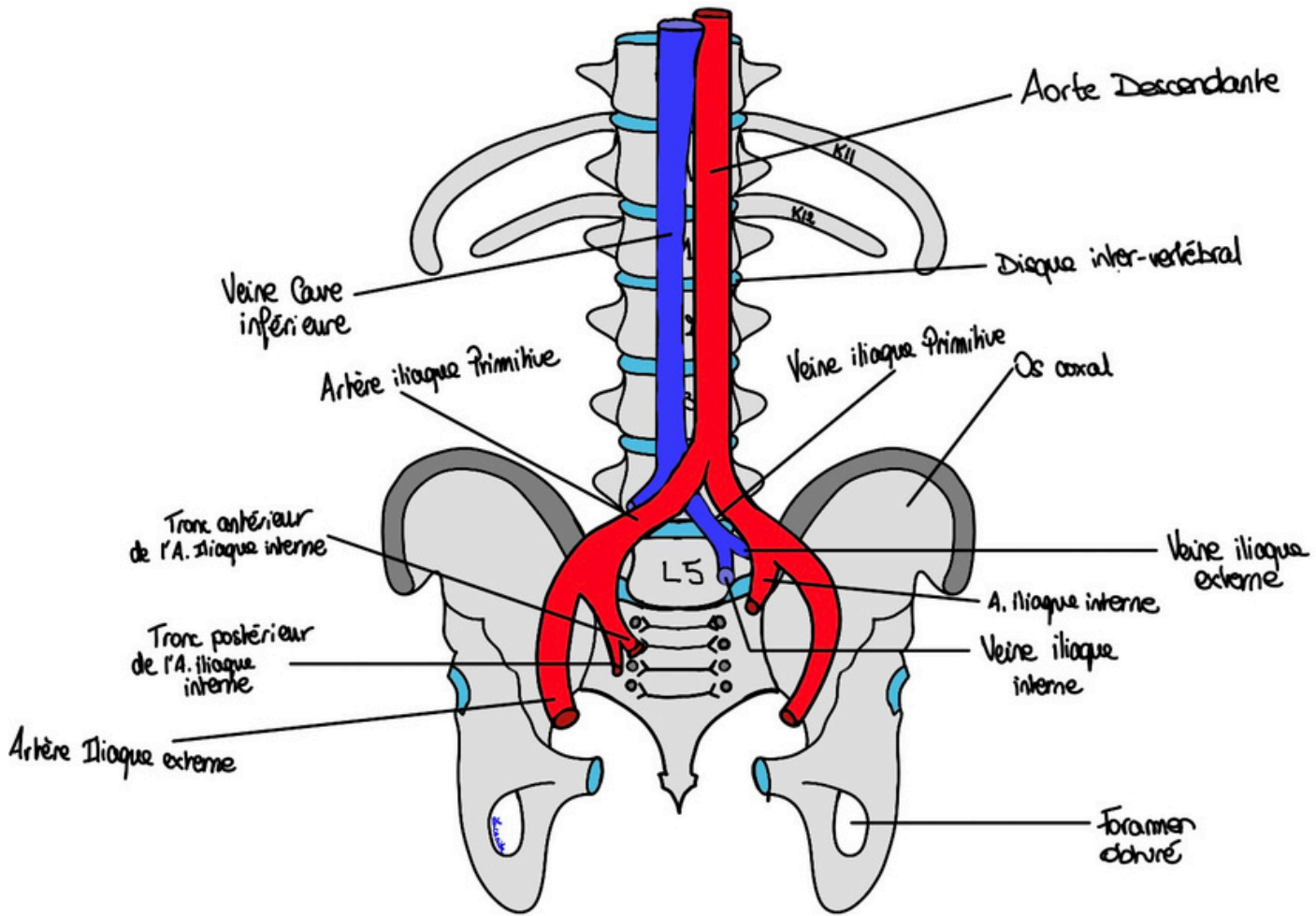


Schéma 2 : Vascularisation du Petit Bassin

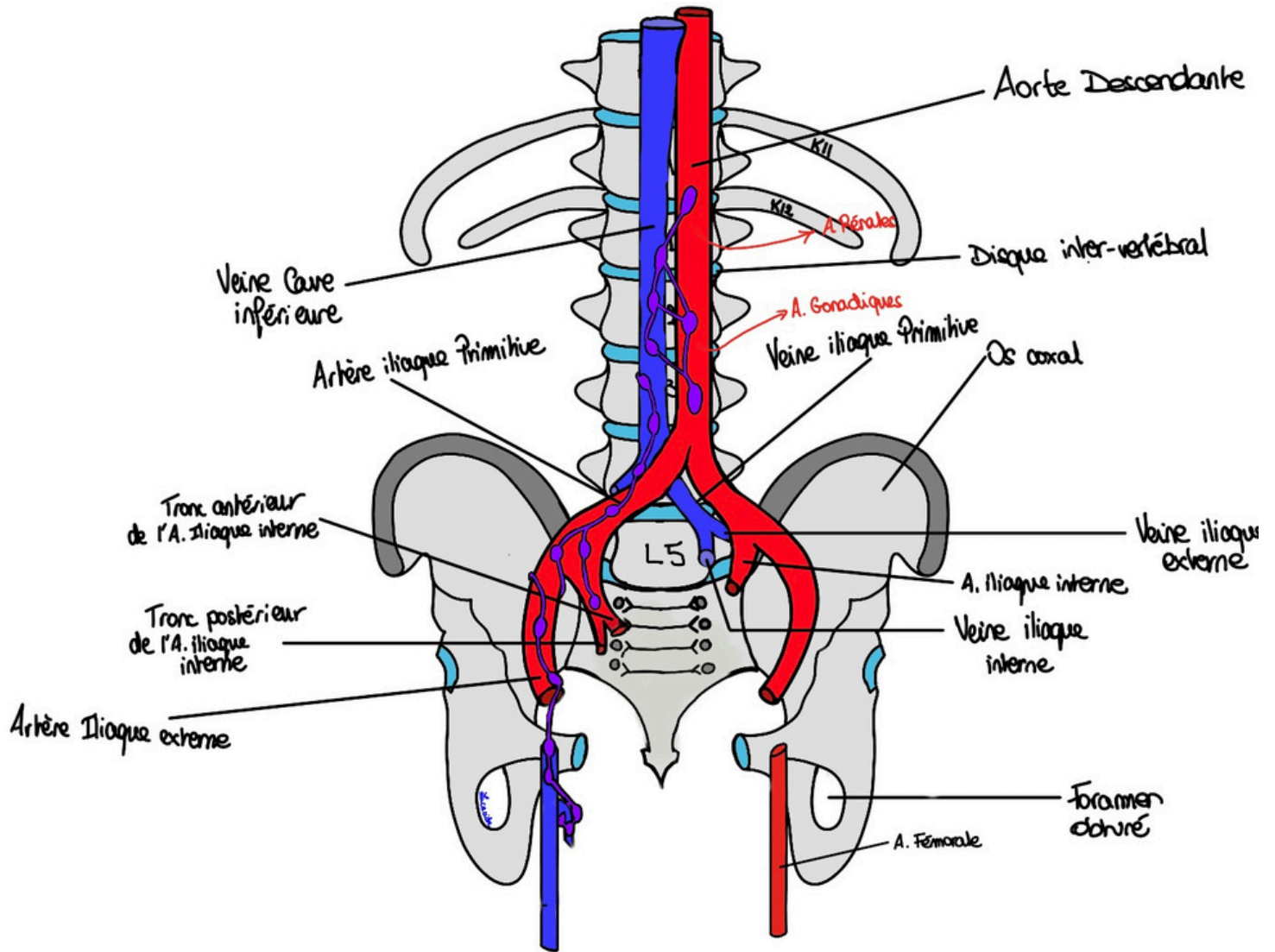


Schéma 6 : Vascularisation du Petit Bassin avec courants lymphatiques

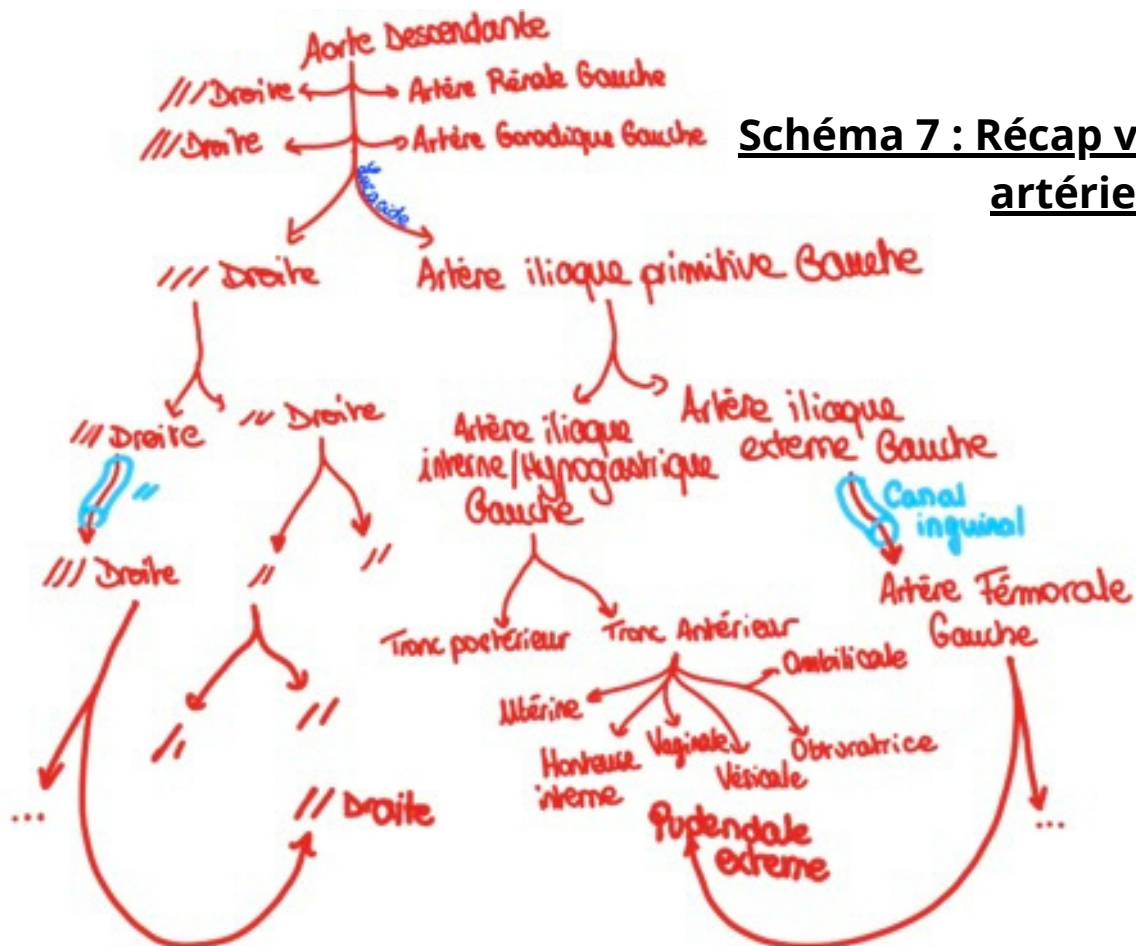


Schéma 7 : Récap vascularisation artérielle

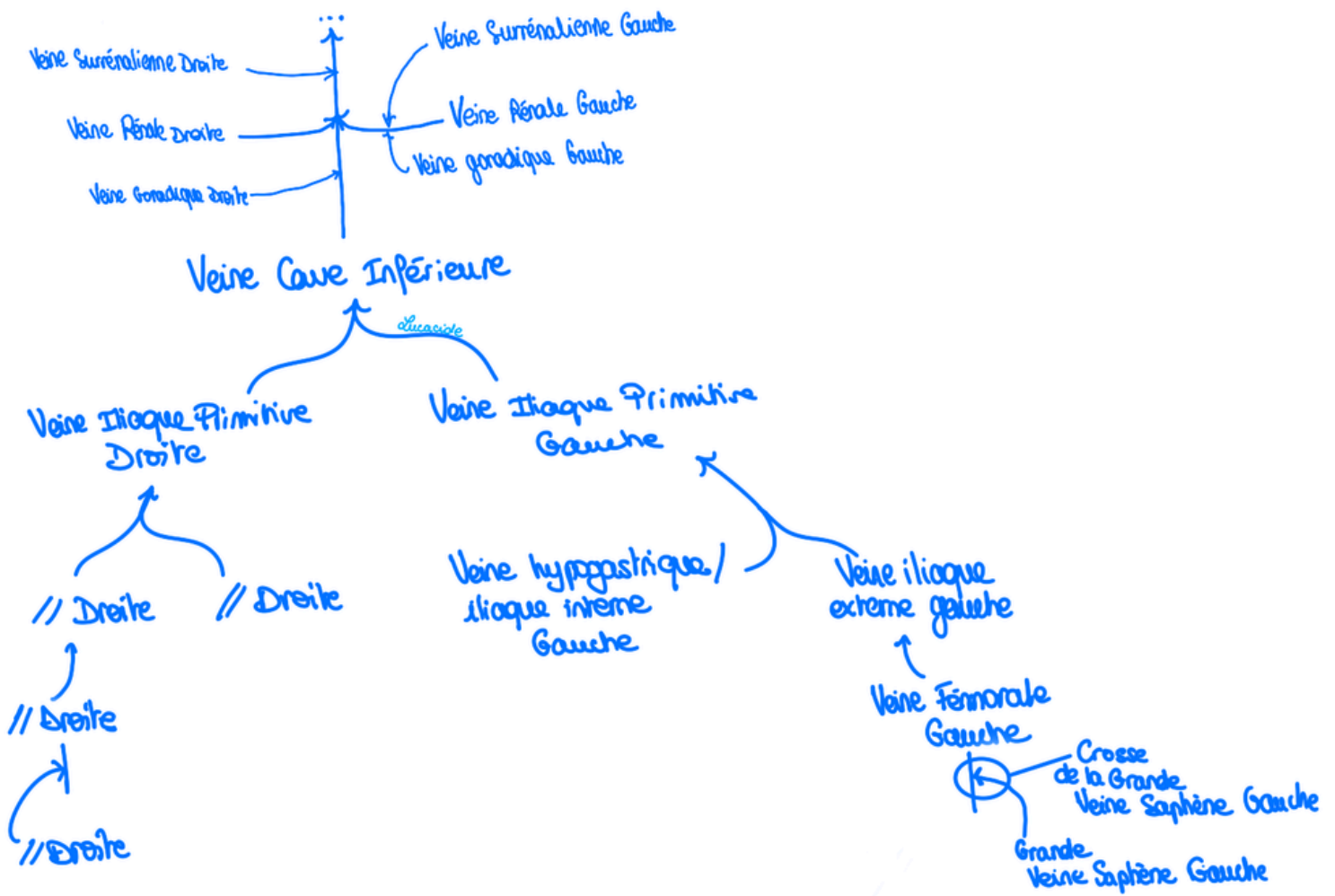


Schéma 8 : Récap vascularisation veineuse

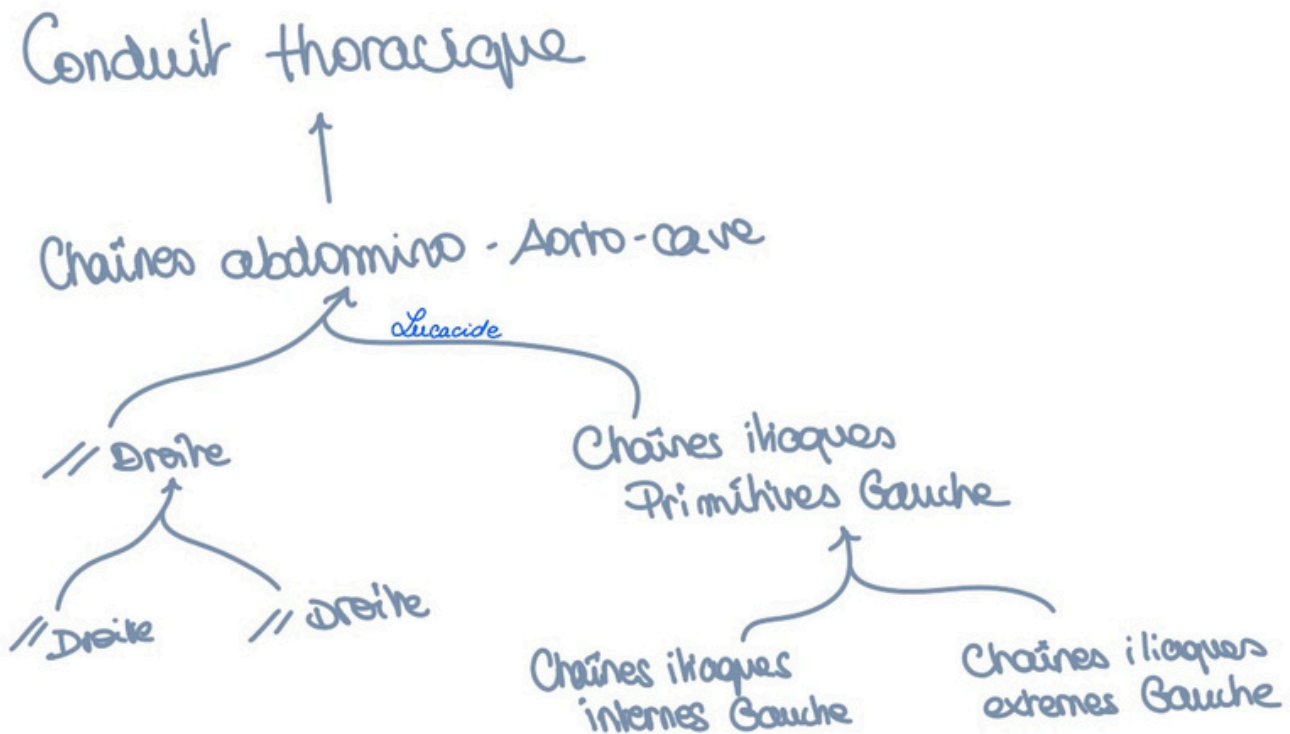


Schéma 9 : Récap courants de drainage lymphatiques

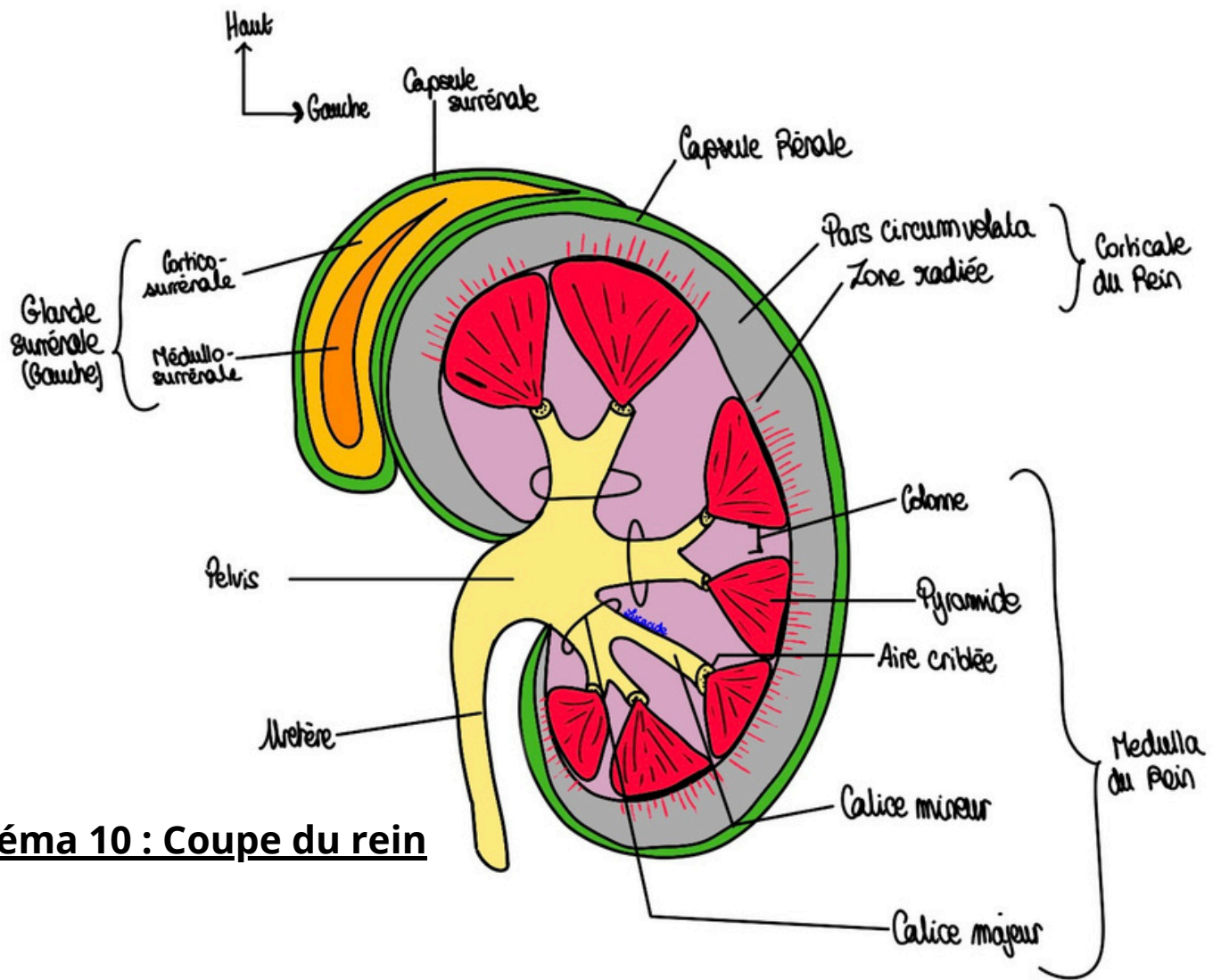


Schéma 10 : Coupe du rein

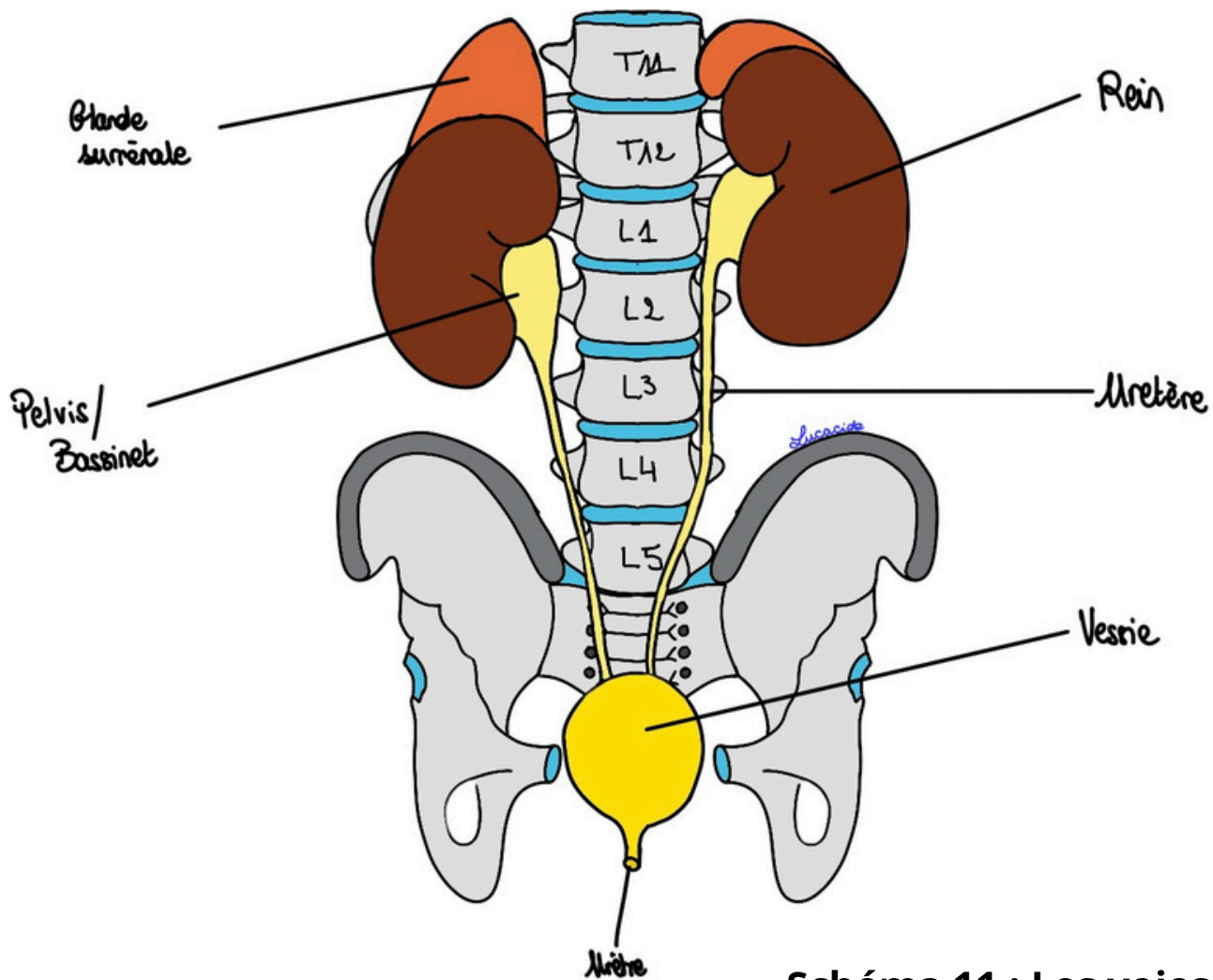


Schéma 11 : Les voies urinaires

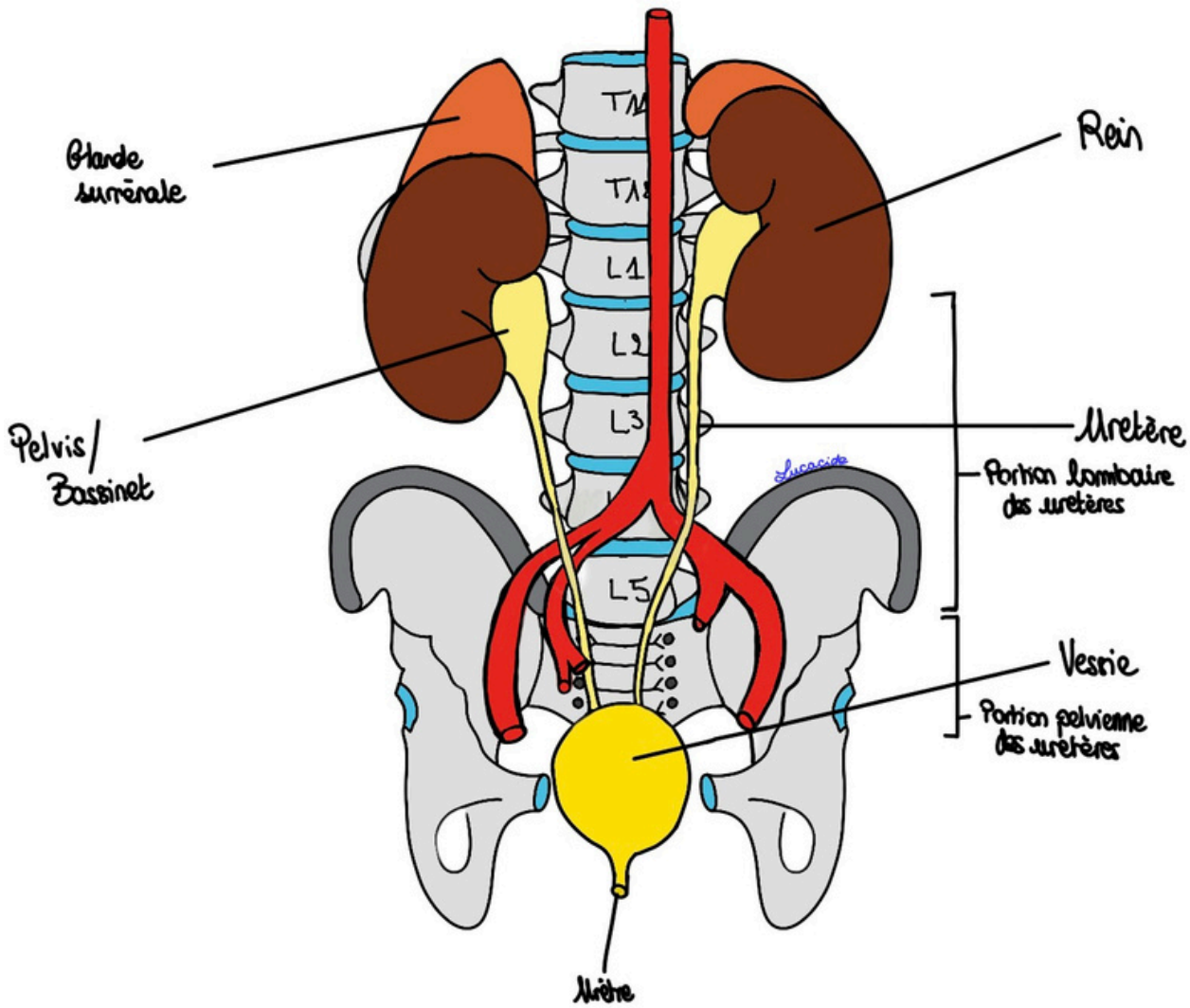
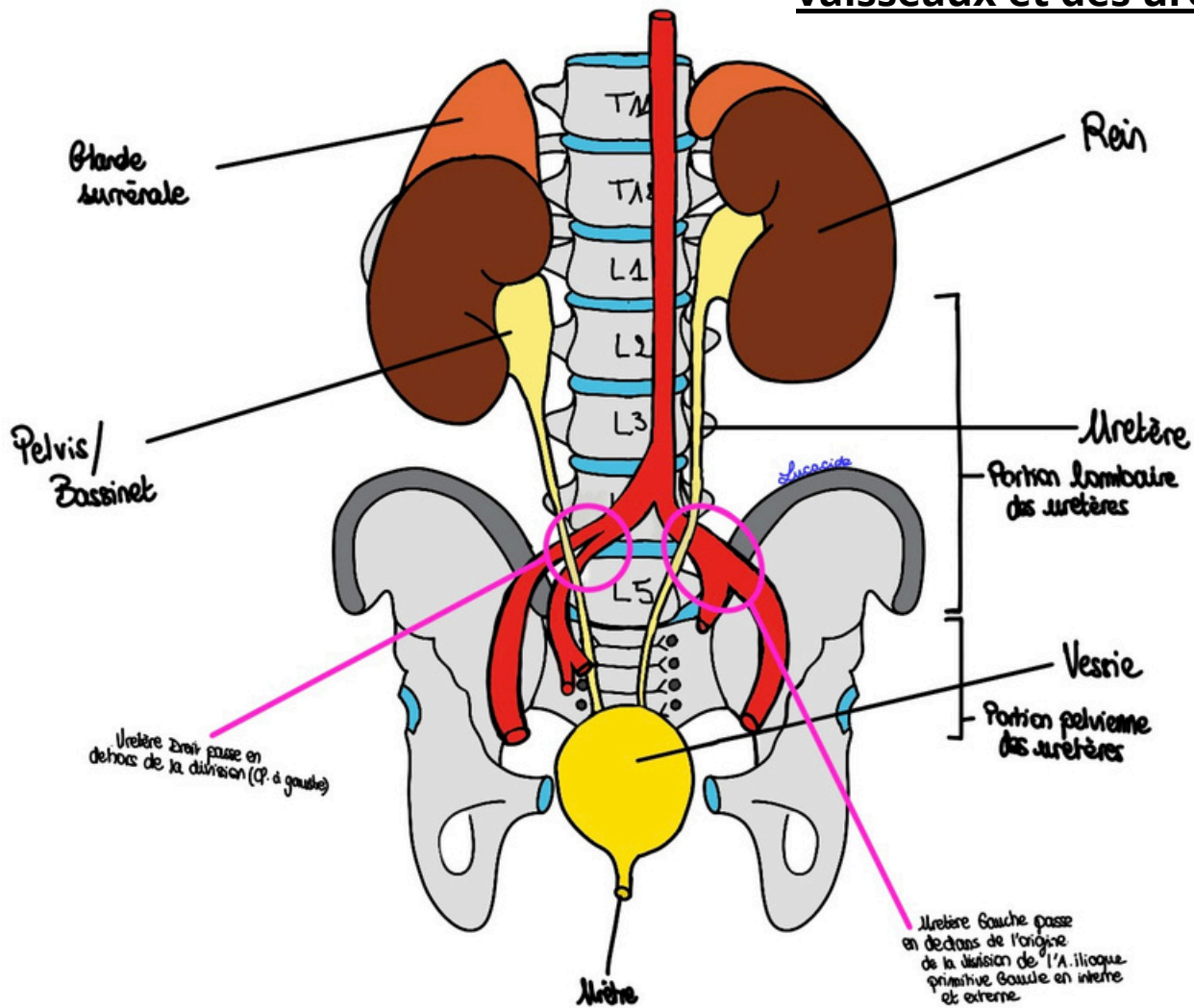


Schéma 12 et 13 : Croisement des vaisseaux et des urètres



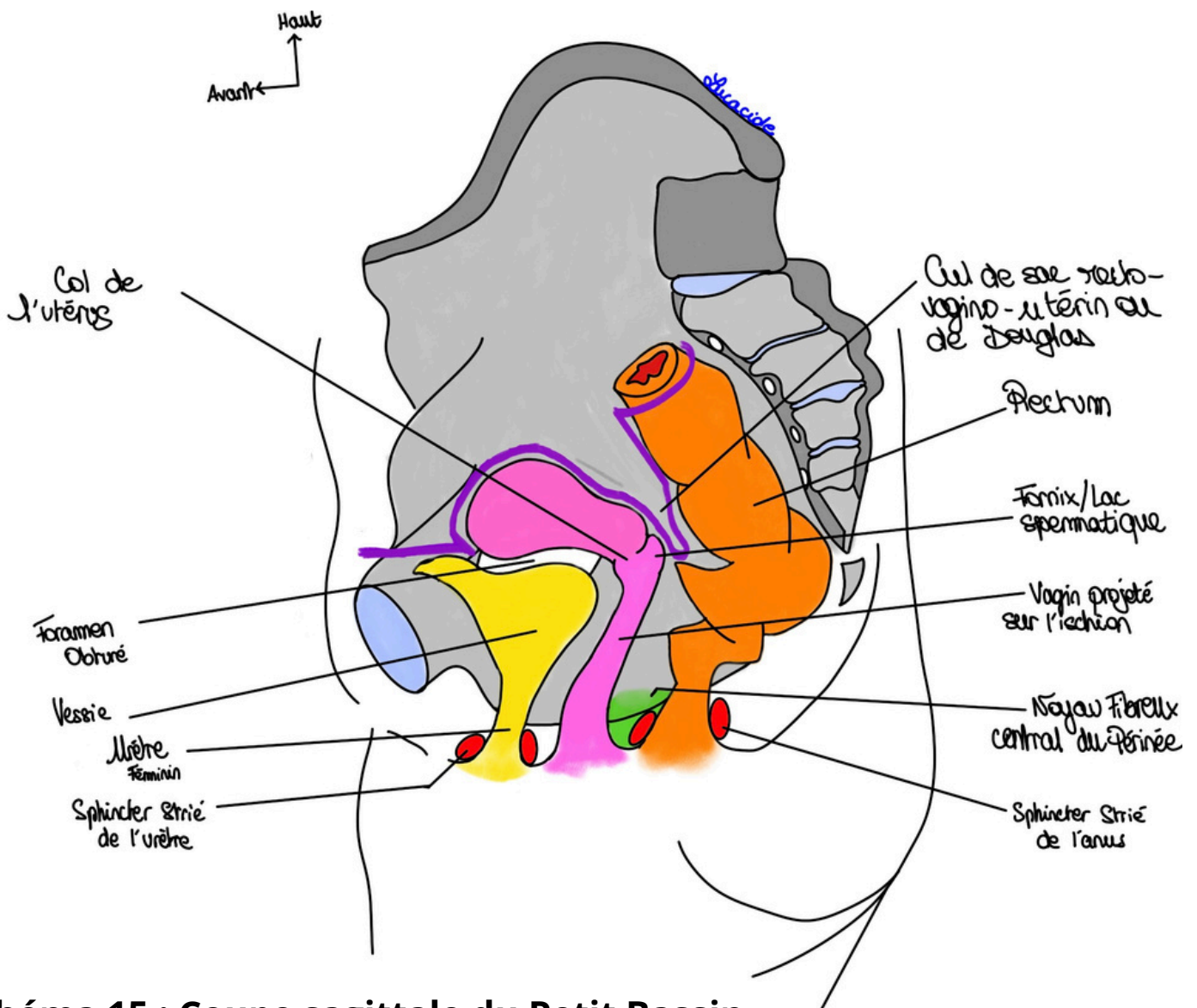
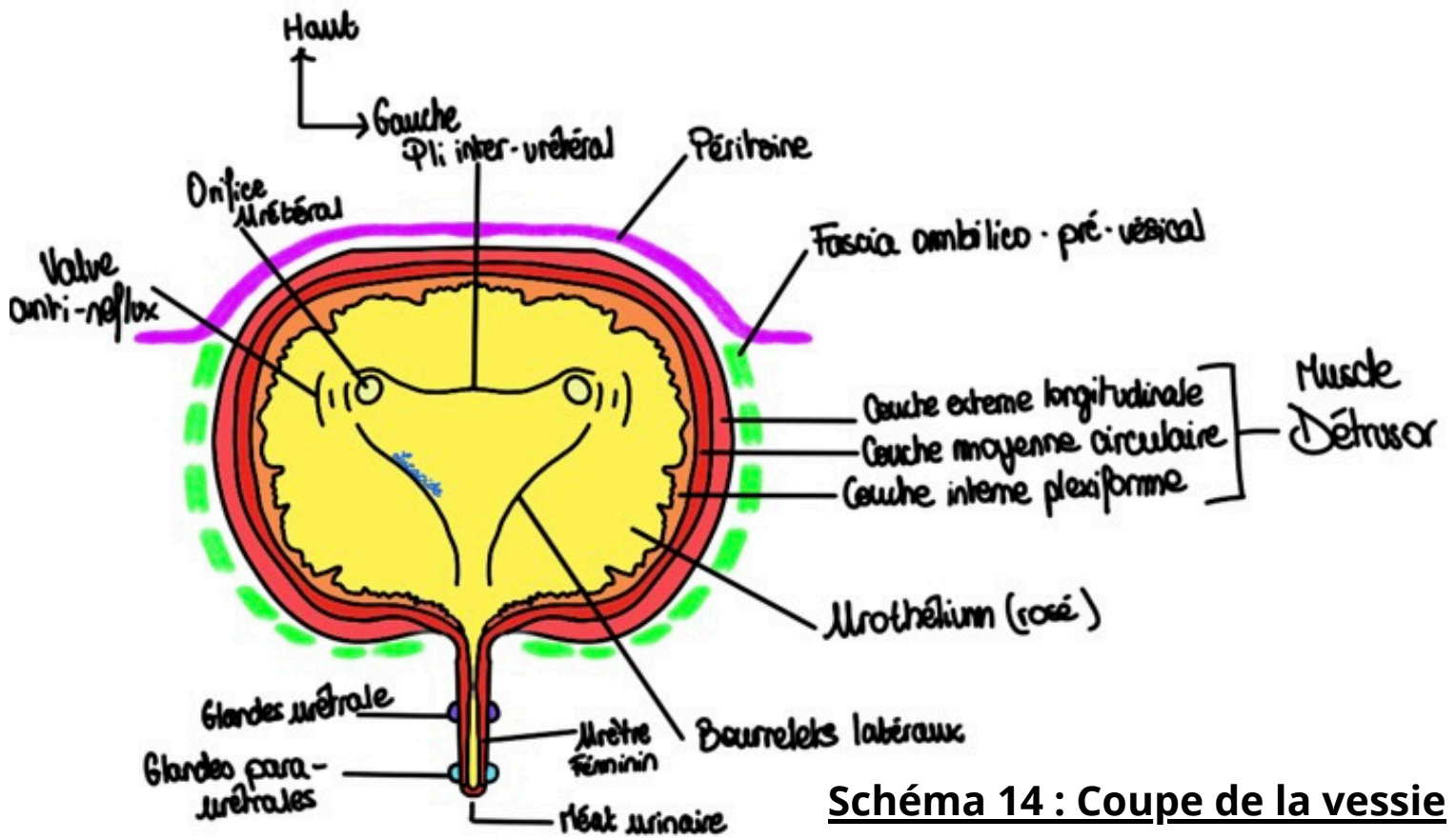


Schéma 15 : Coupe sagittale du Petit Bassin de la femme

Haut
 Avant ←

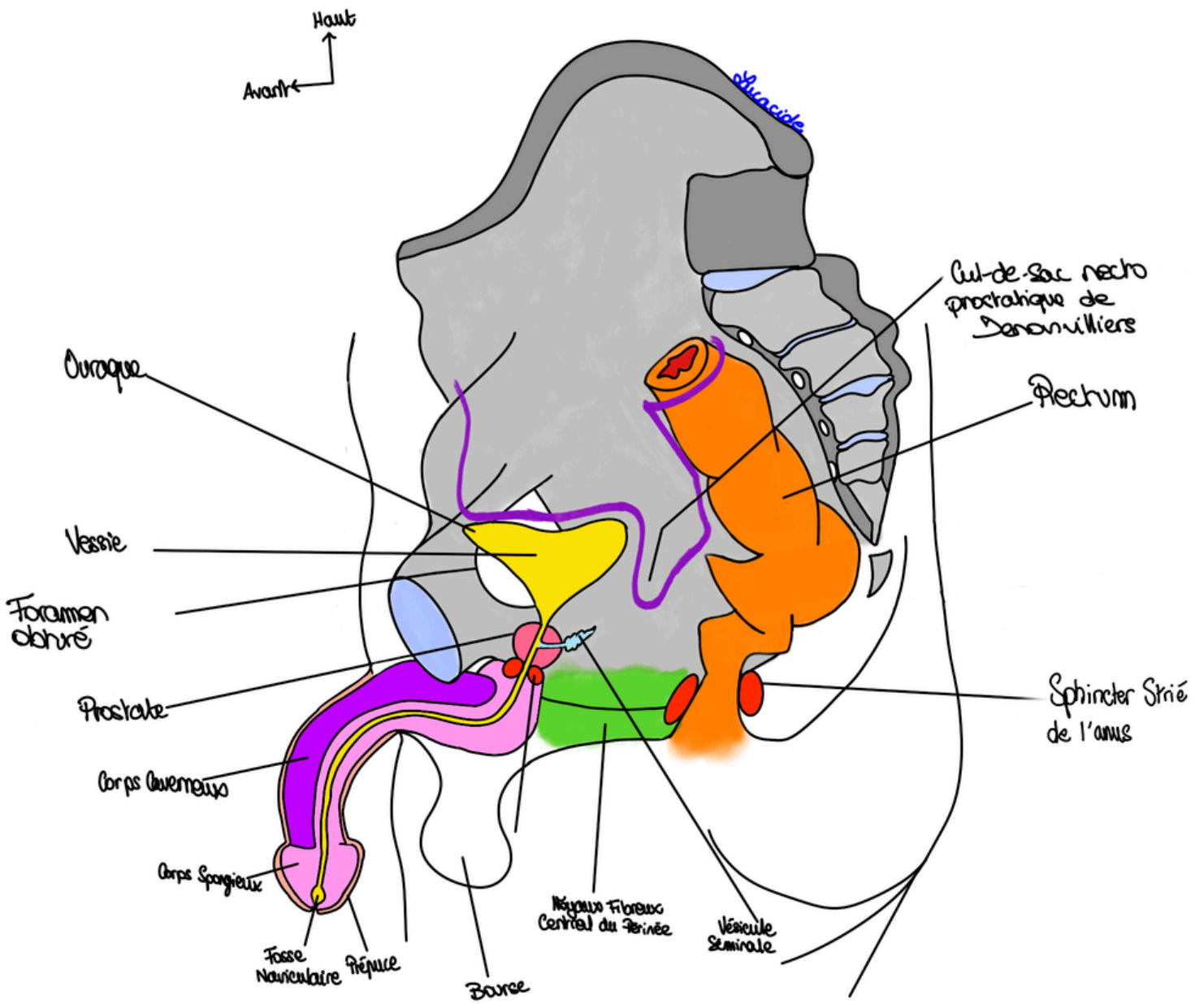


Schéma 16 : Coupe sagittale du Petit Bassin de l'homme

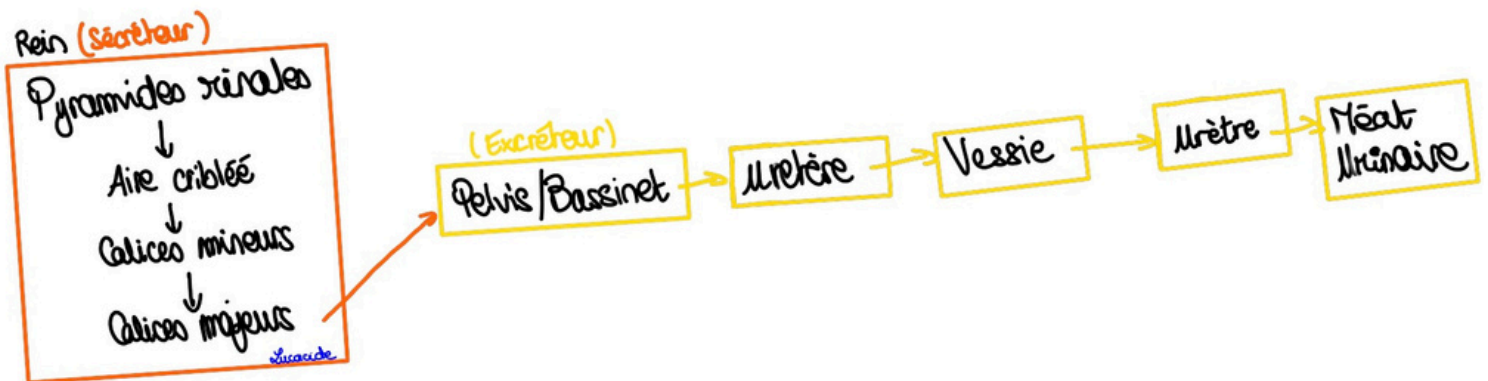


Schéma 17 : Récap des voies urinaires