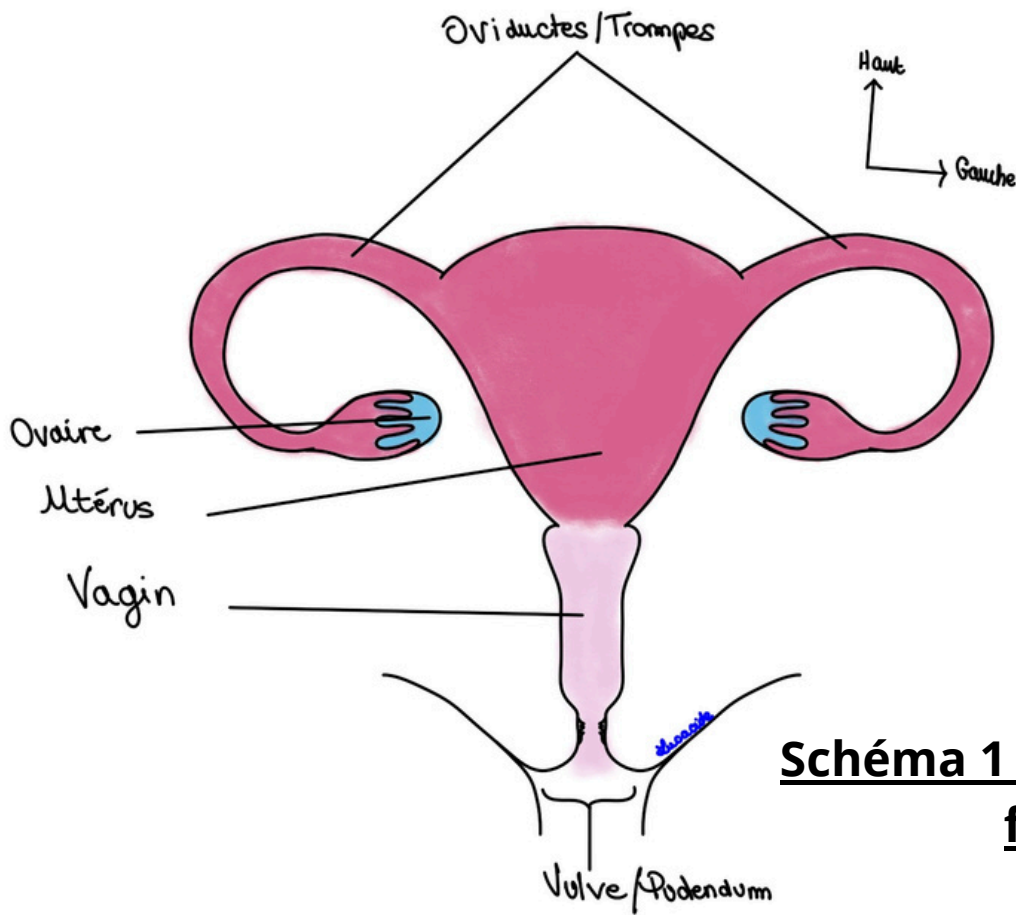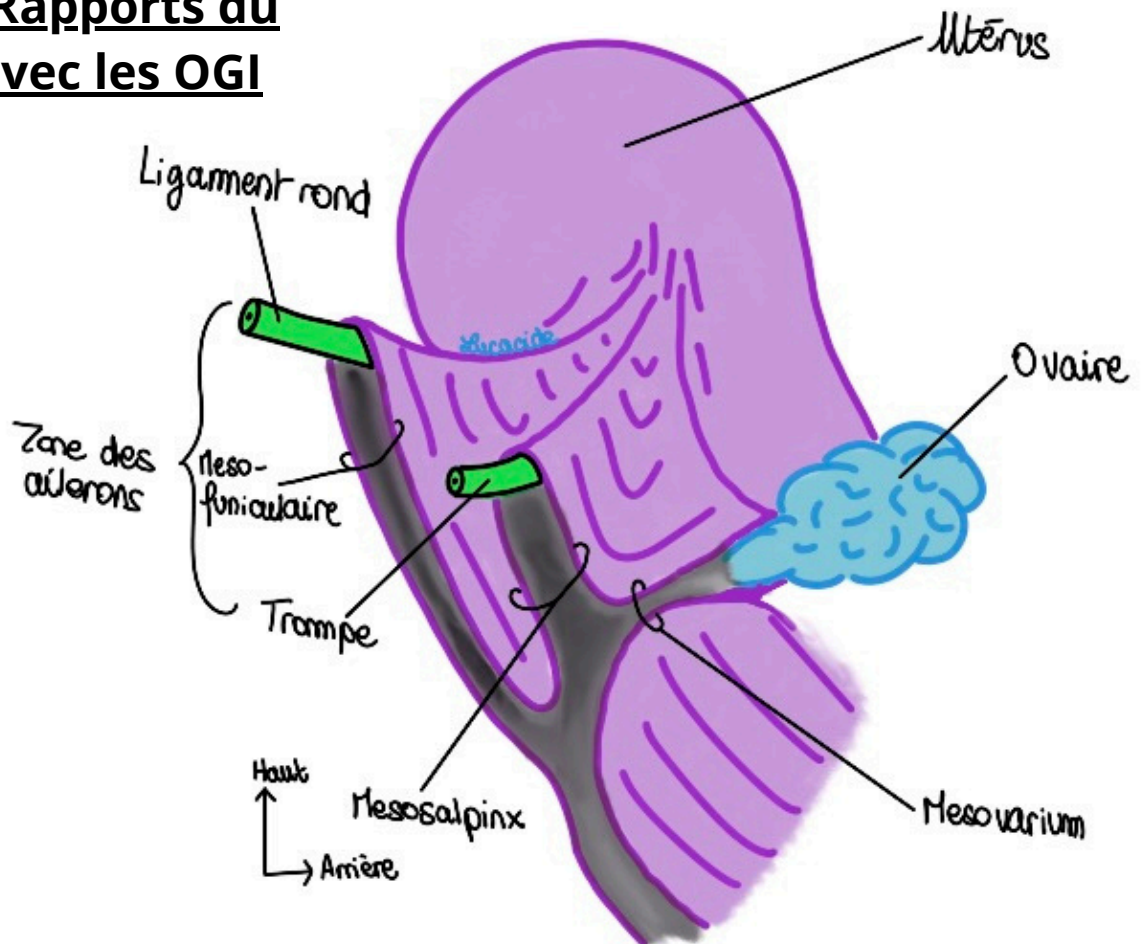


Schéma 1 : Appareil génital féminin

Schéma 2 : Rapports du Péritoine avec les OGI



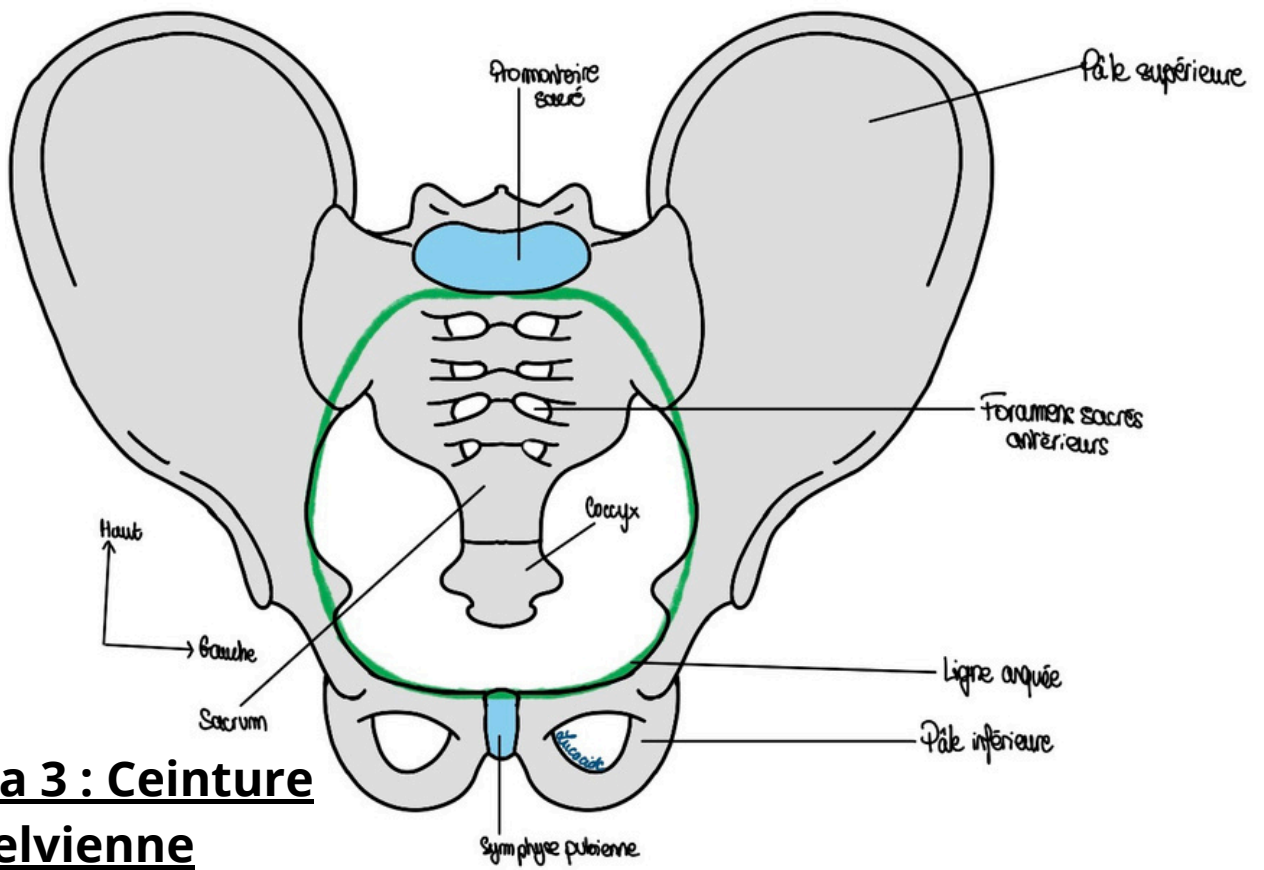


Schéma 3 : Ceinture pelvienne

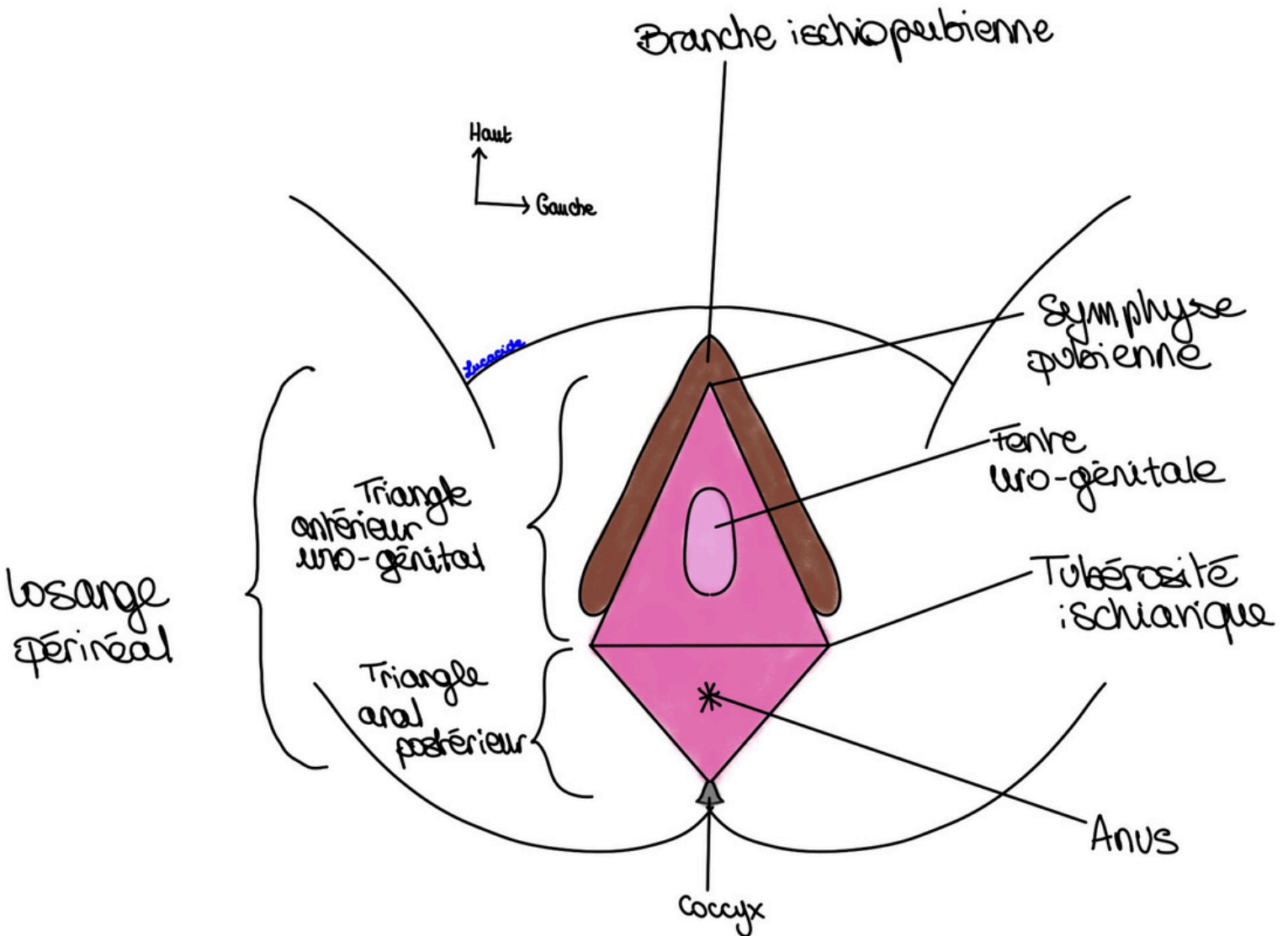


Schéma 4 : Vision schématique des OGE

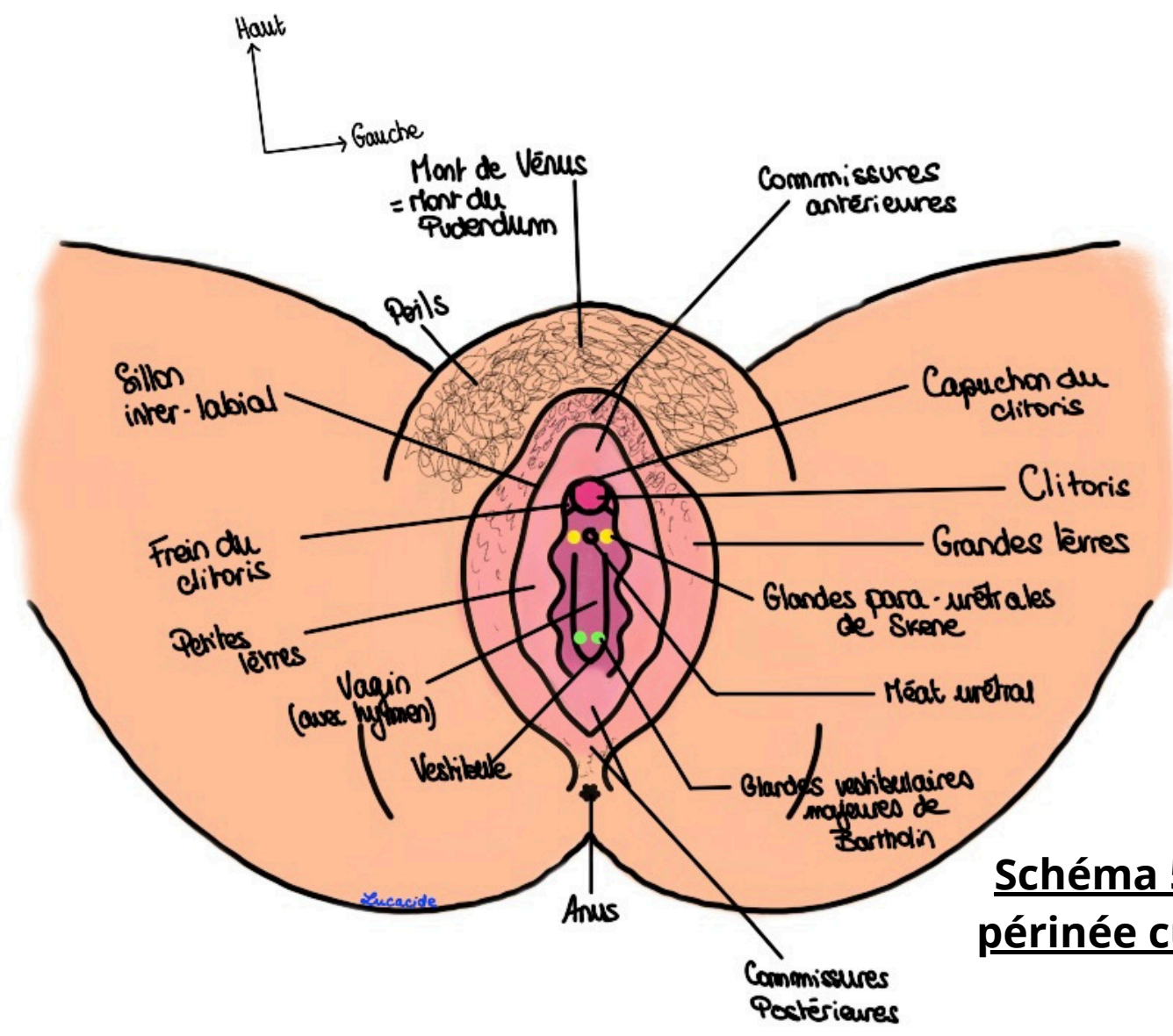




Schéma 5 : Le périnée cutané

Schéma 6 : Les différentes formes d'hymen


Hymen vierge



Hymen après pénétration



Hymen après accouchement



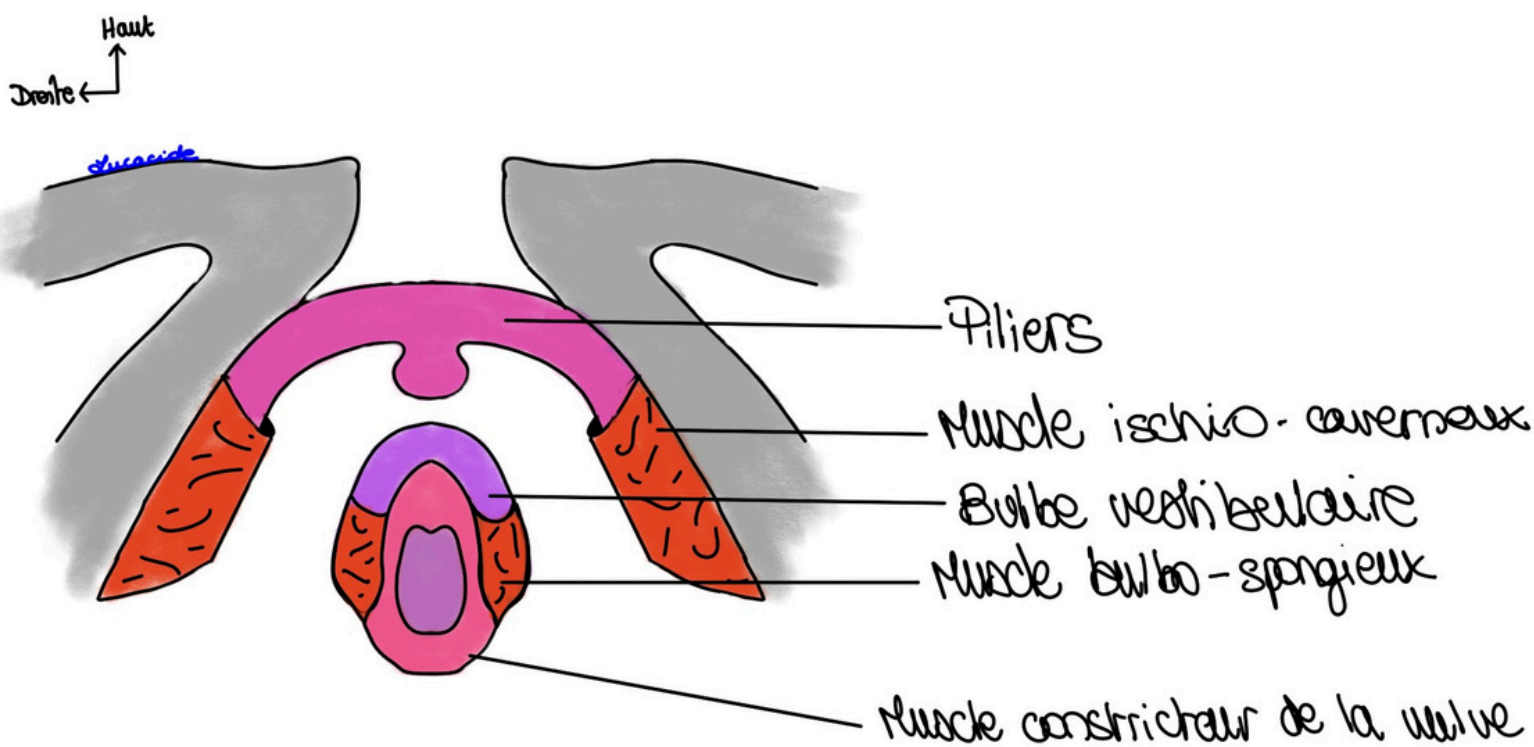


Schéma 7 : Les corps érectiles et leurs muscles en cornets

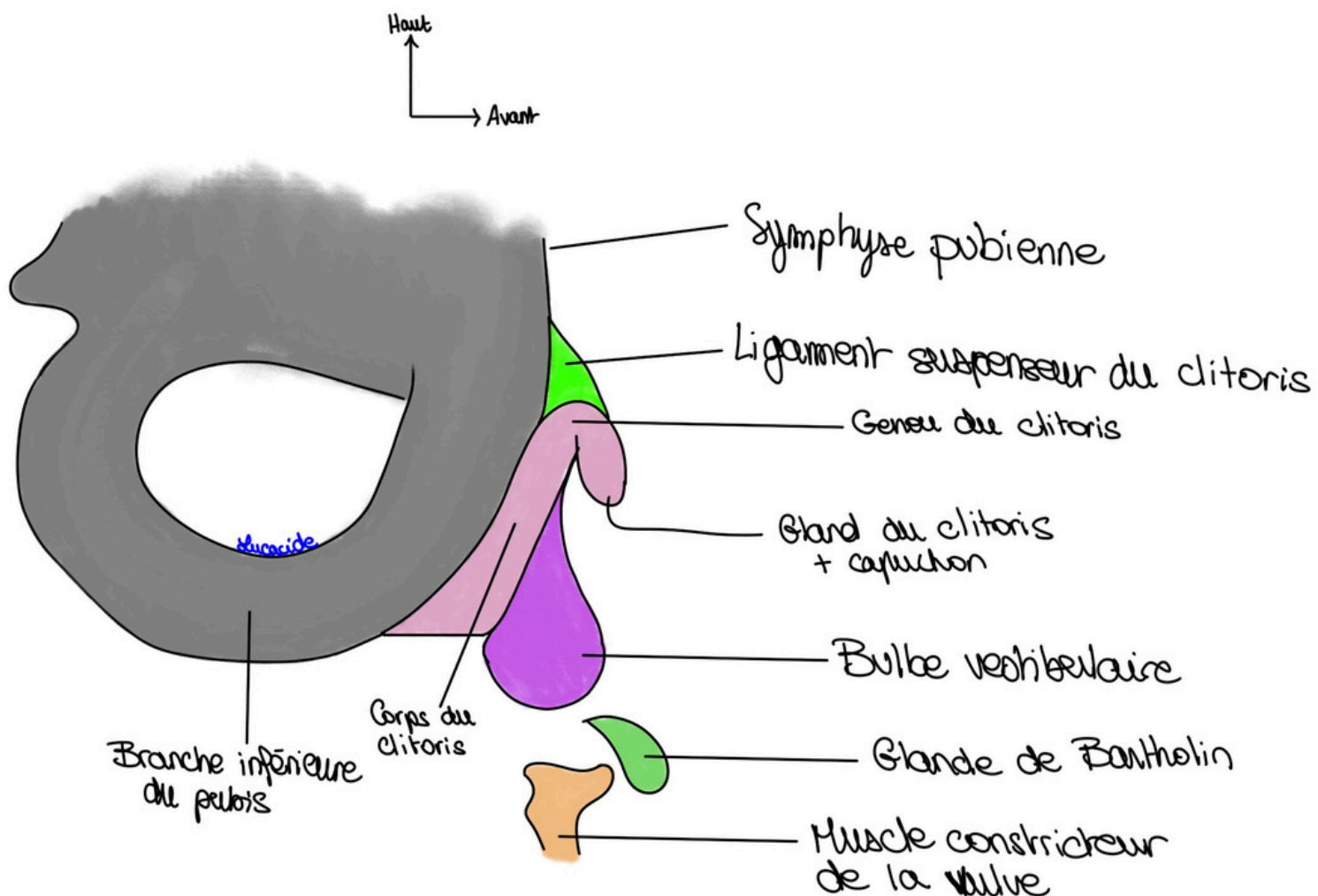


Schéma 8 : Les corps érectiles en vue de profil

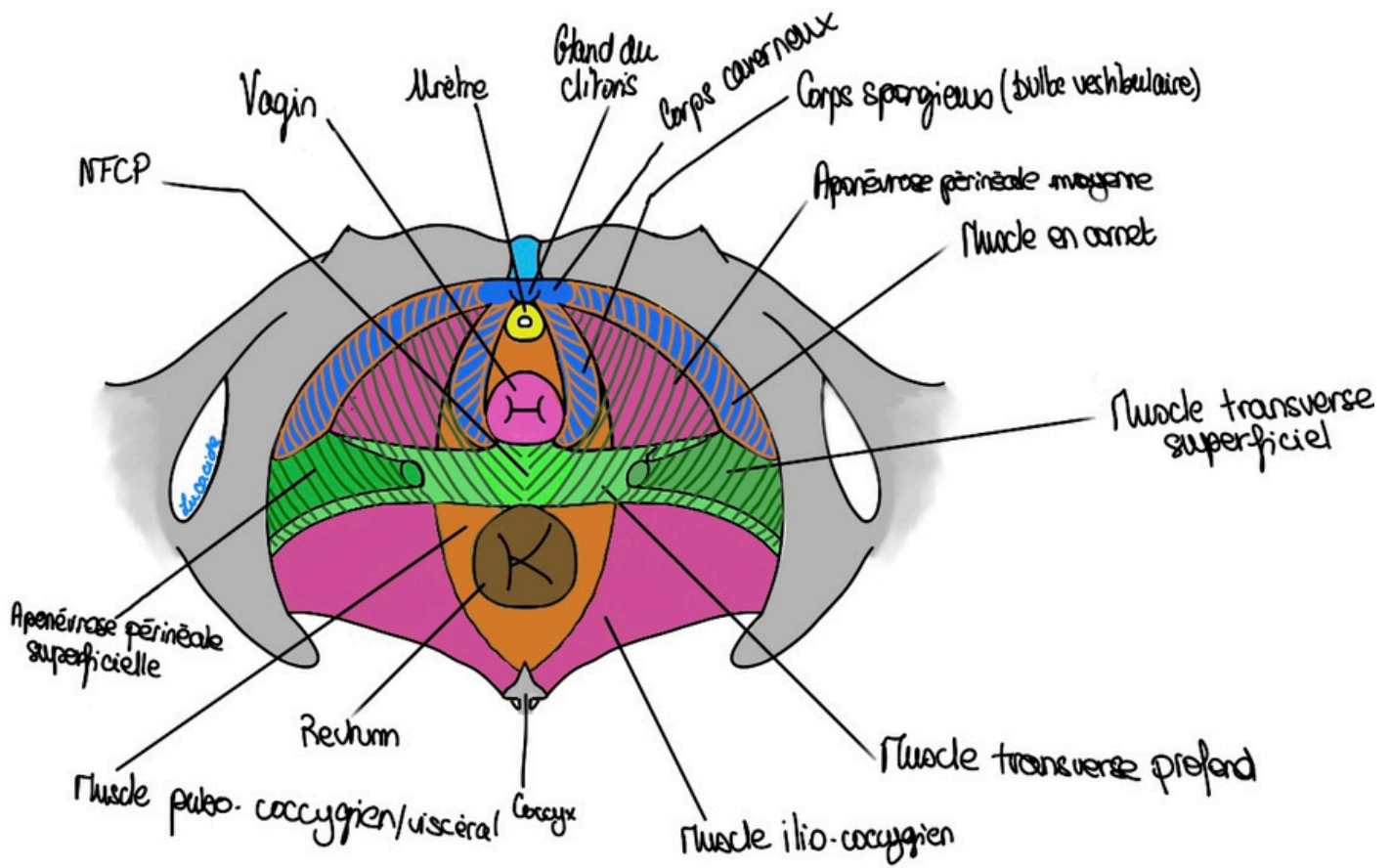


Schéma 9 : Plancher pelvien et corps érectiles

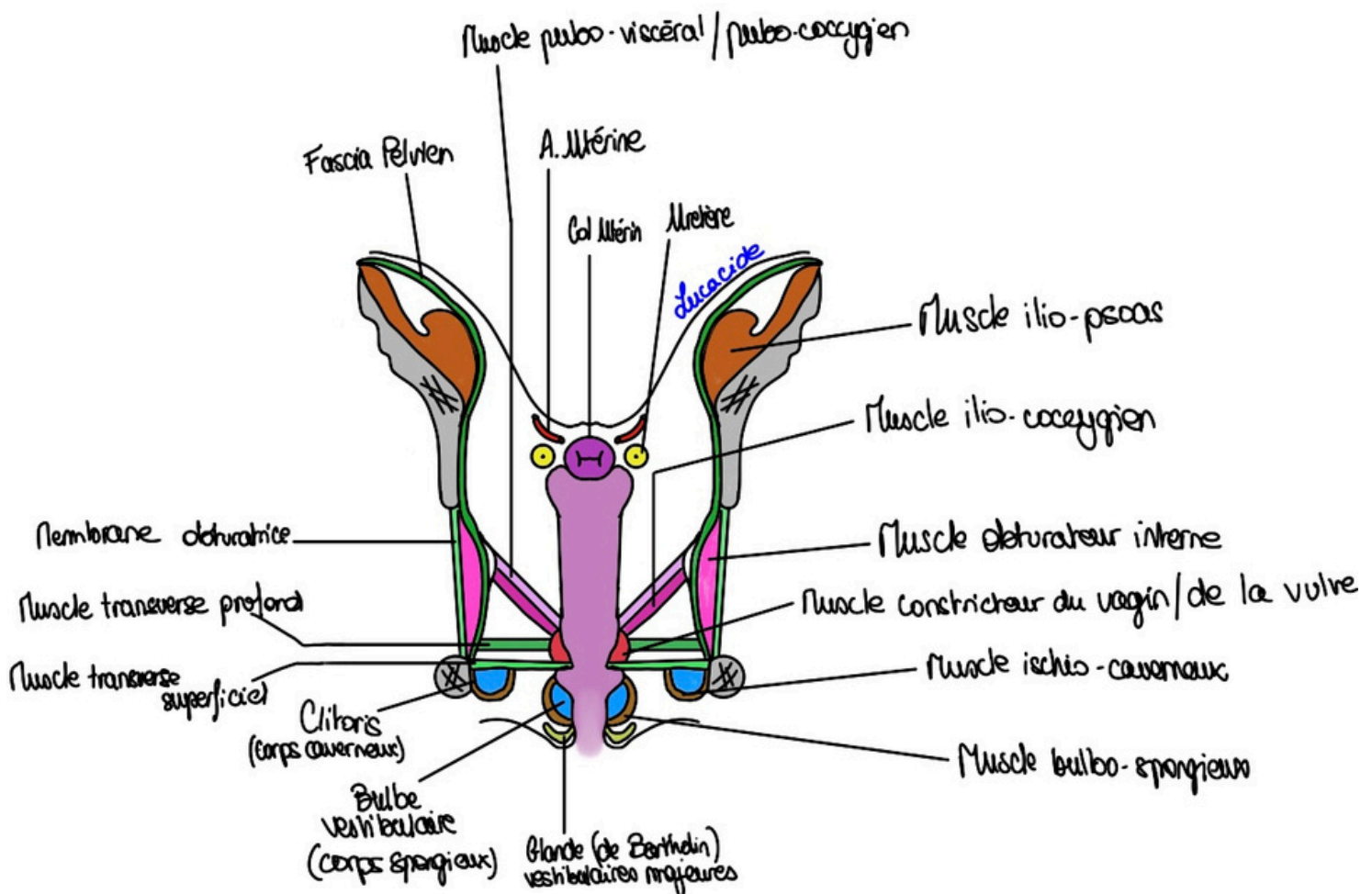


Schéma 10 : Coupe frontale du vagin

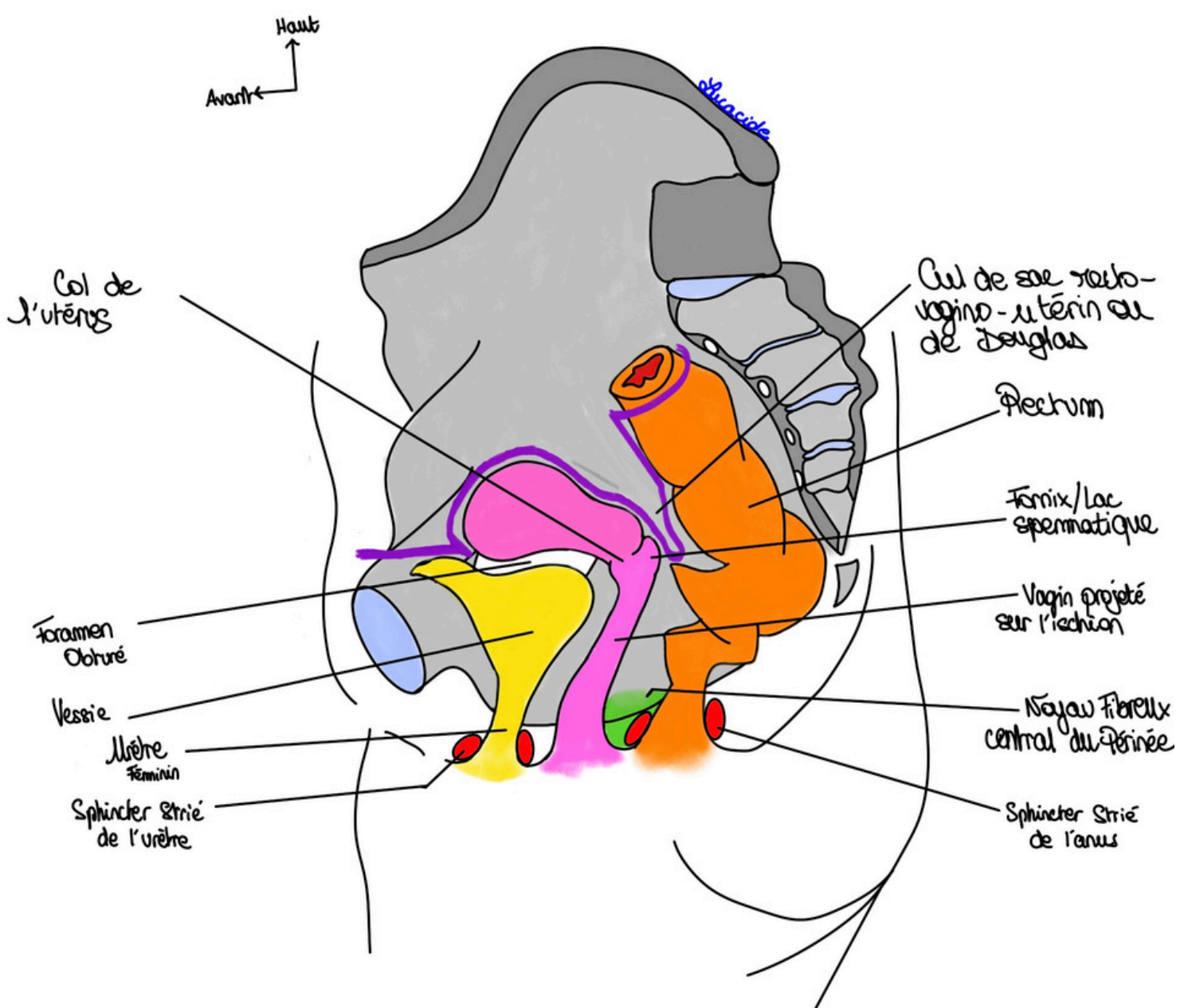
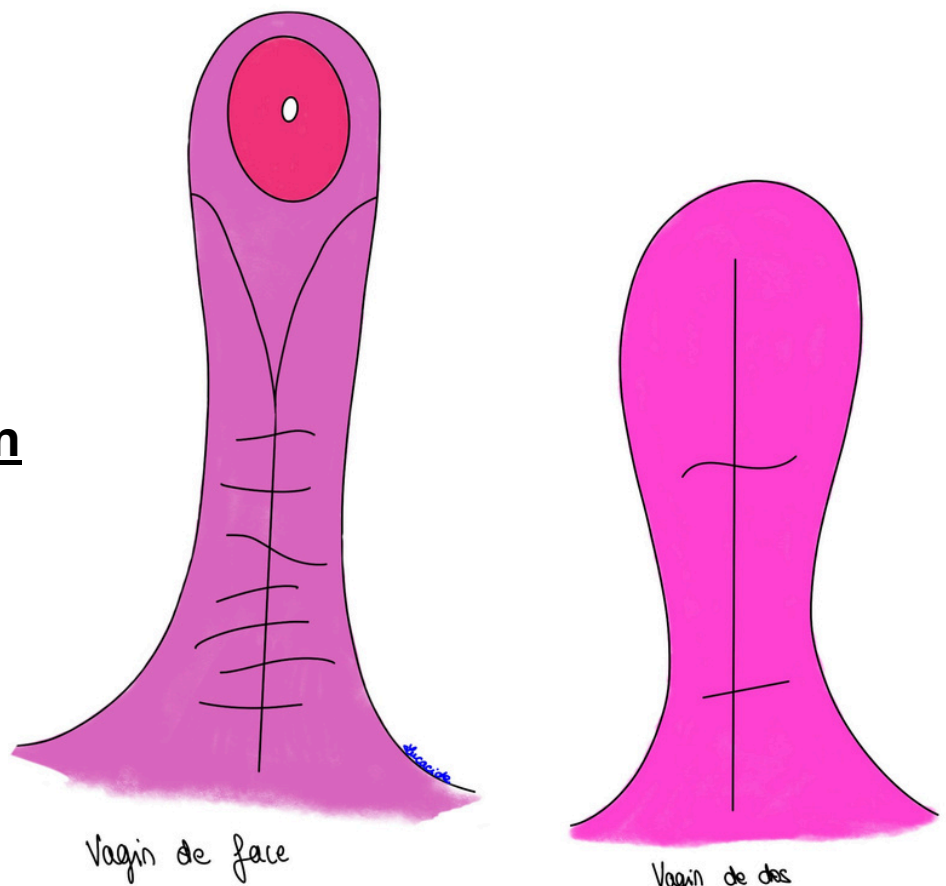


Schéma 11 : Coupe sagittale du Petit Bassin de la femme

Schéma 12 : Le vagin



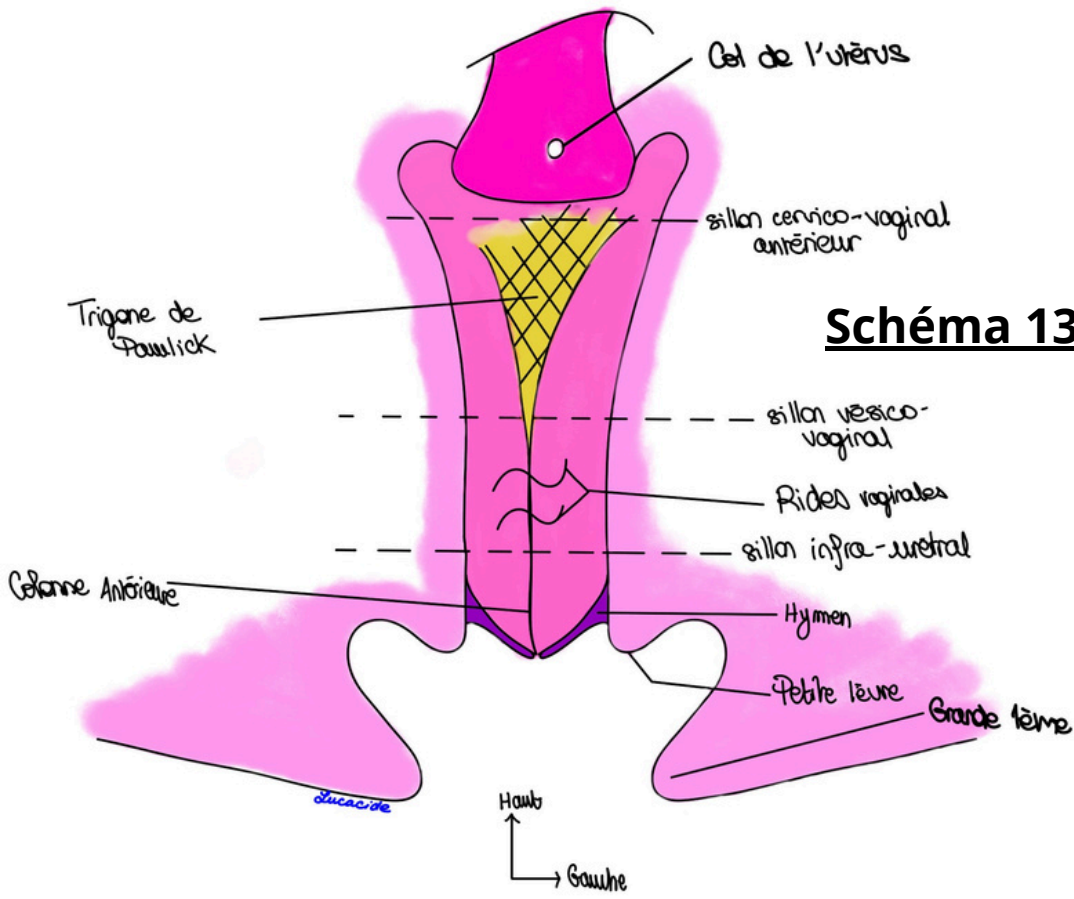
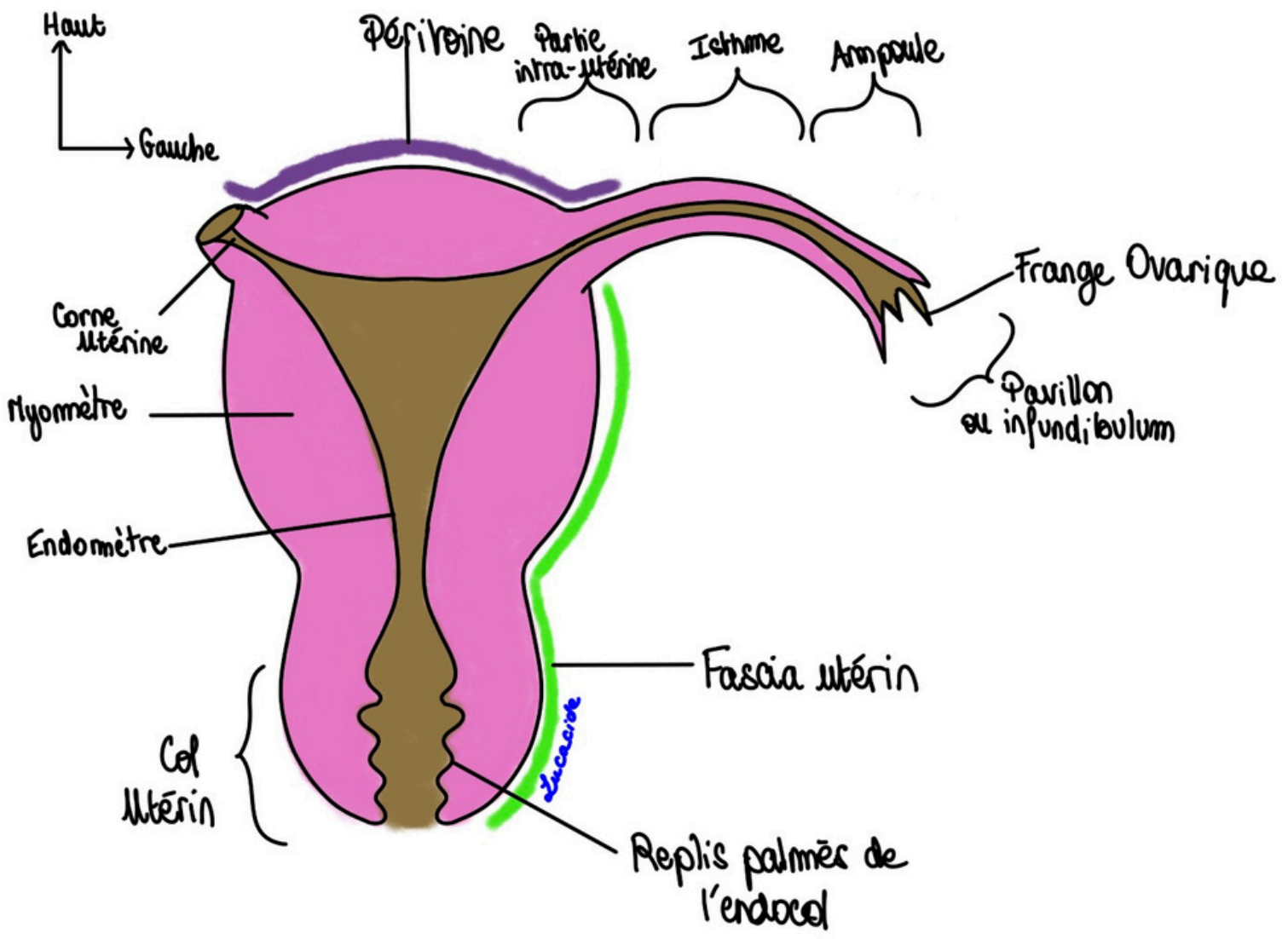


Schéma 13: Le vagin (bis).

Schéma 14: L'utérus et les trompes






Schéma 15 : Les différentes formes de col utérin

Schéma 16 : Vascularisation utérine et vaginale

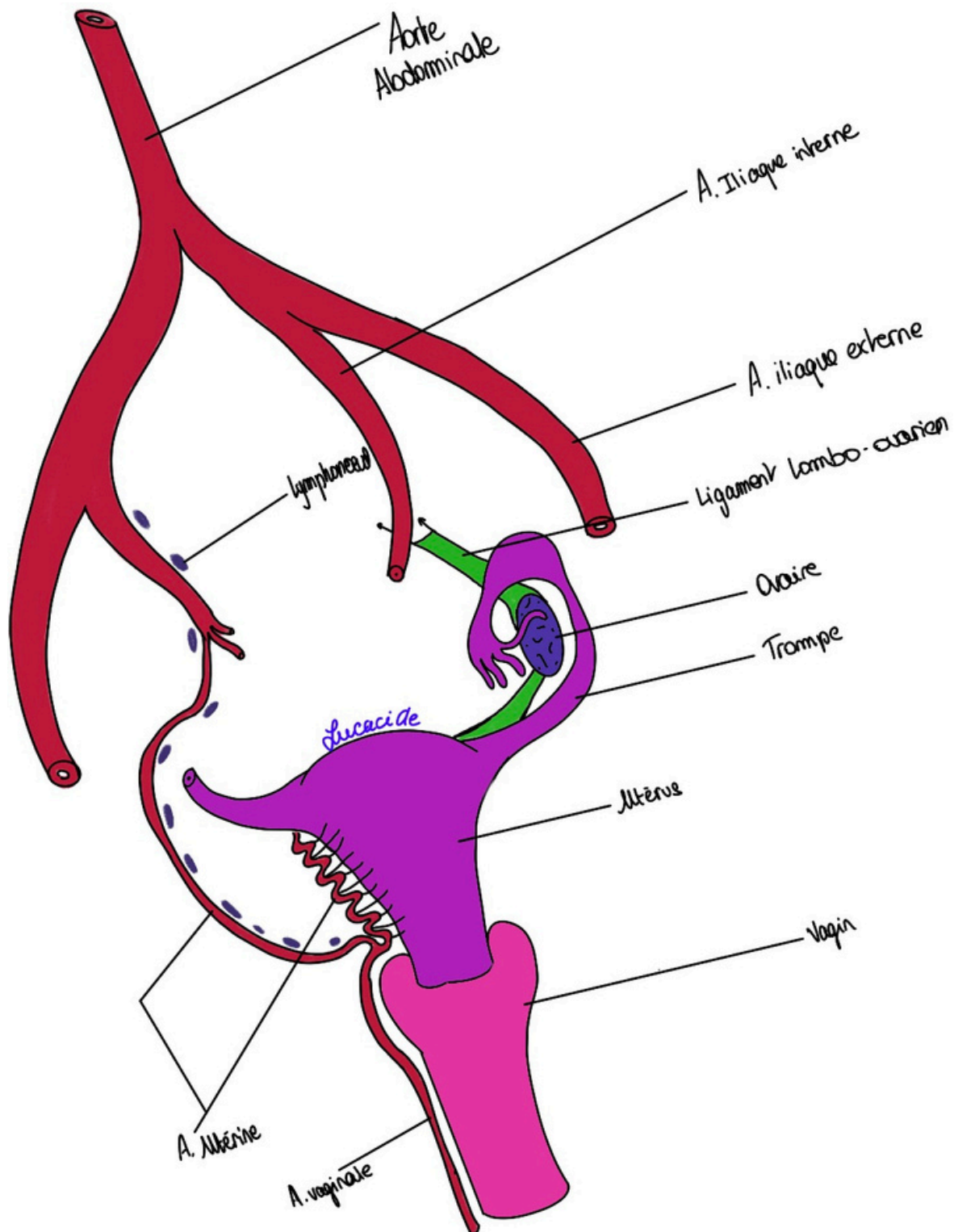


Schéma 17 : L'ovaire

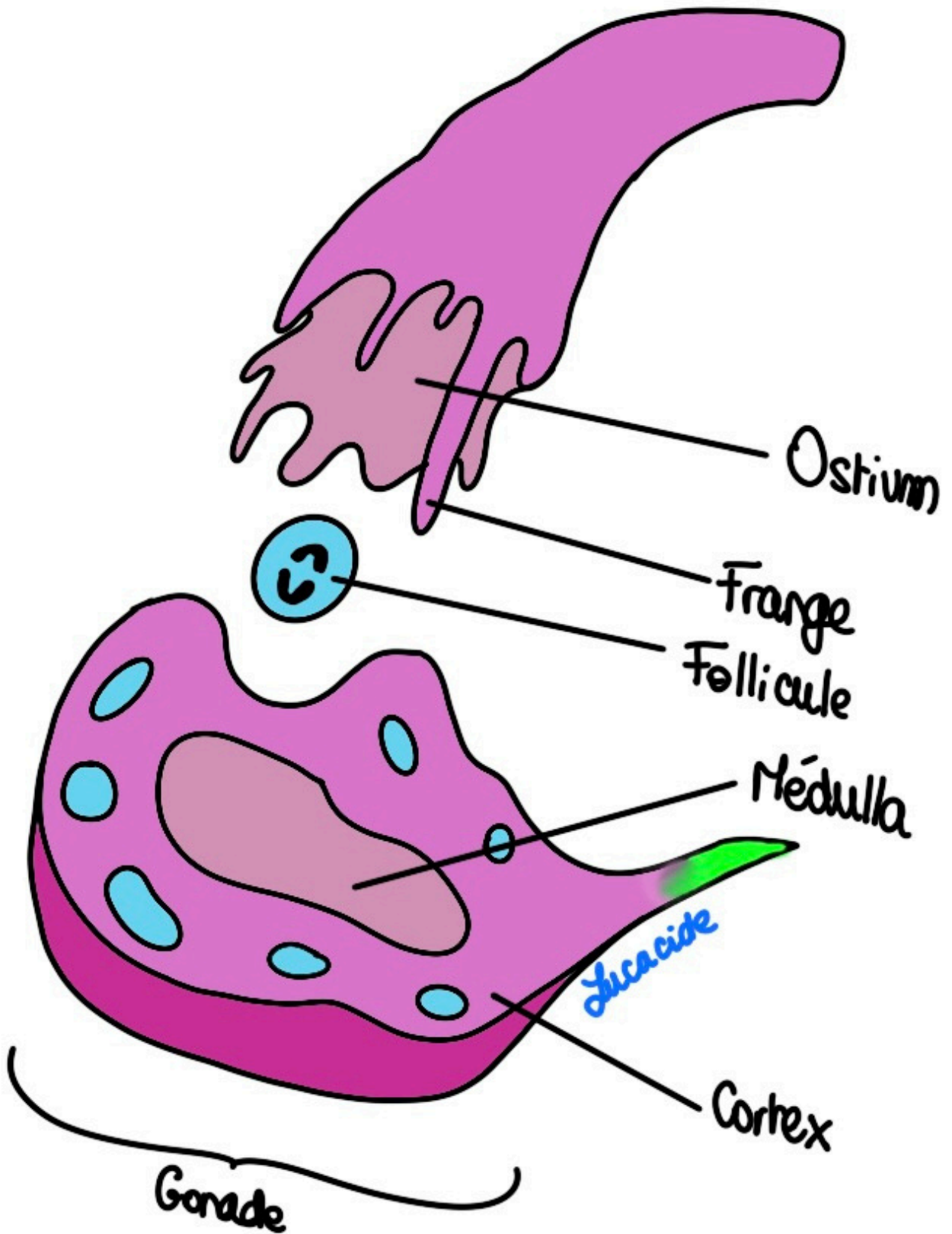


Schéma 20 : Angles et cul-de-sac

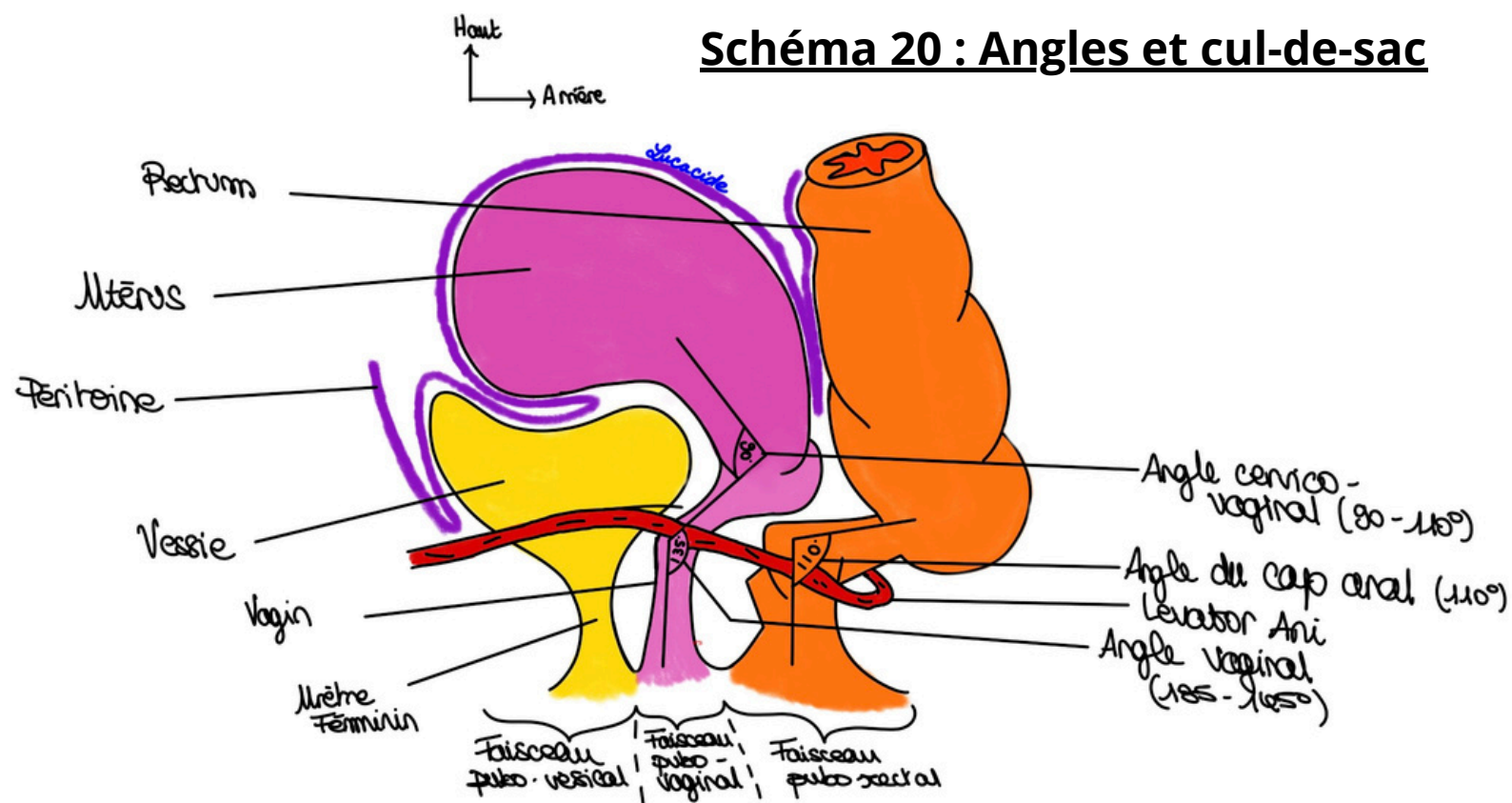


Schéma 21 : Examen gynécologique de la femme

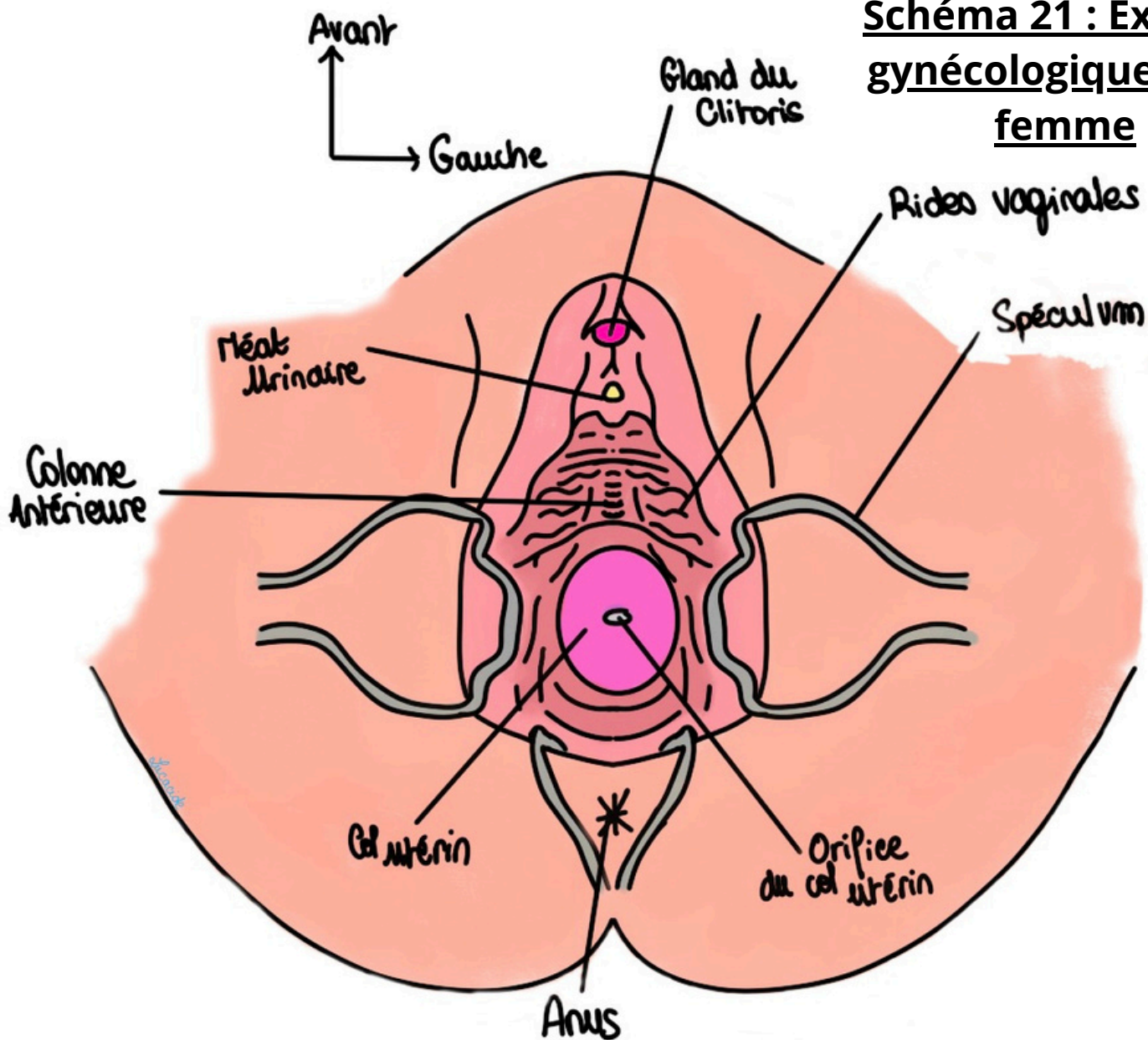


Schéma 22 : Vue chirurgicale lors d'une coelioscopie (sans péritoine)

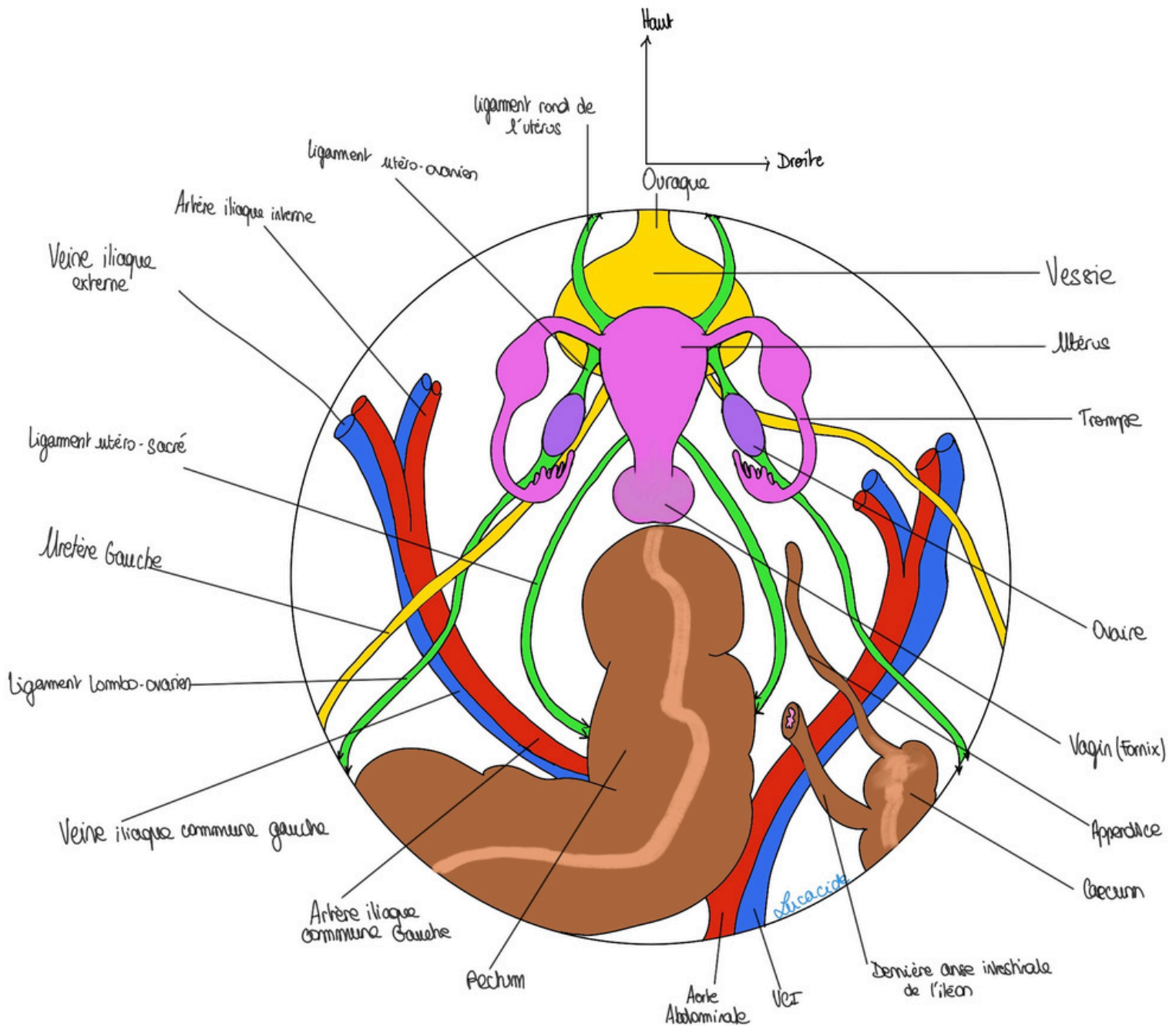
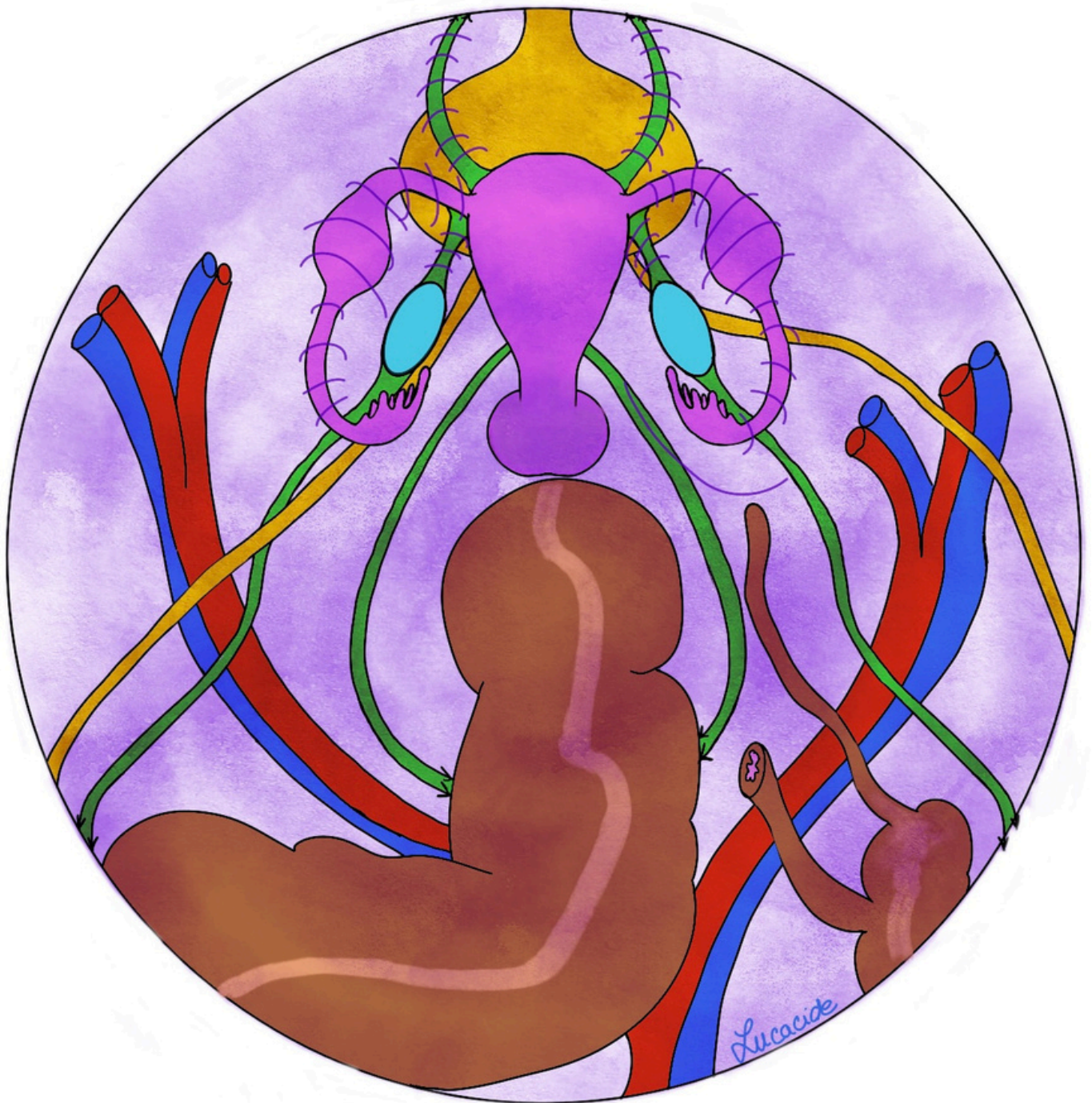
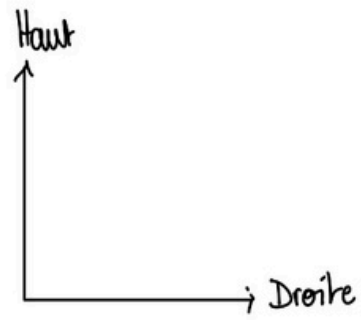


Schéma 23 : Vue chirurgicale lors d'une coelioscopie
(avec péritoine)



	Col Sain	Col malade (biopsie)
<i>Sucrose</i> Acide Acétique		
Lugol		

Schéma 24 : Colorations du col utérin

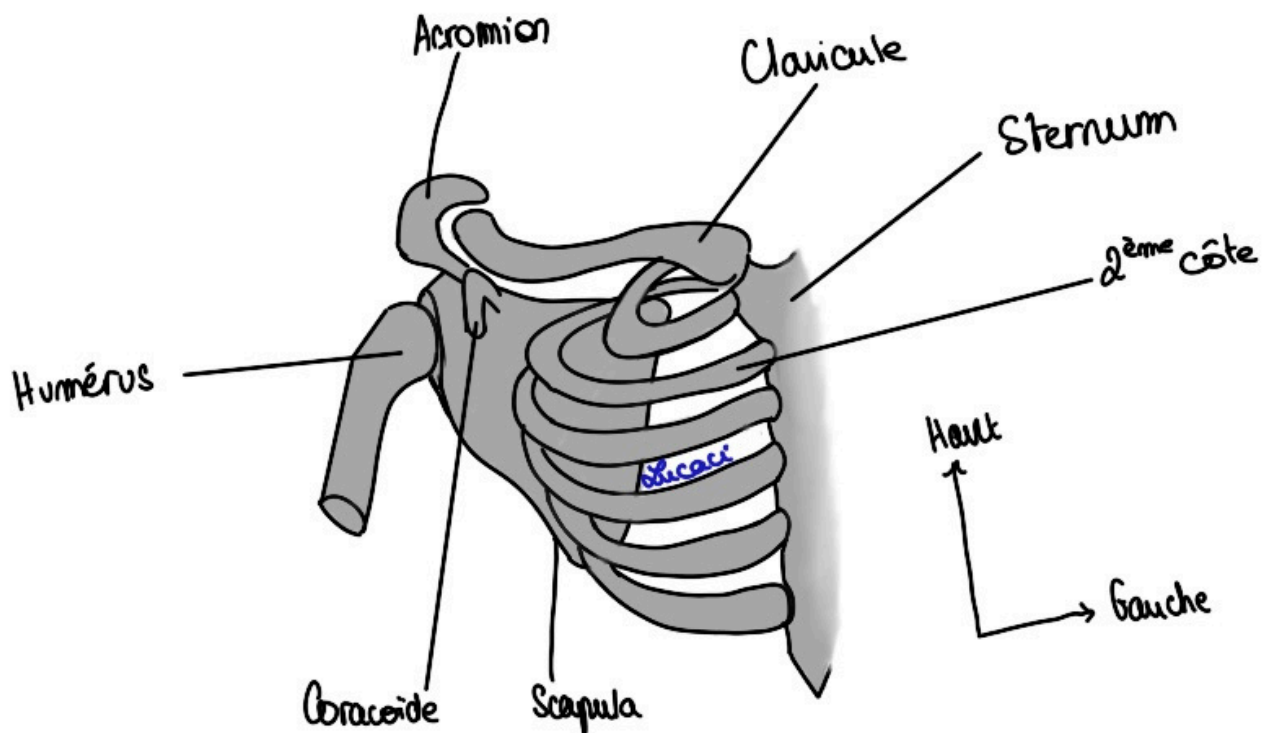


Schéma 25 : Os de la région axillaire

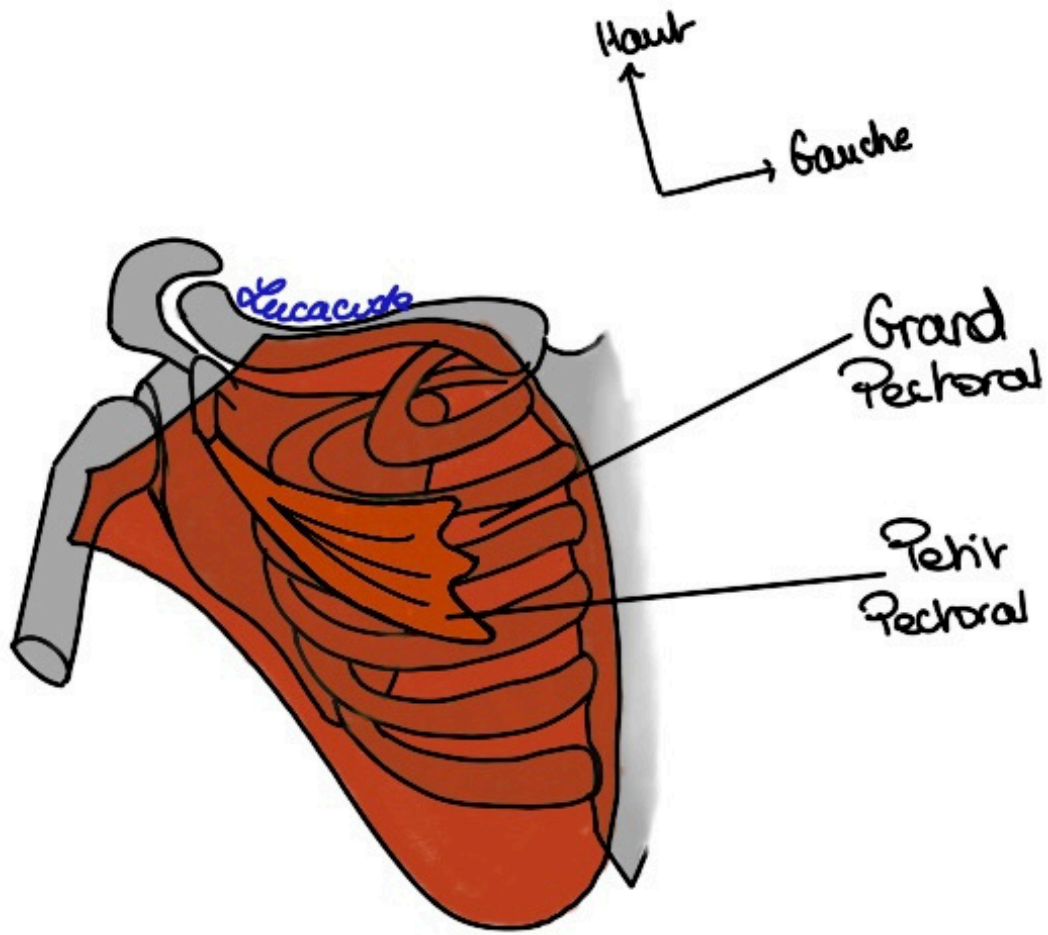


Schéma 26 : Thorax

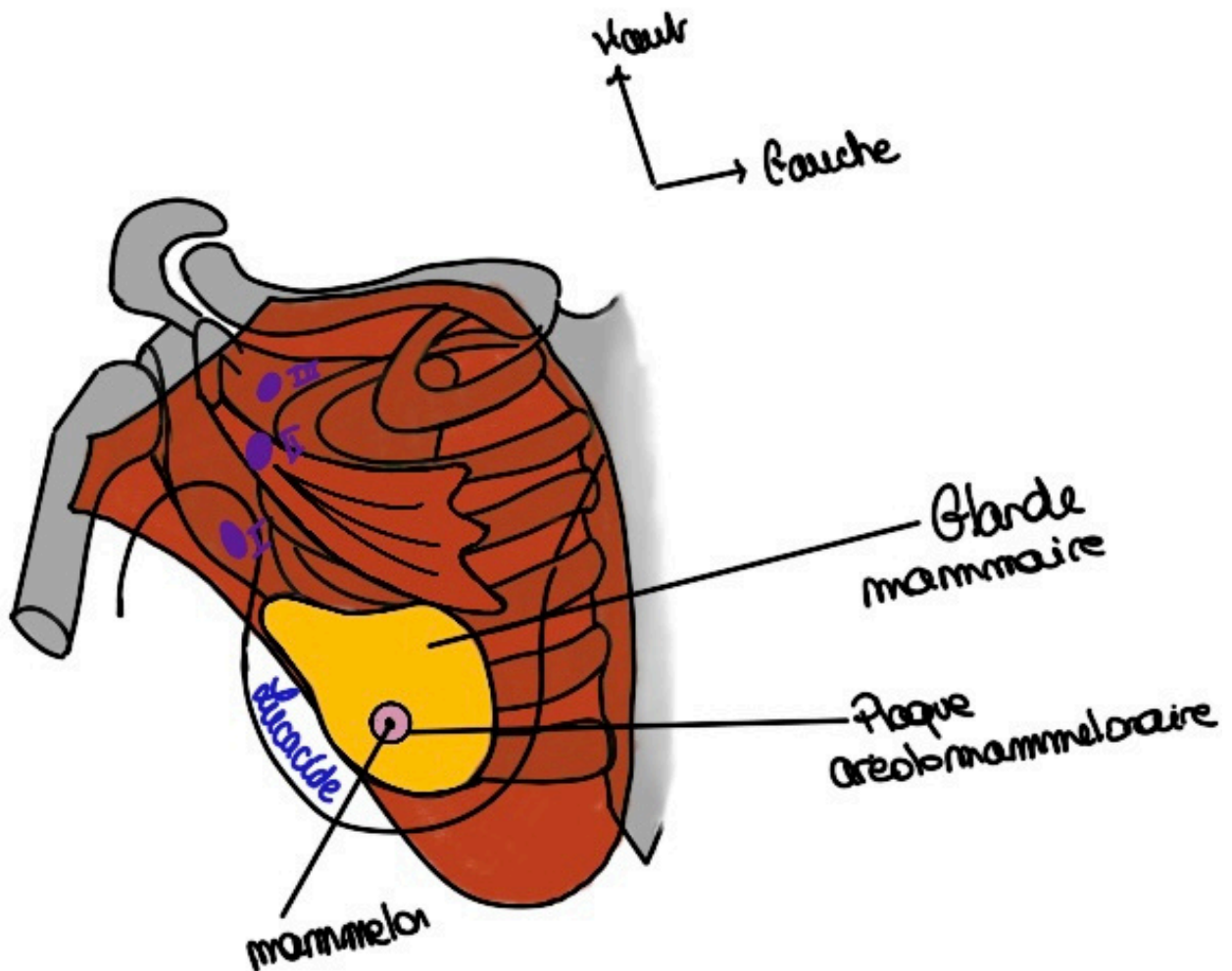


Schéma 27 : La glande mammaire

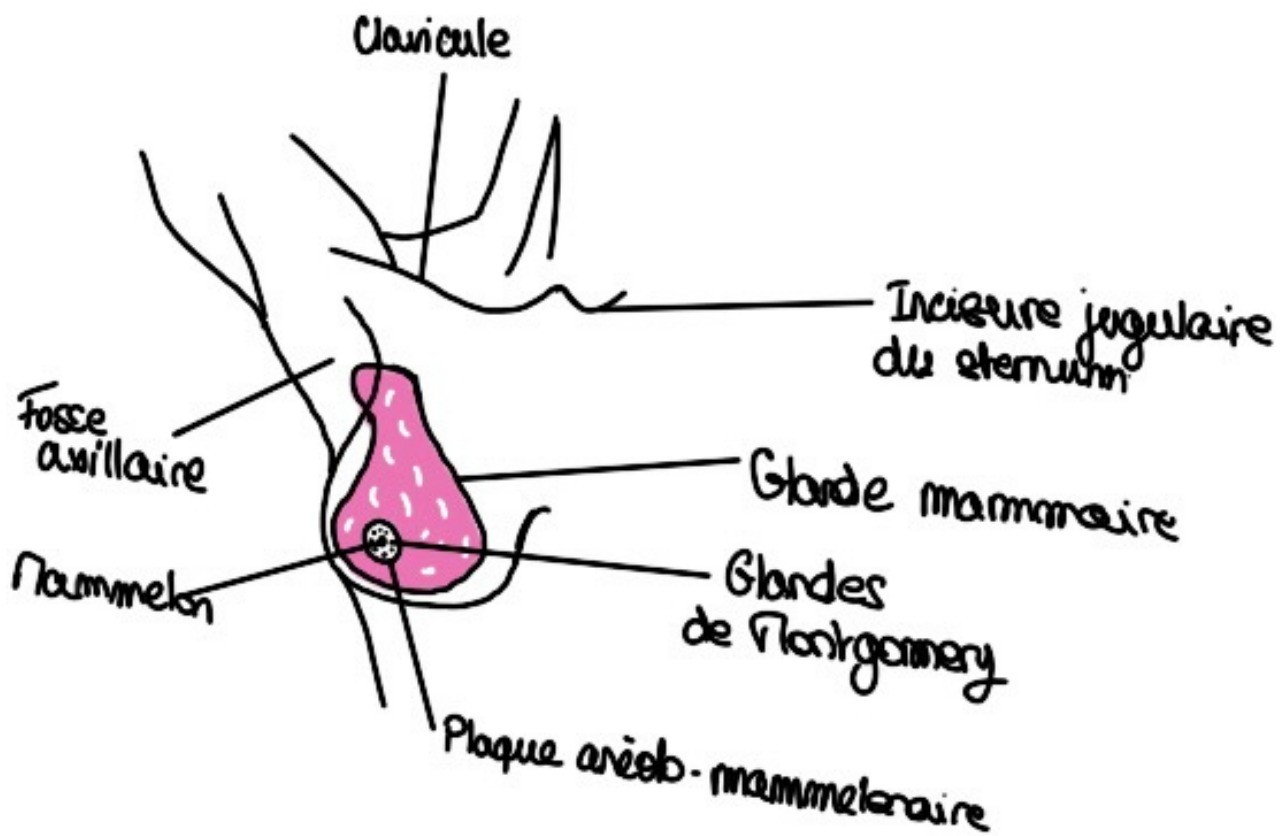


Schéma 28 : La glande mammaire (bis)

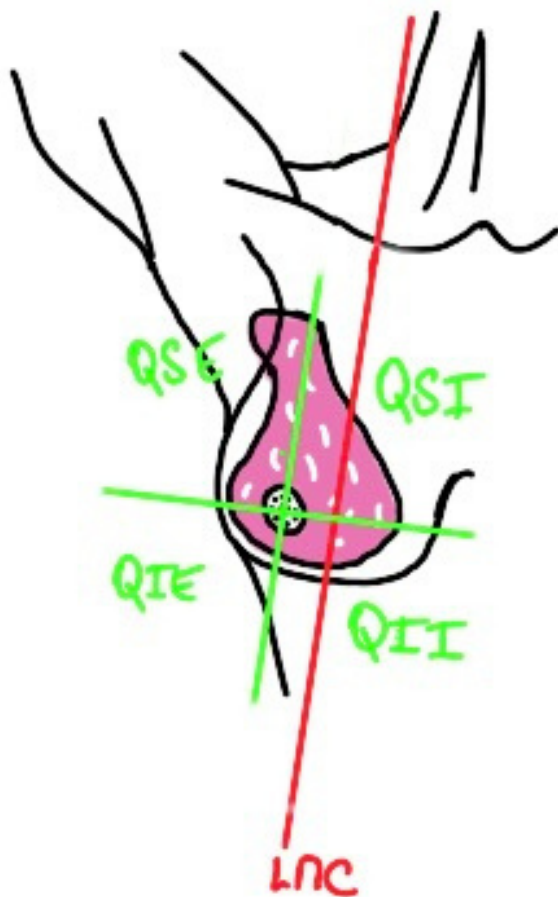


Schéma 29 : Cadrans

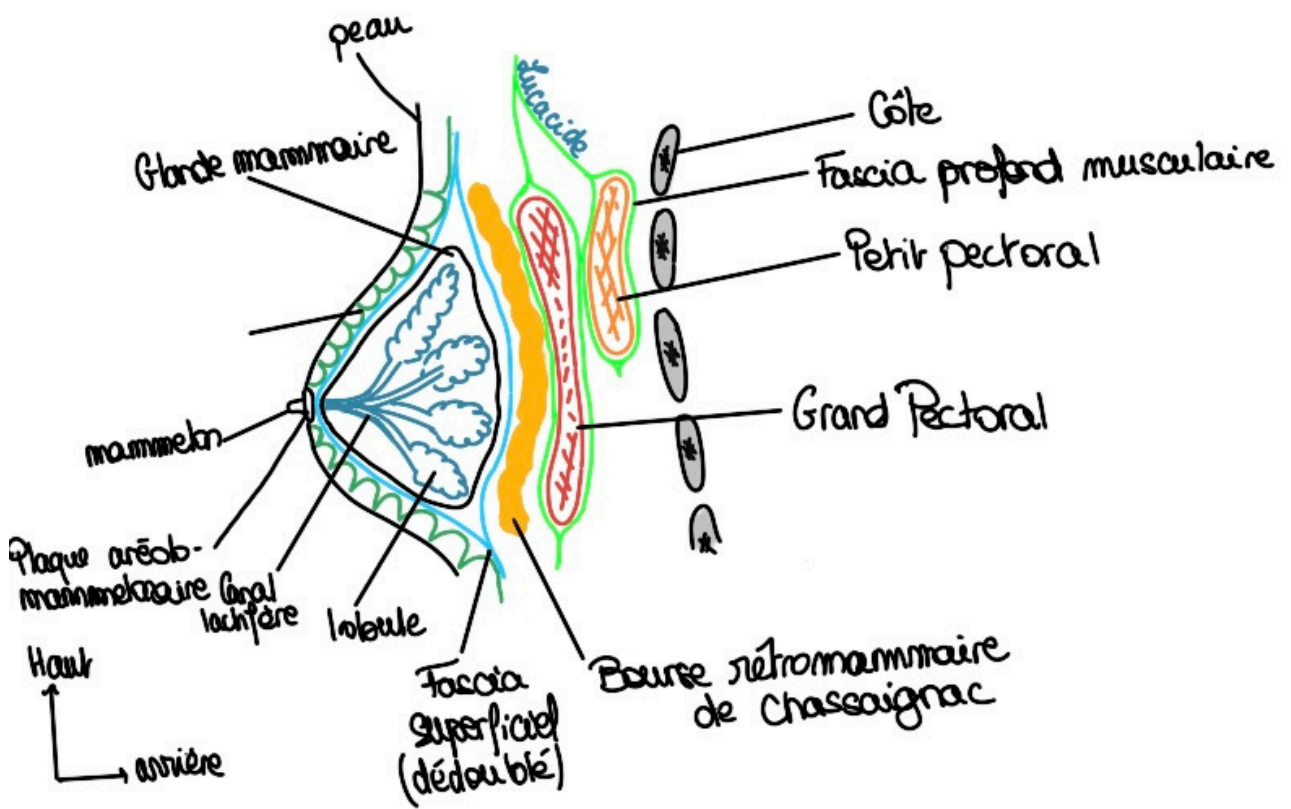


Schéma 30 : Coupe para-sagittale de la glande mammaire