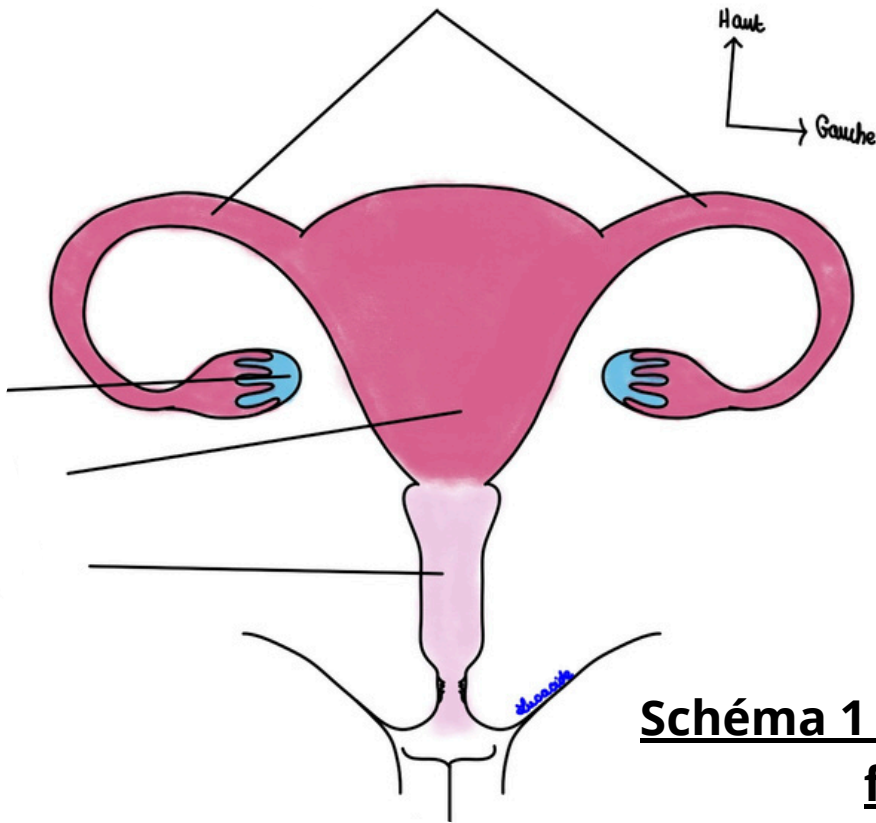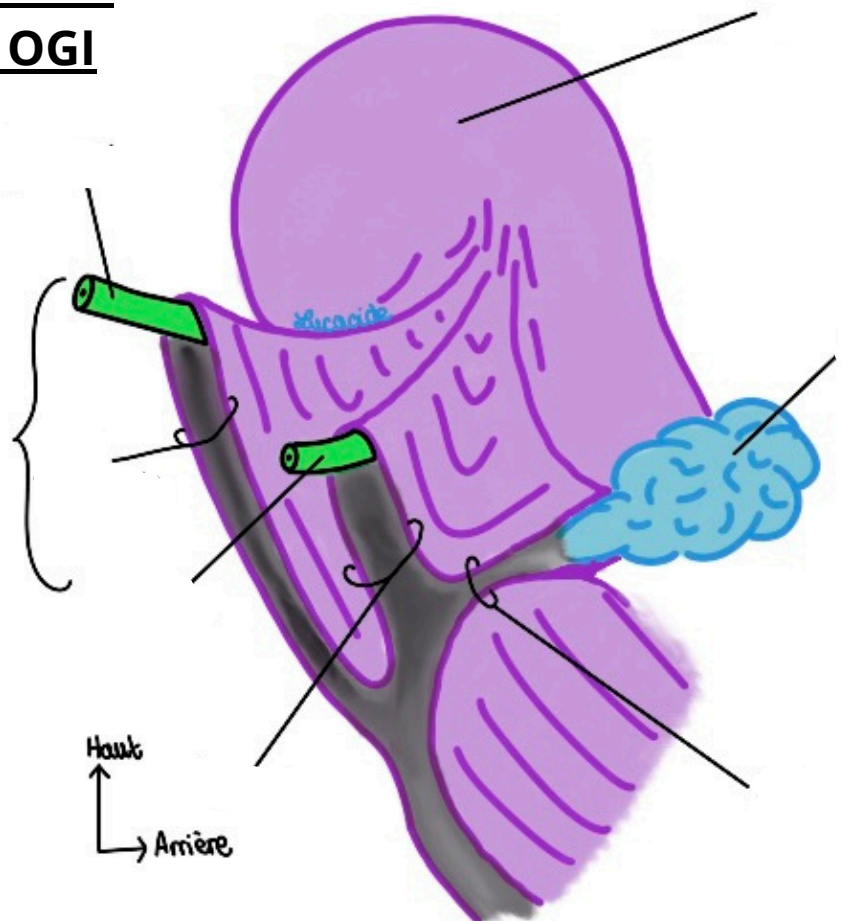
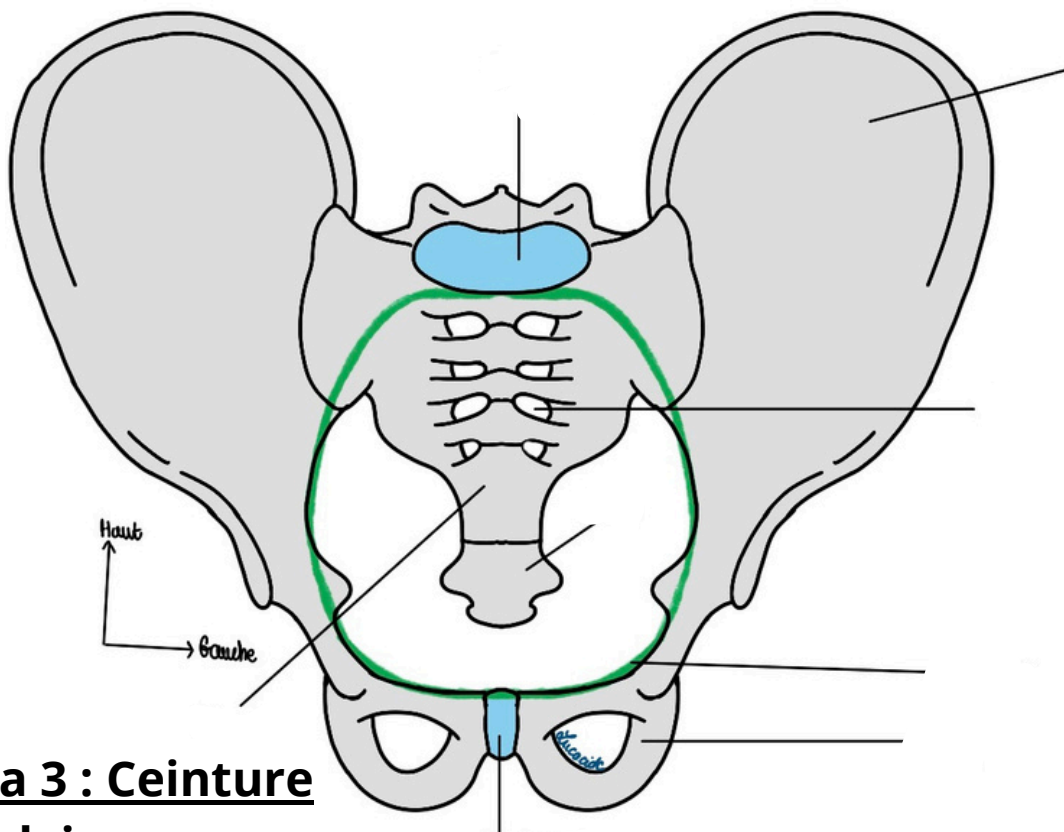


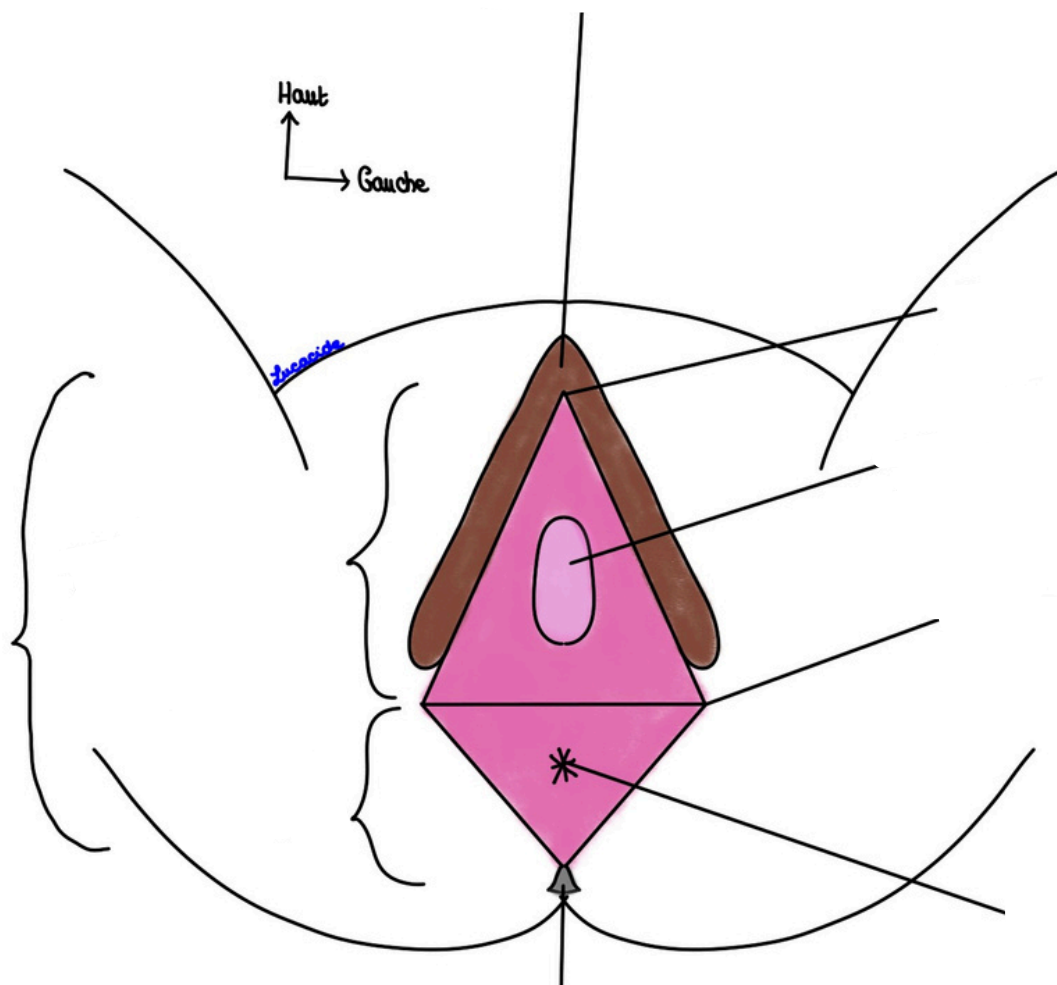
**Schéma 1 : Appareil génital féminin**

**Schéma 2 : Rapports du Péritoine avec les OGI**



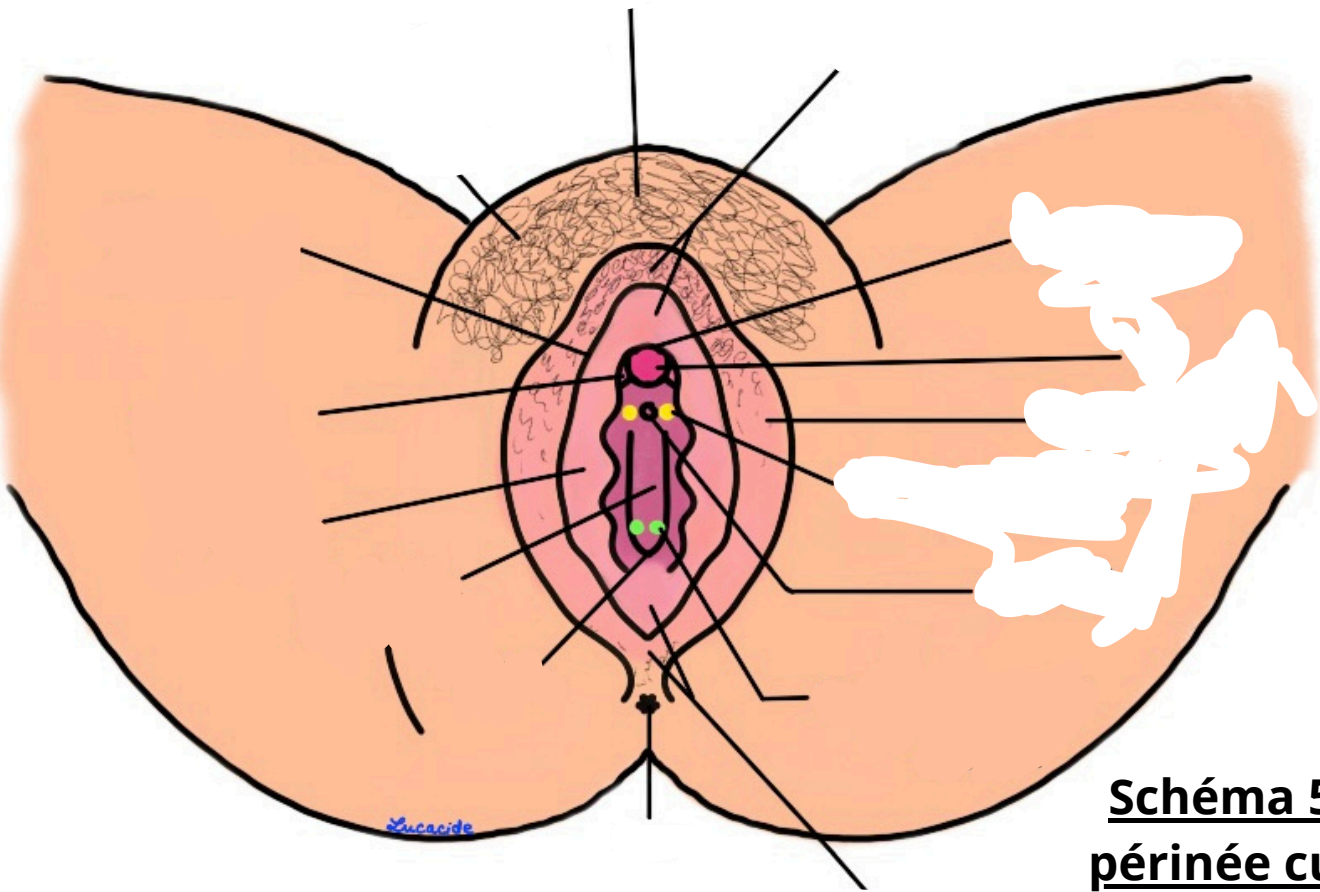


**Schéma 3 : Ceinture pelvienne**



**Schéma 4 : Vision schématique des OGE**

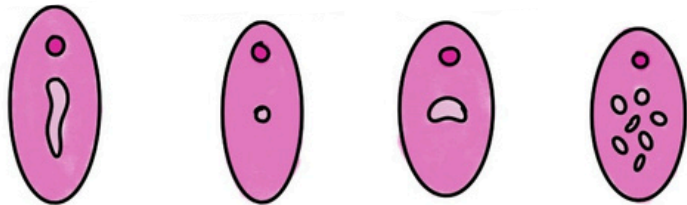
Haut  
→ Gauche



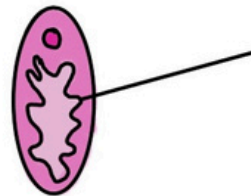
**Schéma 5 : Le  
périnée cutané**

**Schéma 6 : Les  
différentes formes  
d'hymen**

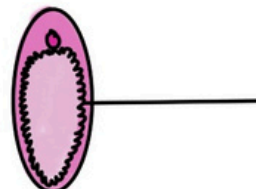
Hymen

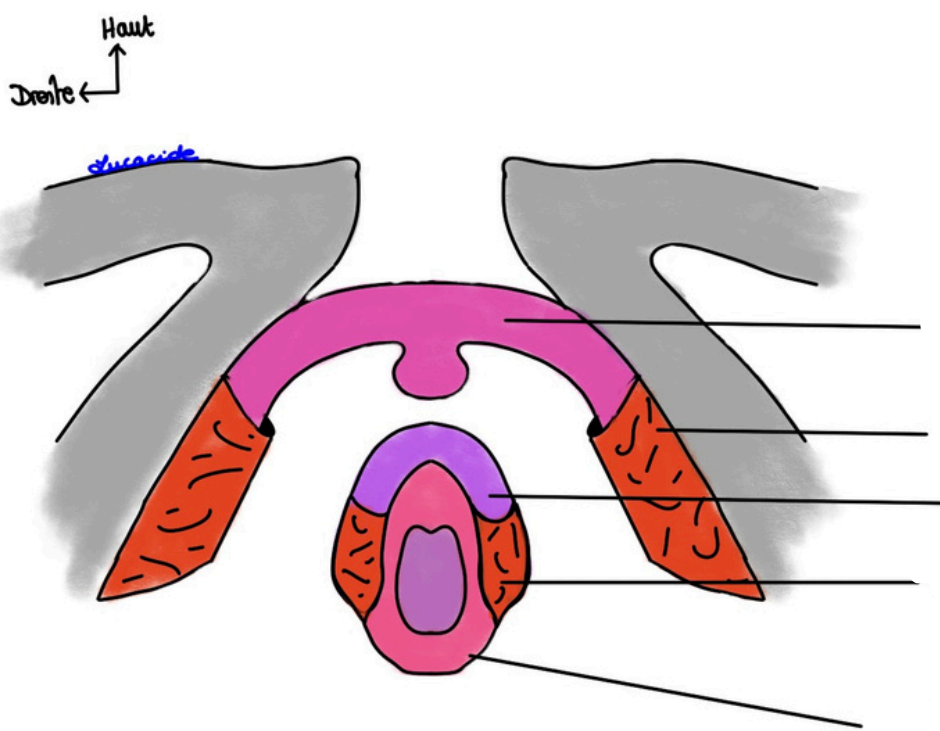


Hymen

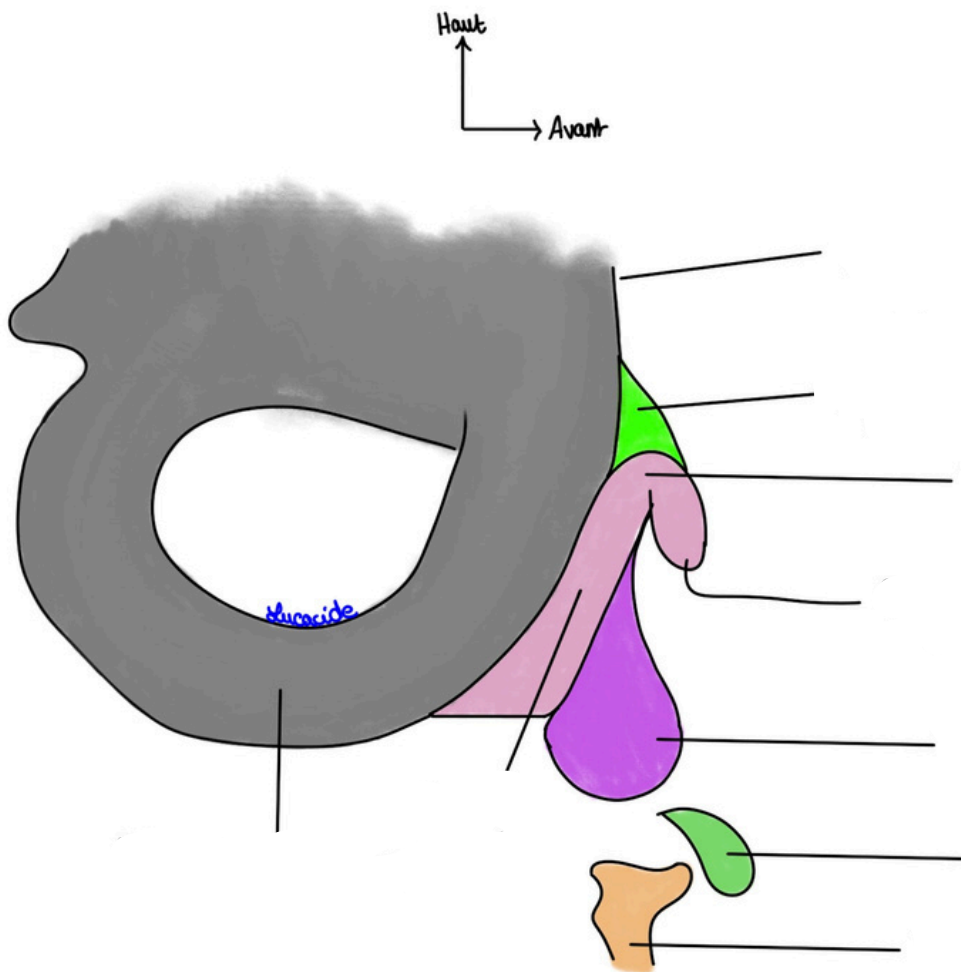


Hymen



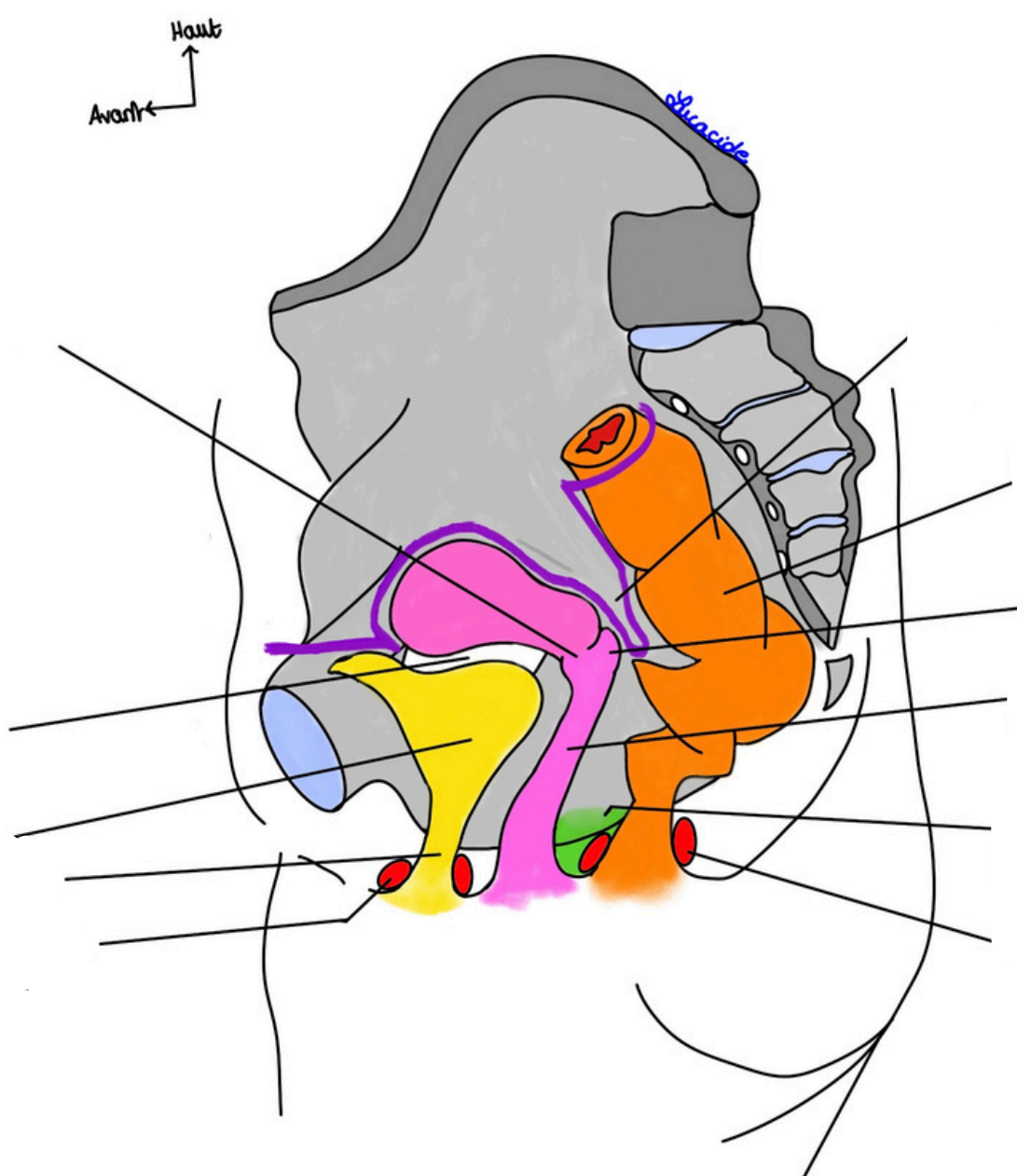


**Schéma 7 : Les corps érectiles et leurs muscles en cornets**



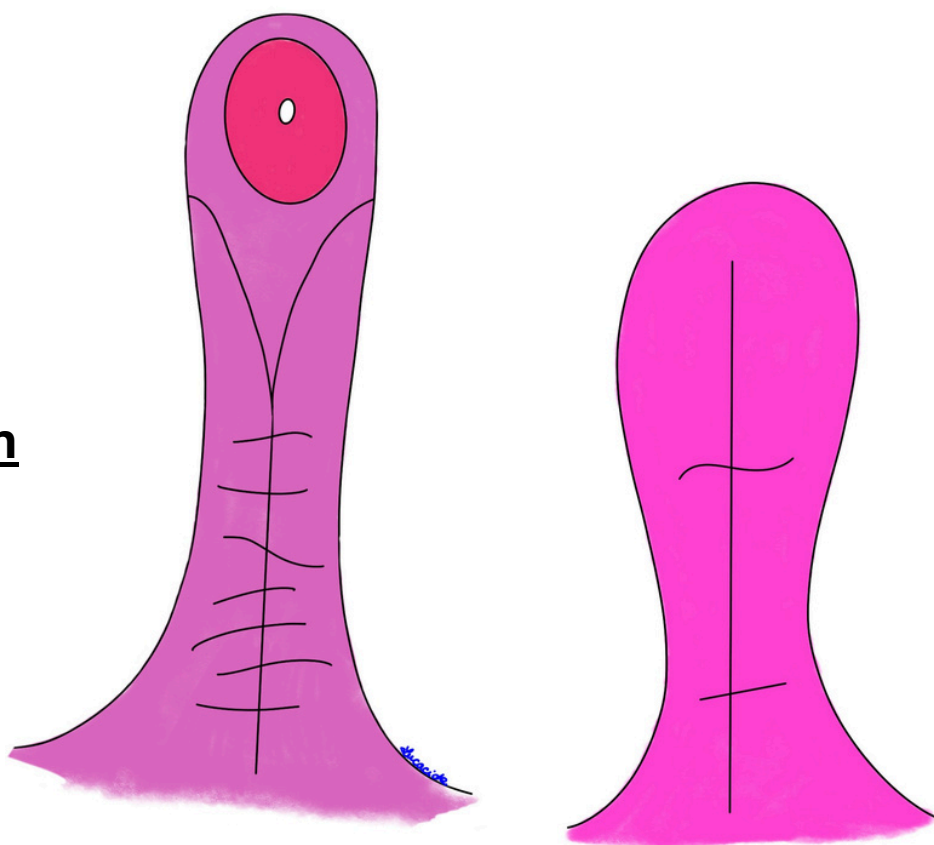
**Schéma 8 : Les corps érectiles en vue de profil**



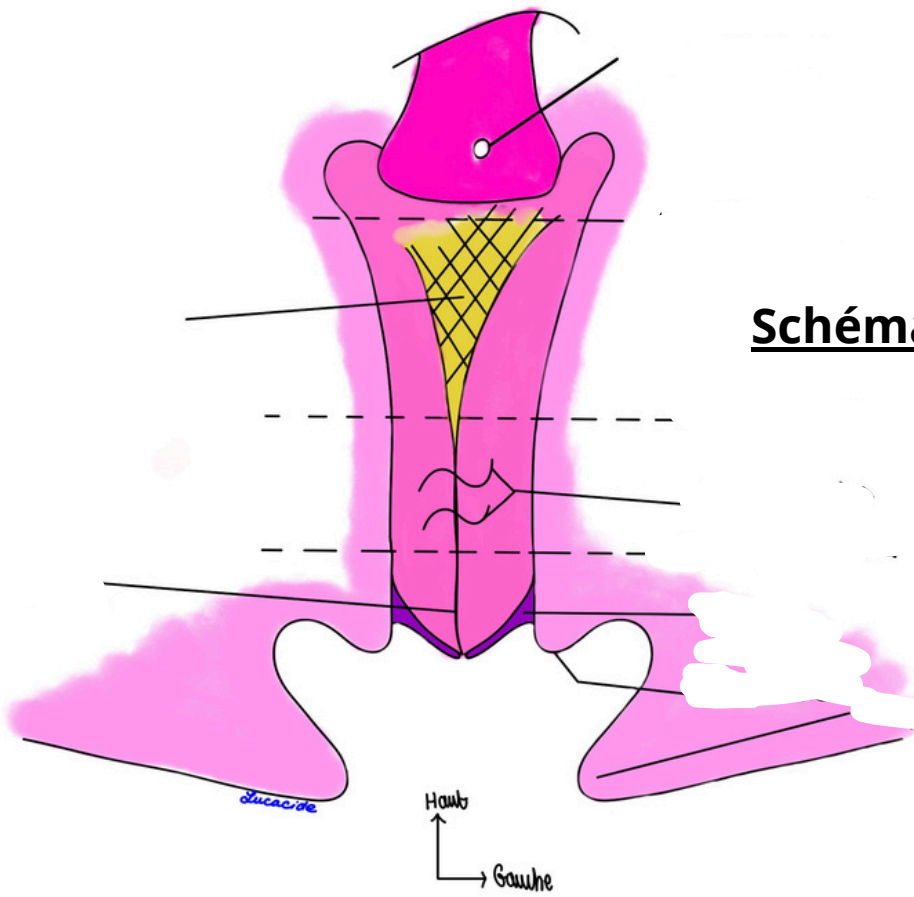


**Schéma 11 : Coupe sagittale du Petit Bassin de la femme**

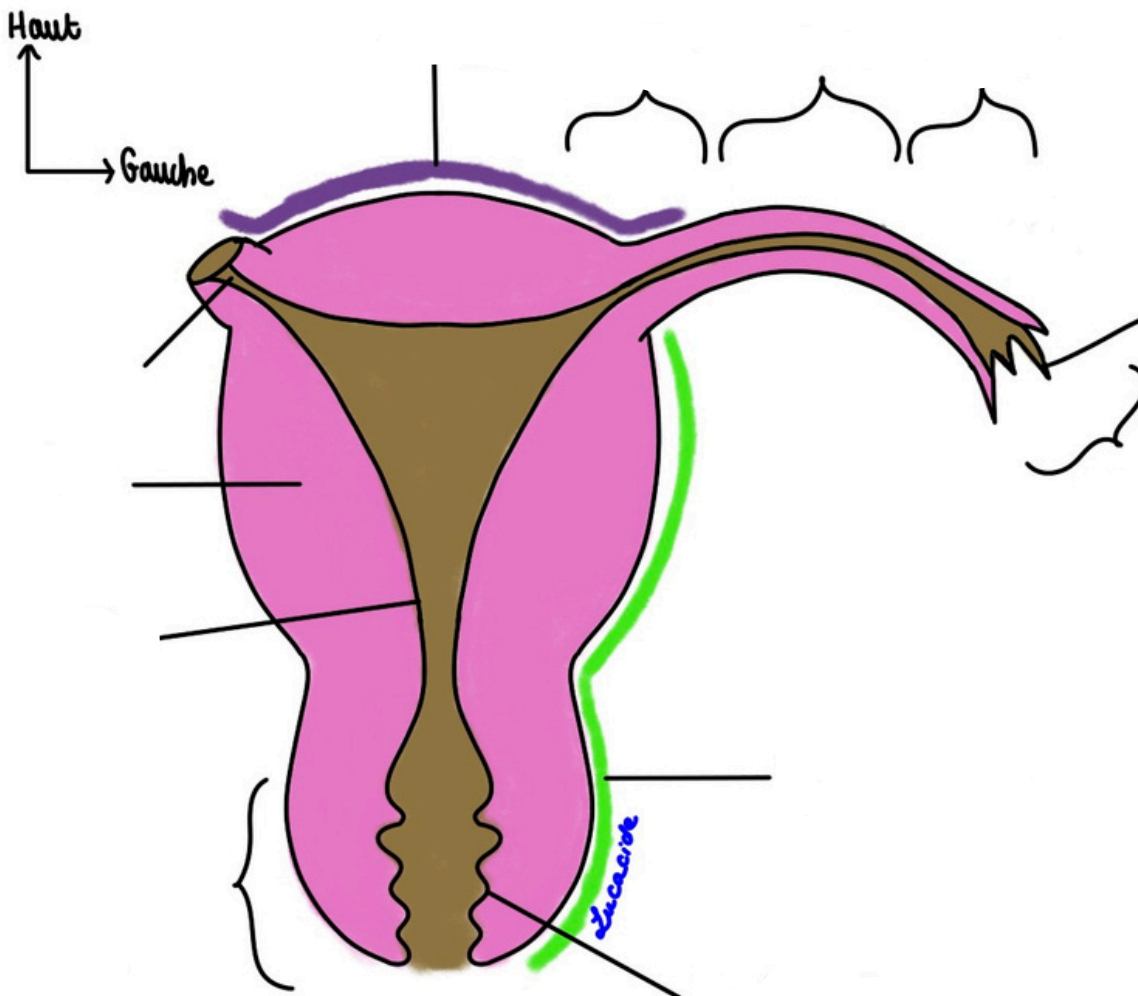
**Schéma 12 : Le vagin**

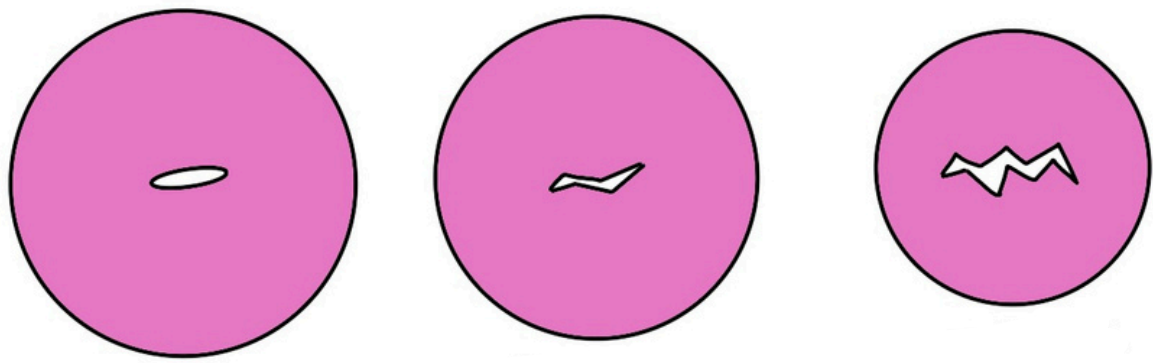


**Schéma 13: Le vagin (bis).**



**Schéma 14 : L'utérus et les trompes**





**Schéma 15 : Les différentes formes de col utérin**

**Schéma 16 : Vascularisation utérine et vaginale**

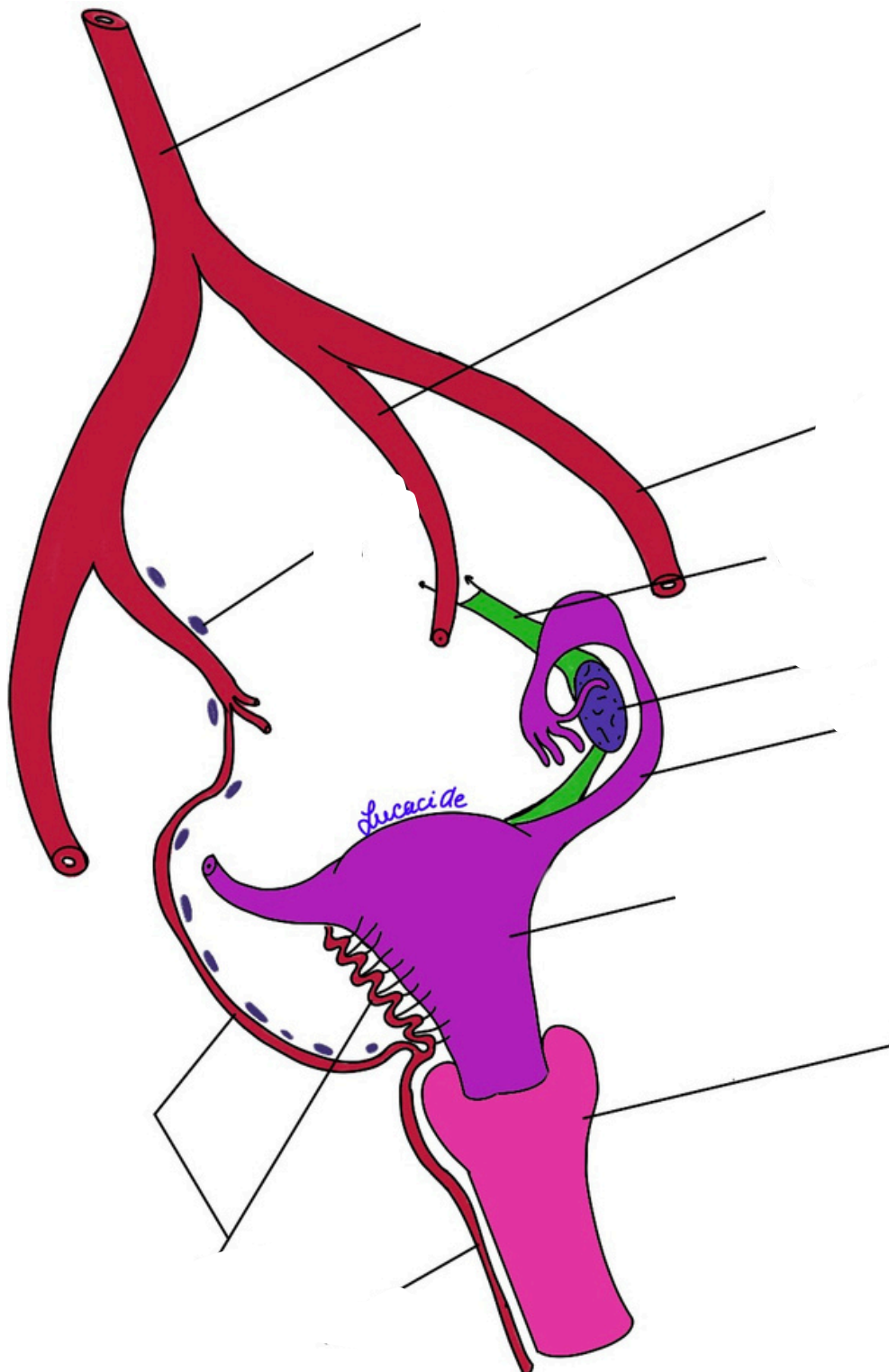
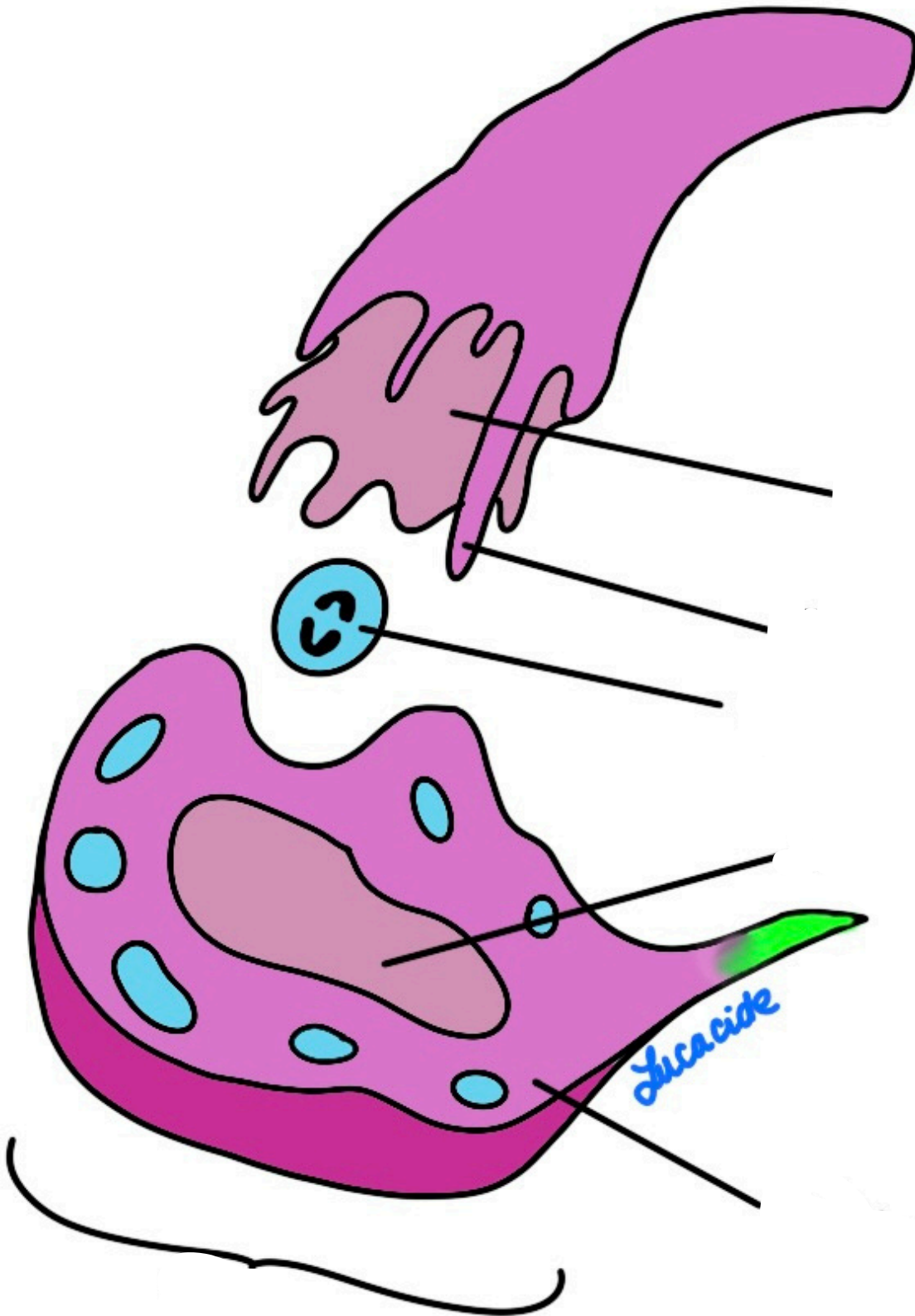
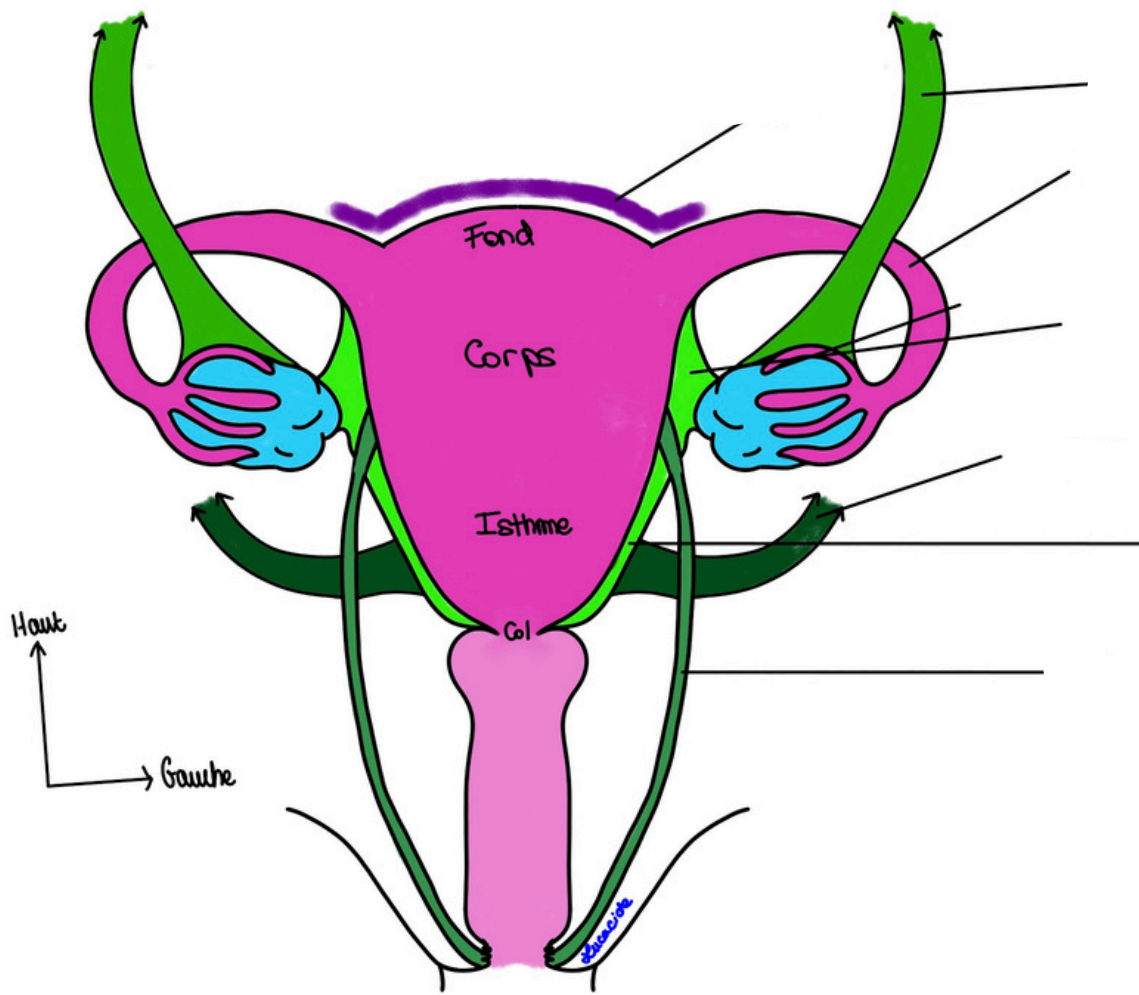
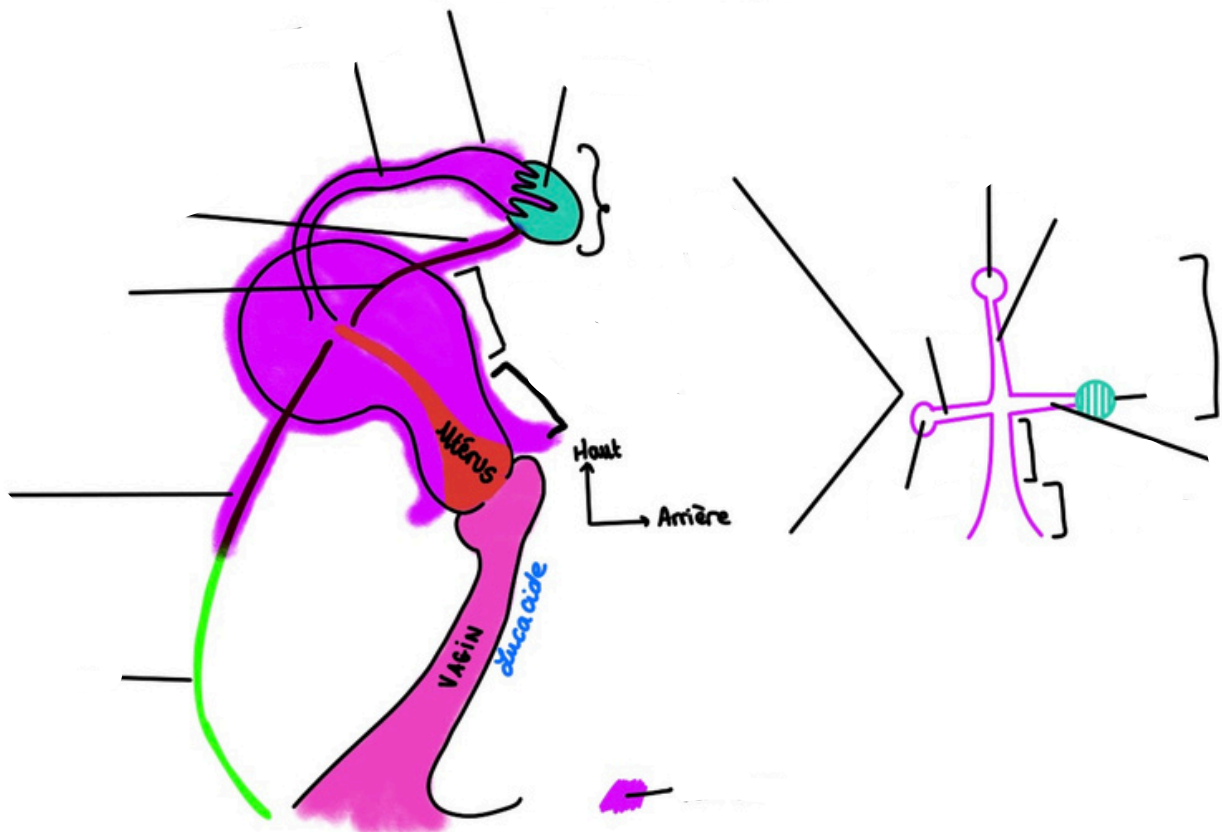


Schéma 17 : L'ovaire

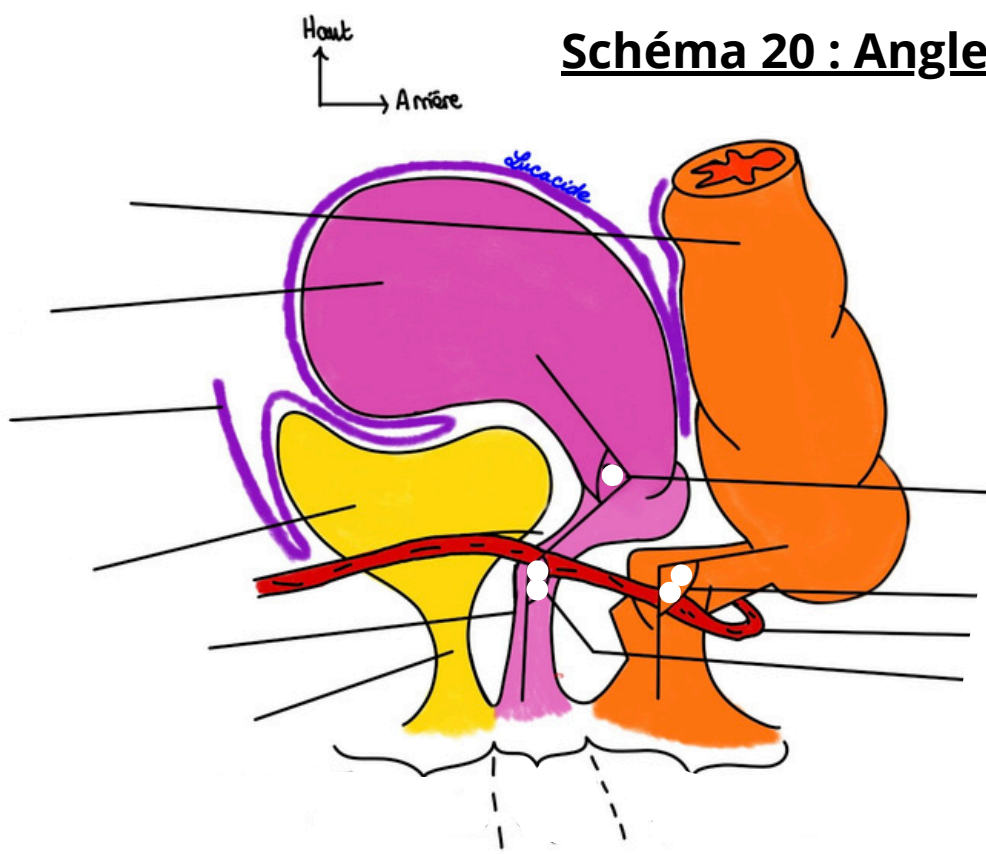




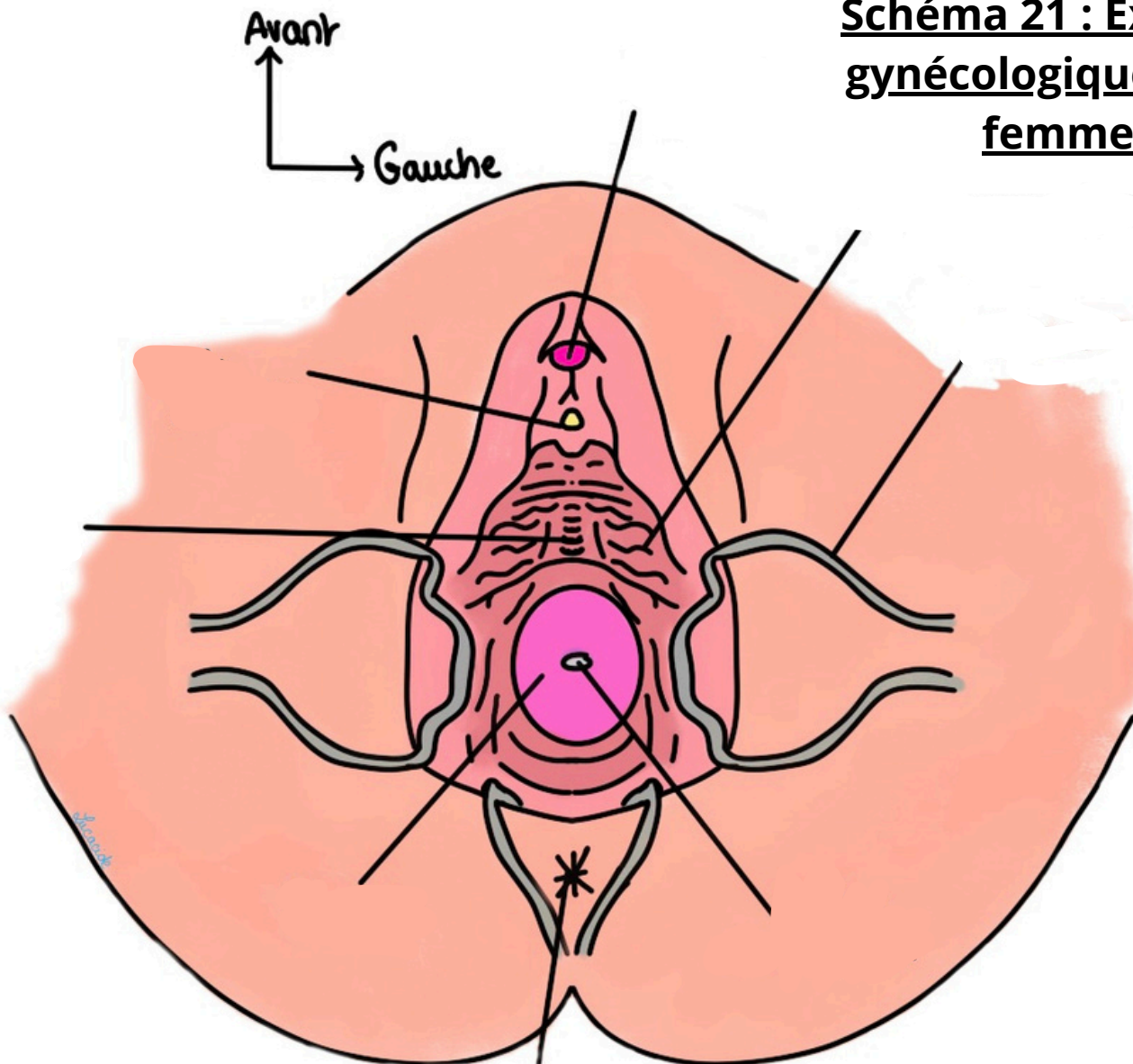
**Schéma 18 et 19 : Les ligaments**



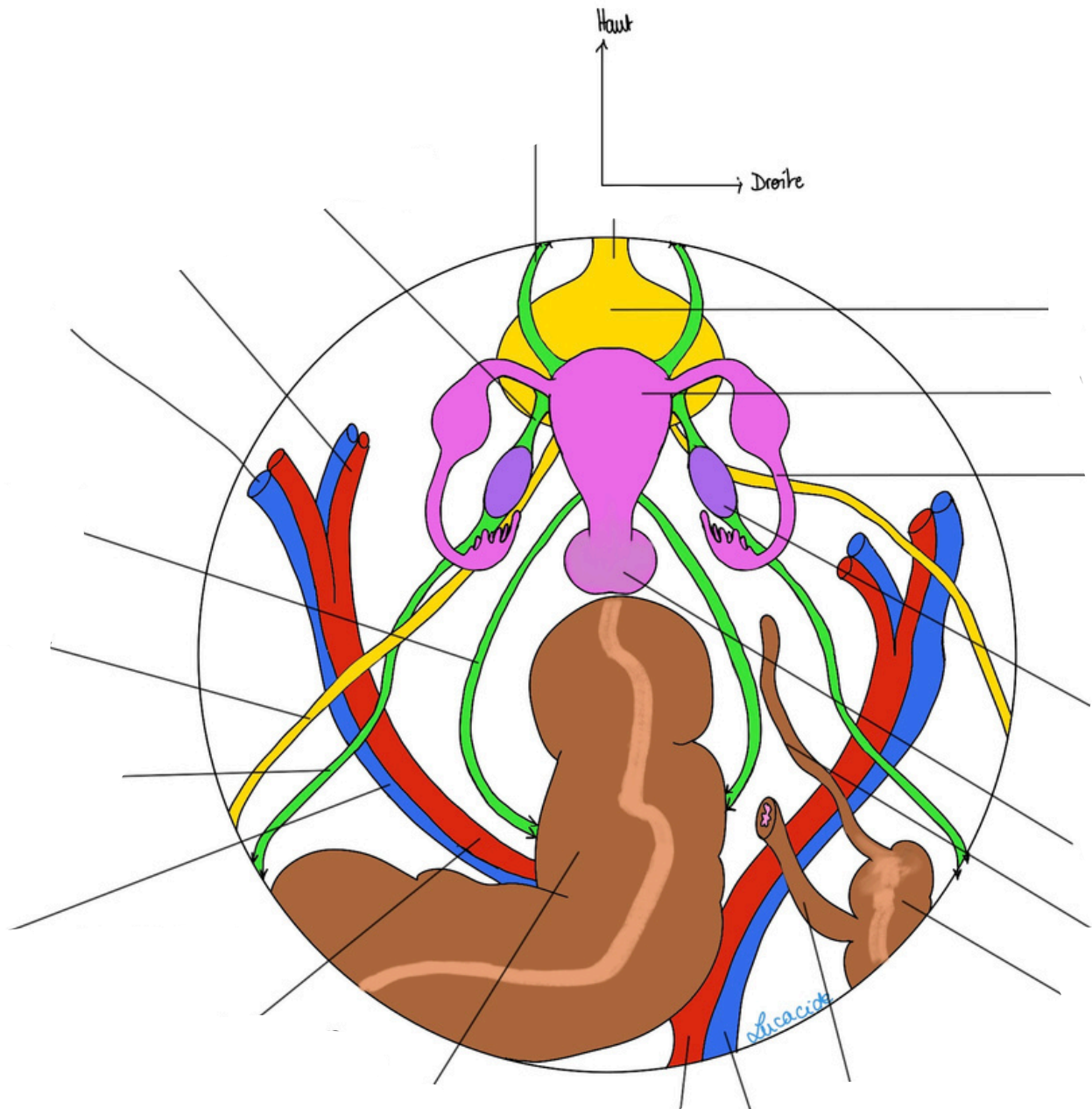
**Schéma 20 : Angles et cul-de-sac**



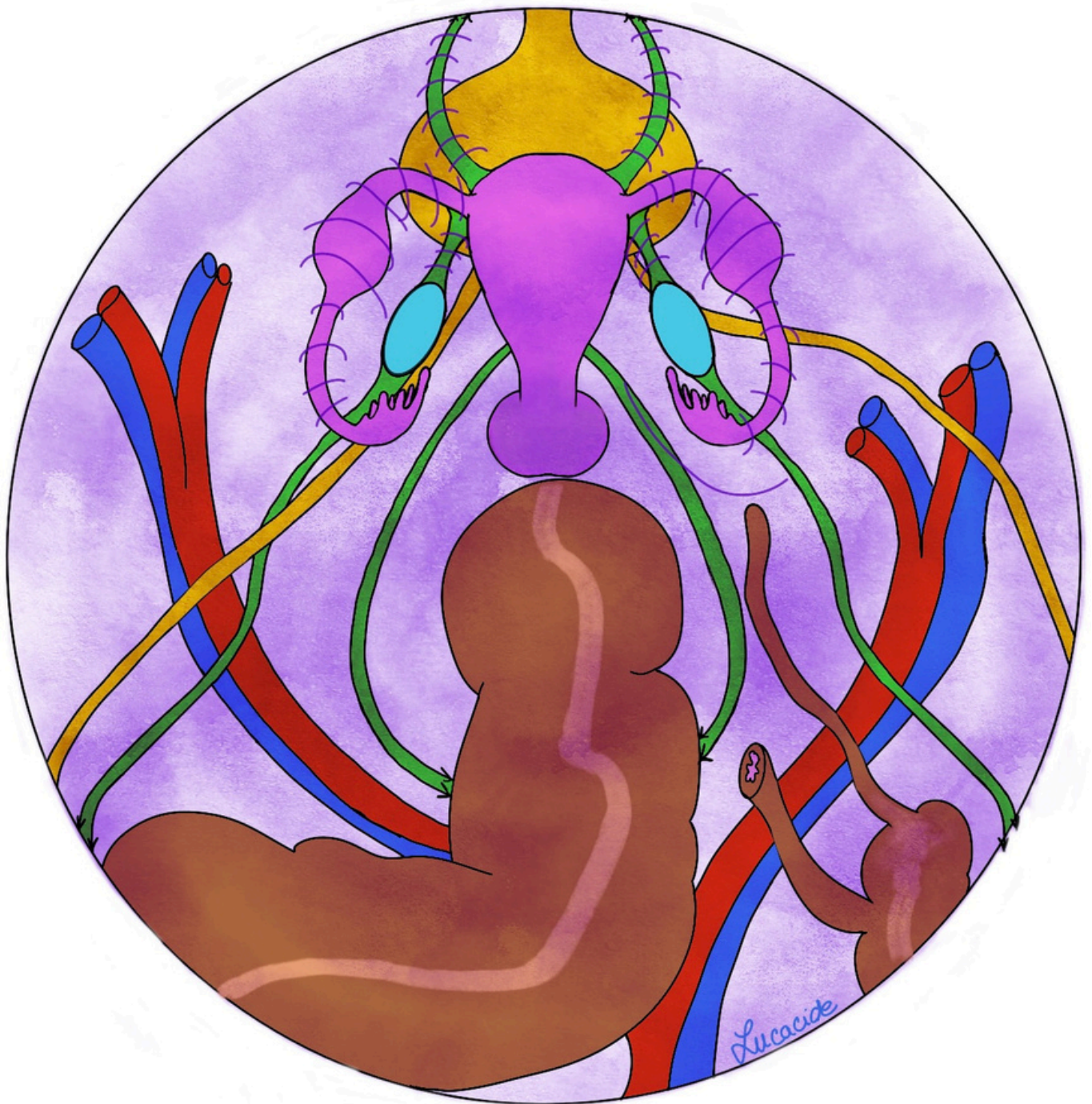
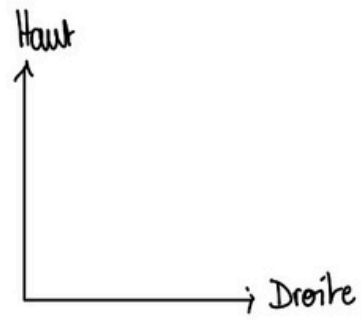
**Schéma 21 : Examen gynécologique de la femme**

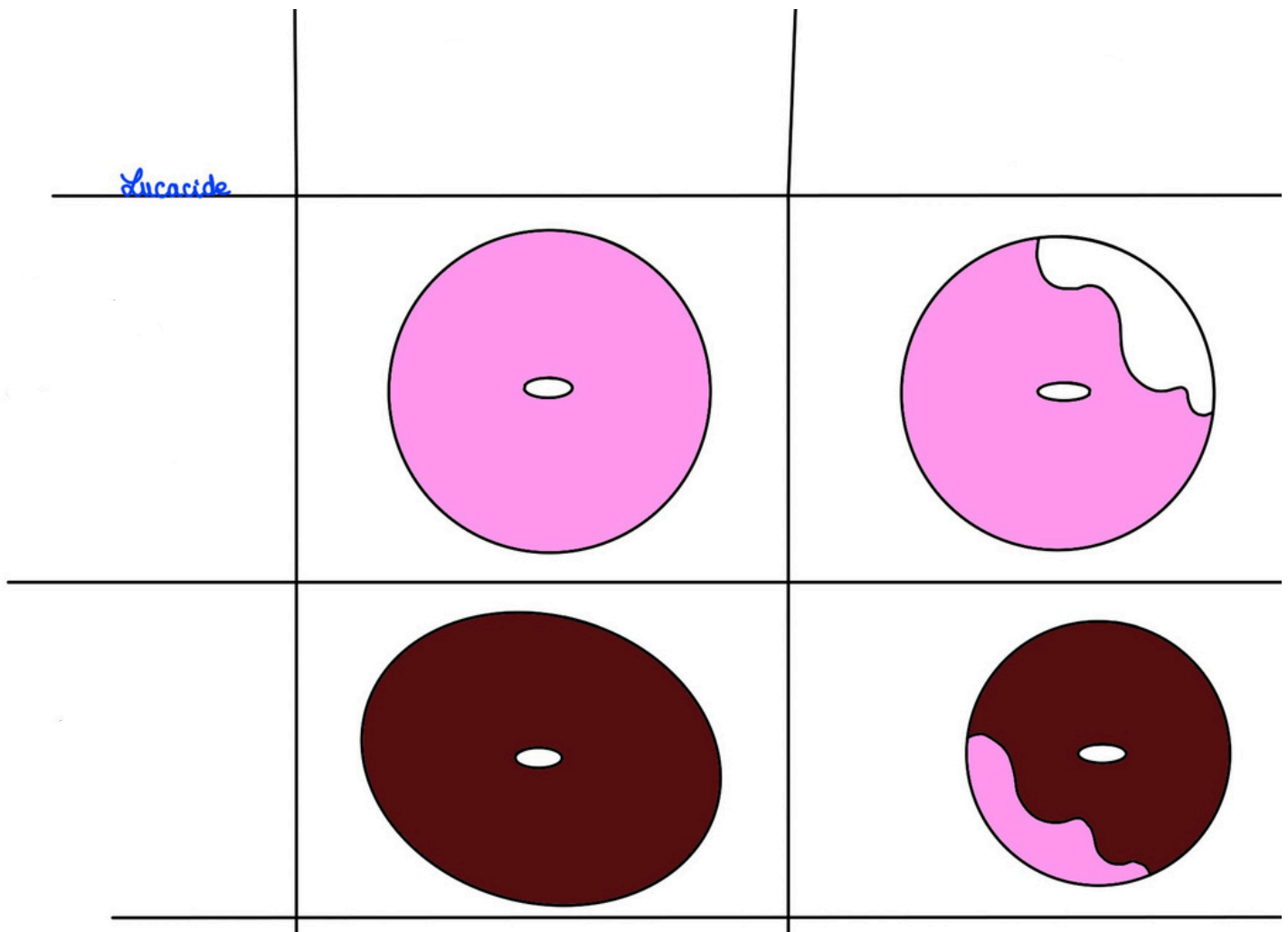


## Schéma 22 : Vue chirurgicale lors d'une coelioscopie (sans péritoine)

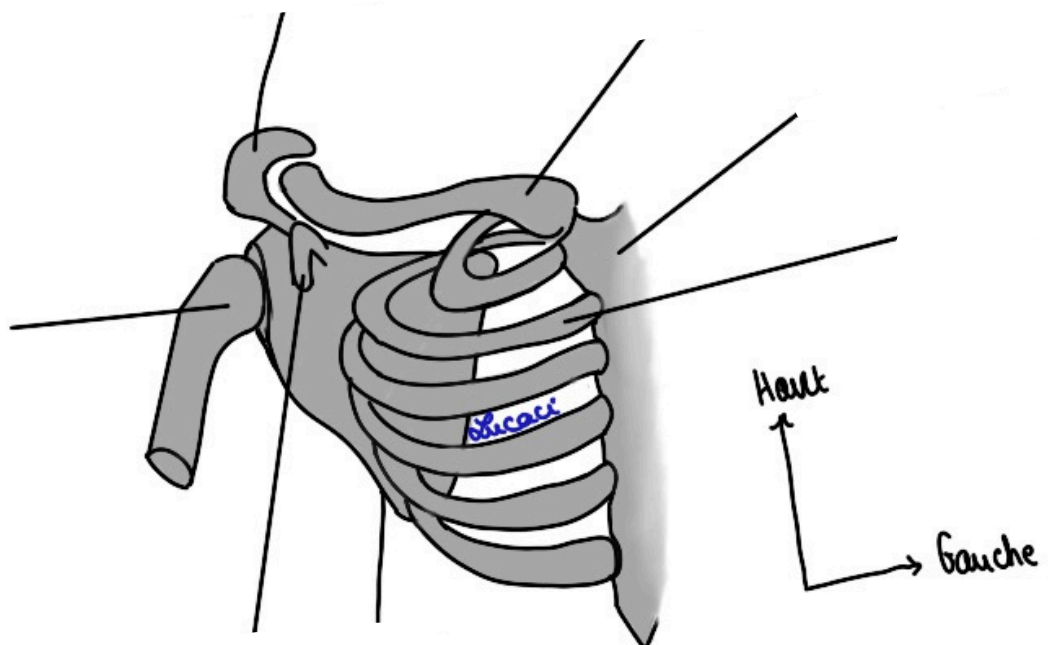


# Schéma 23 : Vue chirurgicale lors d'une coelioscopie (avec péritoine)





**Schéma 24 : Colorations du col utérin**



**Schéma 25 : Os de la région axillaire**

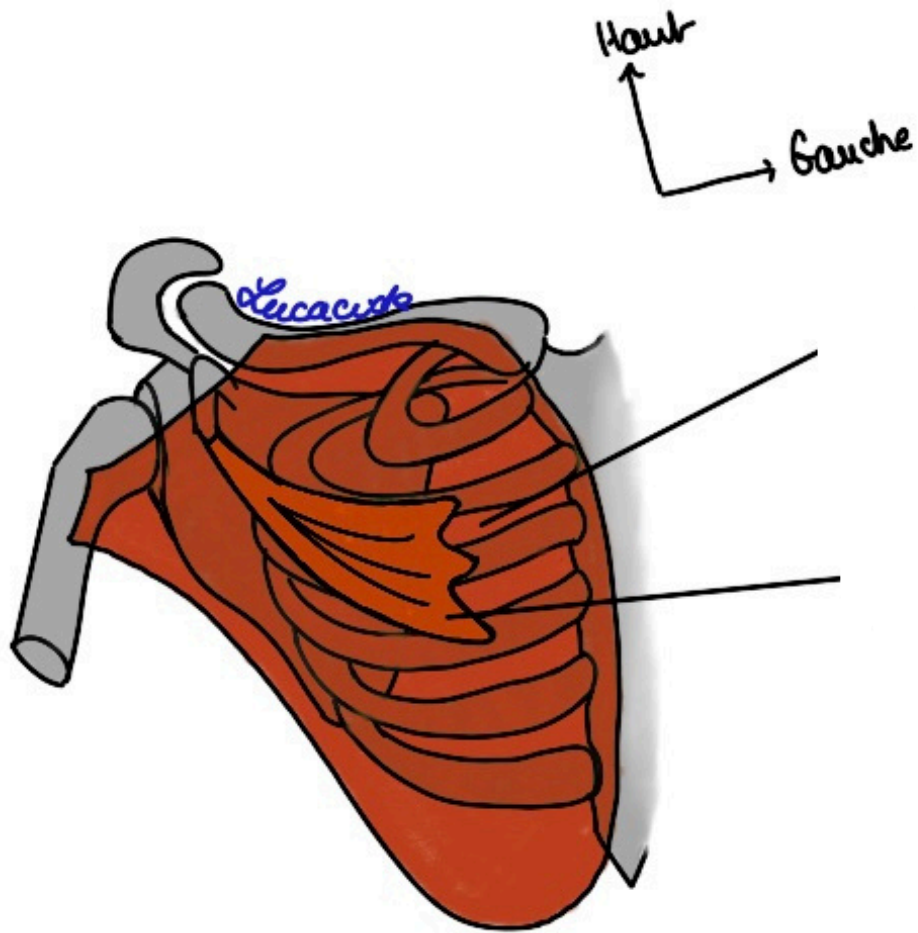


Schéma 26 : Thorax

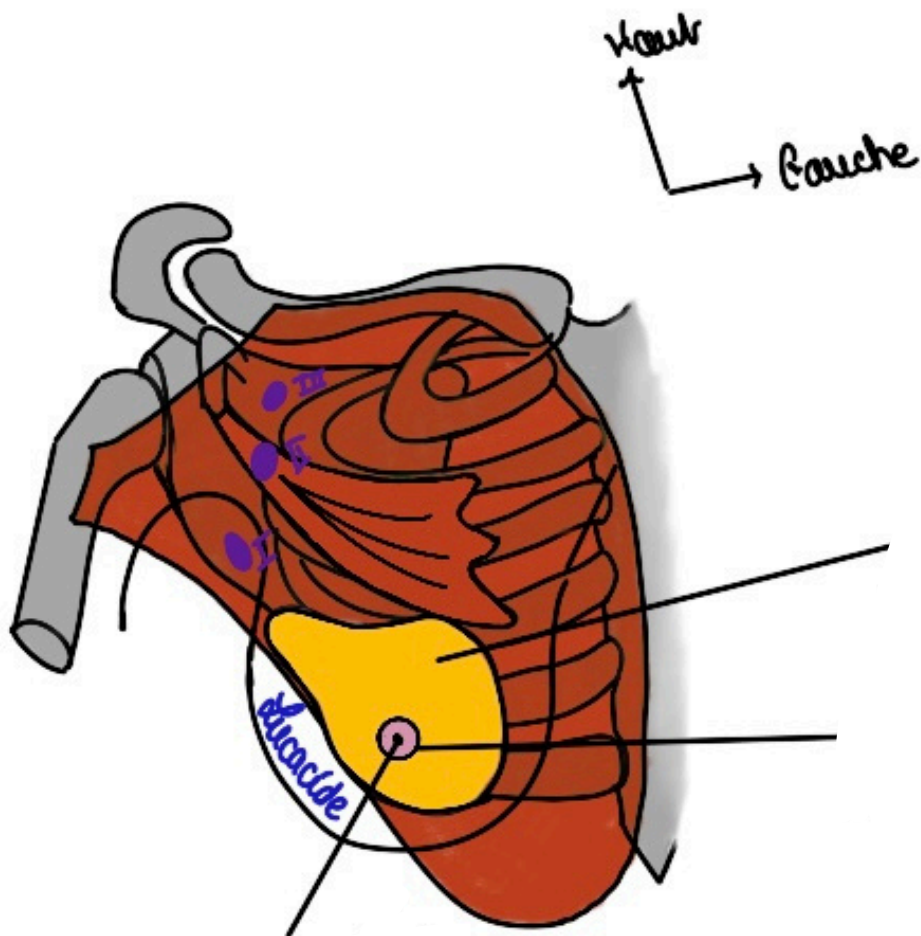
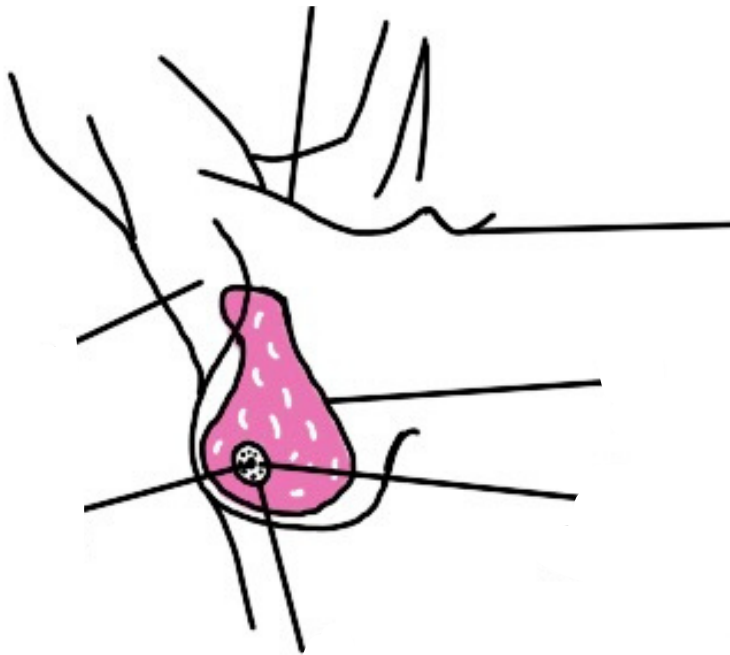
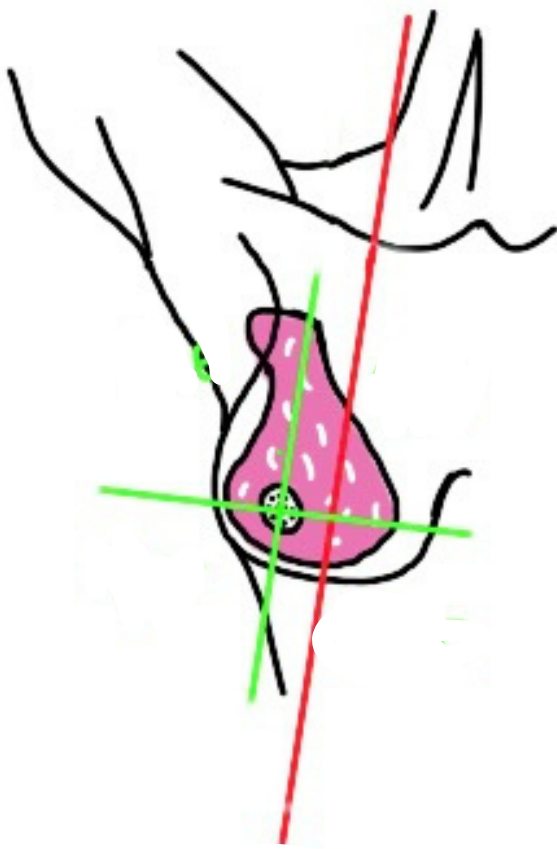


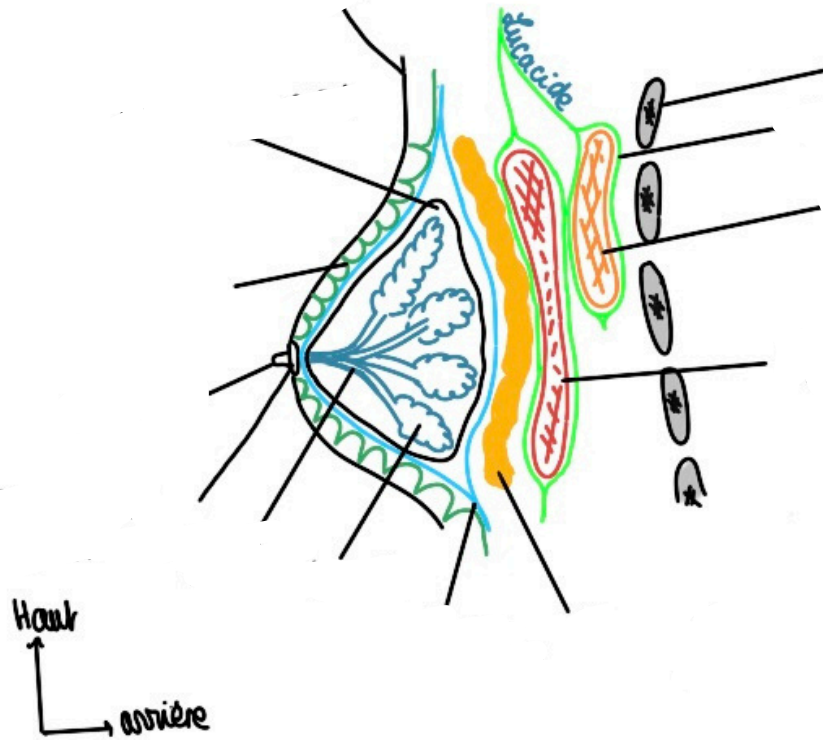
Schéma 27 : La glande mammaire



**Schéma 28 : La glande mammaire (bis)**



**Schéma 29 : Cadrans**



**Schéma 30 : Coupe para-sagittale de la glande mammaire**